

HETEROBILHARZIA AMERICANA IN DOGS: CHARACTERIZING CLINICAL
INFECTION, EVALUATING DIAGNOSTIC TEST PERFORMANCE, AND
EXPLORING NOVEL METHODS OF DIAGNOSIS

A Dissertation

by

JESSICA YVONNE RODRIGUEZ

Submitted to the Office of Graduate and Professional Studies of
Texas A&M University
in partial fulfillment of the requirements for the degree of

DOCTOR OF PHILOSOPHY

Chair of Committee,	Karen Snowden
Committee Members,	Christine Budke
	Charles Criscione
	Barbara Lewis
Head of Department,	Ramesh Vemulapalli

August 2017

Major Subject: Veterinary Pathobiology

Copyright 2017 Jessica Yvonne Rodriguez

ABSTRACT

Heterobilharzia americana is a waterborne trematode parasite (Family: Schistosomatidae) of dogs. More complete information regarding clinical, geographic, and diagnostic aspects of this parasite is needed to aid in more effective awareness and diagnosis.

A total of 238 cases diagnosed through the Texas A&M Veterinary Medical Diagnostic Laboratory, Texas A&M Veterinary Medical Teaching Hospital, Texas A&M Diagnostic Parasitology Service, and Texas A&M Gastrointestinal Laboratory were reviewed. Cases were distributed primarily in the eastern region of Texas. Clinical signs were diarrhea (67%), weight loss (38%), anorexia/hyporexia (27%), vomiting (22%), hematochezia (20%), lethargy (17%), and polyuria/polydipsia (6%). *H. americana* was attributed to death in 20 of 39 necropsy cases. Trematode eggs were identified histologically in the small intestine (84%), liver (84%), large intestine (39%), pancreas (35%), lung (9%), lymph node (8%), and spleen (4%).

A total of 69 dogs were enrolled in a diagnostic methods comparison study. Relative test sensitivities were 50% (29.1-70.9) for fecal saline sedimentation, 58.3% (36.6-77.9) for PCR of fresh feces, and 95.8% (78.9-99.9) for PCR of fecal sediment. PCR of fresh feces was no more sensitive than fecal saline sedimentation. Circulating anodic antigen was detected in the serum of 8 dogs using the *Schistosoma mansoni* point-of-care assay (POC-CAA). Circulating cathodic antigen was detected in urine of 7 dogs using the POC-CCA test.

Next generation sequencing technology and the Galaxy-based RepeatExplorer computation pipeline were used to discover highly repetitive DNA sequences in the *H.*

americana genome. A novel probe-based real-time PCR diagnostic assay targeting these highly repetitive sequences was developed. No DNA amplification was detected when testing DNA of common parasites indicating that the assay is highly specific. The real-time assay detected 9 samples as positive that were negative by conventional PCR targeting a segment of the 18S ribosomal DNA.

Increased awareness of *H. americana* by veterinarians is crucial for a timely diagnosis. Promising methods to increase test sensitivity include sample concentration before DNA extraction, and using highly repetitive DNA targets in a real-time PCR assay. Circulating antigens were detected in some dogs; however, more sensitive test modalities should be developed in order to make circulating antigens accurate diagnostic targets.

CONTRIBUTORS AND FUNDING SOURCES

Committee

This work was supervised by a dissertation committee consisting of Dr. Karen Snowden (advisor) and Dr. Barbara Lewis of the Department of Veterinary Pathobiology (VTPB), Dr. Christine Budke of the Department of Veterinary Integrative Biosciences (VIBS), and Dr. Charles Criscione of the Department of Biology (BIOL).

Student/collaborator contributions

PI, Karen Snowden, oversaw project design and provided critical review of the scientific manuscript writing of the student.

Chapter 1

The literature review was performed independently by the student.

Chapter 2

Dr. Barbara Lewis facilitated case record collection from the Texas A&M Veterinary Medical Diagnostic Laboratory. Drs. Jörg Steiner and Jan Suchodolski provided GI Laboratory case records. Dr. Tom Craig provided Texas A&M diagnostic parasitology laboratory case records. The student compiled and analyzed the records independently.

Chapter 3

Dr. Govert van Dam provided point-of-care diagnostic assays and assisted in troubleshooting results. Statistics were performed by the student, with input from Dr. Christine Budke. Kathleen Logan and Beverly Finneburgh provided technical support for fecal DNA extraction and PCR and sequencing. The student performed the majority of the laboratory work independently.

Chapter 4

The student performed the bioinformatics and PCR design and optimization with guidance and support from Dr. Steven Williams (Department of Biological Sciences, Smith College, Northampton, MA) and Nils Pilotte, MS (Molecular and Cellular Biology Program, University of Massachusetts Amherst, Amherst, MA) at Smith College. Dr. William's lab also provided human parasite DNA for specificity analysis of the PCR. Dr. Charles Criscione facilitated obtaining *Trichobilharzia* sp. DNA through Dr. Sara Brant (Division of parasites, University of New Mexico, Albuquerque, NM). Real-time PCR thermocycler use was provided by the Molecular Genomics Shared Workspace of the Texas A&M Institute for Genome Sciences and Society. The student performed all real-time PCR tests independently.

Funding sources

Graduate study was supported by the Texas A&M University Graduate Diversity Fellowship and by Merial and the National Center of Veterinary Parasitology (NCVP). Research was supported by two NCVP grants (2013 & 2015), a Burroughs-Wellcome Fund Collaborative Research Travel Award (2015), and the Texas A&M CORE Facilities Grant (2016).

TABLE OF CONTENTS

	Page
ABSTRACT.....	ii
CONTRIBUTORS AND FUNDING SOURCES	iv
TABLE OF CONTENTS.....	vi
LIST OF FIGURES	viii
LIST OF TABLES	ix
CHAPTER I INTRODUCTION AND LITERATURE REVIEW	1
Family: Schistosomatidae	1
Life cycle	11
Pathogenesis.....	12
Intestinal schistosomiasis	13
Hepatic schistosomiasis	14
Schistosomiasis in other organs/aberrant locations	16
Secondary pathological lesions.....	17
Cercarial dermatitis	18
Clinical pathology	18
Clinical signs.....	21
Diagnostics.....	22
Parasitological.....	22
Immunodiagnosics	27
Molecular	36
Surgical	39
Imaging	39
Treatment	40
Dissertation aims.....	41
CHAPTER II DISTRIBUTION AND CHARACTERIZATION OF <i>HETEROBILHARZIA AMERICANA</i> IN DOGS IN TEXAS	43
Introduction.....	43
Materials and methods	44
Results.....	46
Discussion.....	54

CHAPTER III DETECTING CIRCULATING CATHODIC AND ANODIC ANTIGENS IN DOGS NATURALLY INFECTED WITH <i>HETEROBILHARZIA AMERICANA</i> : A COMPARATIVE DIAGNOSTIC METHODS STUDY	62
Introduction.....	62
Materials and methods	64
Selection of dogs and data collection.....	64
Fecal saline sedimentation test (FSS)	65
Concentration of fecal sediment for DNA extraction	66
Fecal DNA extraction and PCR (PCR-ff and PCR-sedi).....	66
Small subunit rRNA gene sequencing	67
Point-of-care antigen testing (POC-CCA and POC-CAA).....	67
Statistical analysis	68
Results.....	69
Discussion.....	74
CHAPTER IV UTILIZING NEXT GENERATION SEQUENCING TO DISCOVER HIGHLY REPETITIVE DNA SEQUENCE TARGETS FOR REAL TIME PCR DIAGNOSIS OF <i>HETEROBILHARZIA AMERICANA</i>	79
Introduction.....	79
Materials and methods	81
Isolation of parasite genomic DNA	81
Next generation sequencing of genomic DNA	81
Repeat analysis.....	81
Primer and probe design, testing, and optimization.....	82
Testing of canine samples.....	83
Statistical analysis	83
Results.....	84
Repeat analysis.....	84
Primer and probe design, testing, and optimization.....	87
Testing of canine samples	89
Discussion.....	90
CHAPTER V SUMMARY AND CONCLUSIONS	93
REFERENCES	97

LIST OF FIGURES

FIGURE		Page
1.1	Histologic section (H&E staining) showing many <i>Heterobilharzia americana</i> eggs (arrows) linearly arranged in lamina propria of small intestine of a dog.....	16
1.2	Histological section (H&E staining) showing <i>Heterobilharzia americana</i> eggs within granuloma in hepatic parenchyma.....	18
1.3	Histological section (H&E section) showing marked fibrosis and granulomatous inflammation in the pancreas of a dog secondary to trapped eggs of <i>Heterobilharzia americana</i>	19
1.4	<i>Heterobilharzia americana</i> eggs from a fecal saline sedimentation test.....	25
1.5	Partially hatched miracidium larva from <i>H. americana</i> egg.....	25
2.1	<i>Heterobilharzia americana</i> diagnosis among dogs in Texas by biopsy, fecal examination, or fecal PCR from 1991-2012 by year	49
2.2	<i>Heterobilharzia americana</i> cases among dogs in Texas by county from 1991 to 2012	50
2.3	Breed distribution of canine <i>Heterobilharzia americana</i> cases in Texas by American Kennel Club (AKC) breed groups.....	51
2.4	<i>Heterobilharzia americana</i> diagnosis in dog by month in Texas.....	52
4.1	Graphical layout output of RepeatAnalysis	87
4.2	Output file of a cluster of similar DNA reads.....	88
4.3	Sensitivity analysis of primer/probe Set 3	90

LIST OF TABLES

TABLE	Page
1.1	Geographic distribution of wildlife infected with <i>Heterobilharzia americana</i>4
1.2	Summary of reports of <i>Heterobilharzia americana</i> infections in dogs and their geographic locations7
1.3	Selected <i>Schistosoma</i> spp. of humans and animals11
1.4	Laboratory abnormalities reported for dogs infected with <i>Heterobilharzia americana</i>22
1.5	Most common clinical signs reported in dogs infected with <i>Heterobihlarzia americana</i>24
2.1	Clinical signs reported in 90 dogs diagnosed with <i>Heterobilharzia Americana</i>53
2.2	Proportion of tissues containing <i>H. americana</i> eggs in 39 canine necropsy Cases54
3.1	Diagnostic characteristics of parasitological, molecular, and immunological tests for detecting <i>H. americana</i> infection in naturally infected dogs73
3.2	Comparisons of positive and negative results between each diagnostic test pair74
3.3	Total egg counts of positive fecal saline sedimentation tests with accompanying molecular and immunodiagnostic test results75
4.1	Candidate primer/probe sequences targeting high copy sequence targets89
4.2	Comparison of real-time assay (Real-time-PCR-ff) with conventional PCR of fresh feces (PCR-ff)92
4.3	Comparison of real-time assay targeting highly repetitive DNA sequence (Real-time-PCR-ff) and conventional PCR of fresh feces (PCR-ff) with fecal saline sedimentation (FSS) and conventional PCR of the fecal sediment (PCR-sedi)92

CHAPTER I

INTRODUCTION AND LITERATURE REVIEW

Heterobilharzia americana Price, 1929 (Platyhelminthes; Trematoda; Digenea; Strigeidida; Schistosomatoidea; Schistosomatidae; Heterobilharzia) is a trematode parasite of wildlife and domestic mammals in North America. Parasites in the Schistosomatidae family are informally called ‘schistosomes’ and the condition of being infected with these parasites is referred to as ‘schistosomiasis’. Several parasites in this family are of global medical importance as ‘neglected tropical diseases’ and have been extensively studied. Here I review scientific literature about *H. americana* regarding its host and geographic range, life cycle and pathogenesis, methods of diagnosis, and treatment. I also include related information on other more extensively studied schistosome parasites of medical and veterinary importance.

FAMILY: SCHISTOSOMATIDAE

Schistosome parasites infect a wide variety of mammalian and avian hosts and are distributed worldwide. The majority of species infect the blood vessels of the intestinal system of the hosts, while a limited number of species infect the blood vessels of the nasal cavity or the bladder.

H. americana was originally described by Price (1929) by identifying a male adult worm in a bobcat in Florida (*Lynx rufus floridanus*). He later redescribed the species by identifying 22 males and 3 females in a raccoon in Texas (*Procyon lotor*) (Price, 1943). This is the only species in the *Heterobilharzia* genus. It has been documented from a wide range of mammalian wildlife, primarily raccoons (*Procyon lotor*), in the southeastern United States

(Table 1.1). Animals were diagnosed by examining adult worms in the mesenteric veins or by observing parasite eggs on histopathology. Detection of the parasite by parasitological fecal exam was variable (Table 1.1). Two reports documented eggs in raccoon feces (Goff and Ronald, 1981; McKown et al., 1991). No eggs were detected in the feces of a nutria and swamp rabbits in one report (Malek et al., 1961).

Absence of *H. americana* infection was also noted in one survey in 64 raccoons examined in South Carolina, 22 in Georgia, and 6 in Virginia (Harkema and Miller, 1964). Another survey did not detect infection in 10 raccoons examined in Georgia and 10 in Virginia (Schaffer et al., 1981).

In addition to wildlife, *H. americana* has been documented to infect domestic animals. It was first described in dogs in Louisiana in 1961 (Malek et al., 1961). Dogs comprise the majority of domestic animal reports with most canine cases located in Texas, Louisiana, and Florida (Table 1.2). Canine infections are likely underdiagnosed and have a wider geographic distribution demonstrated by one study documenting five dogs infected in Kansas (Hanzlicek et al., 2011), and another case reported in Indiana (Rodriguez et al., 2016).

Several other domestic animals have been diagnosed with *H. americana* infections. Buergelt and Greiner (1995) initially reported on suspected schistosome infections in Florida horses based on histopathologic evidence. *H. americana* infection in Texas horses was later verified by molecular testing (Corapi et al., 2011b; Corapi et al., 2012). A molecularly confirmed fatal infection was also documented in a llama (*Llama glama*) (Corapi et al., 2015).

Table 1.1 Geographic distribution of wildlife infected with *Heterobilharzia americana*. UK=unknown.

Host	Geographic location	Adult worms	Eggs in tissues	Eggs in feces	Number of animals	References
Raccoon (<i>Procyon lotor</i>)	TX	Yes	UK	UK	1	Price, 1943
“ ”	NC (Bladen County)	Yes	UK	UK	1	Miller and Harkema, 1960
“ ”	LA (MS River Delta and coastal areas)	Yes	Intestine, liver, lung, spleen, kidney	UK	25 of 52	Malek et al., 1961
“ ”	FL	Yes	UK	UK	UK	Lee, 1962 (personal communication)
“ ”	FL	Yes	UK	UK	1 of 19	Harkema and Miller, 1964
“ ”	NC (coastal; mainland)	Yes	UK	UK	15 of 61; 1 of 48	Harkema and Miller, 1964
“ ”	GA (Liberty County)	Yes	UK	UK	1	Byrd et al., 1967
“ ”	FL (southeastern)	Yes	Liver, small and large intestine, lung	UK	3 of 3	Bartsch and Ward, 1976
“ ”	TX (Burlison County)	Yes	Liver	Yes	6 of 12	Goff and Ronald, 1981
“ ”	FL (Glades, Highlands, Hillsborough, and Orange Counties)	Yes	UK	UK	36 of 51	Schaffer et al., 1981
“ ”	NC (Pender County)	Yes	UK	UK	4 of 10	Schaffer et al., 1981

Table 1.1 Continued

Host	Geographic location	Adult worms	Eggs in tissues	Eggs in feces	Number of animals	References
Raccoon (<i>Procyon lotor</i>)	TX (Brown County)	Yes	UK	UK	8 of 37	Schaffer et al., 1981
“ ”	LA (Atchafalaya basin)	Yes	UK	UK	20 of 37	Shoop and Corkum, 1982
“ ”	KS (Lyon, Greenwood, and Crawford Counties)	Yes	Mesenteric lymph node, liver, small intestine, lung, pancreas	Yes	11 of 30	McKown et al., 1991
“ ”	FL (Duval County)	Yes	UK	UK	12 of 18	Forrester, 1992
“ ”	TX (Archer and Wichita Counties)	Yes	UK	UK	17 of 36	Kelley, 2010
Coyote (<i>Canis latrans</i>)	TX and LA (Gulf Coastal prairies)	Yes	UK	UK	6 of 24	Custer, 1981
Red Wolf (<i>Canis rufus</i>)	TX and LA (Gulf Coastal prairies)	Yes	UK	UK	4 of 8	Custer, 1981
Coyote/red wolf hybrid	TX and LA (Gulf Coastal prairies)	Yes	UK	UK	18 of 46	Custer, 1981
Bobcat (<i>Lynx rufus</i>)	LA (Atchafalaya Basin)	Yes	UK	UK	1 of 3	Shoop and Corkum, 1982
Florida panther (<i>Felis concolor coryi</i>)	FL (Collier and Glades Counties)	Yes	UK	UK	6 of 8	Forrester, 1985
Black bear (<i>Ursus americanus</i>)	FL (Collier County)	Yes	UK	UK	1 of 37	Forrester, 1992

Table 1.1 Continued

Host	Geographic location	Adult worms	Eggs in tissues	Eggs in feces	Number of animals	References
Opossum (<i>Didelphis virginianis</i>)	LA (St. Charles Parish)	Yes	UK	UK	1	Kaplan, 1964
Armadillo (<i>Dasypus novemcinctus</i>)	LA (Pointe Coupee Parish)	No	Intestine, colon, liver, mesenteric lymph node, lung	UK	1 of 1	Krotoski et al., 1984
Nutria (<i>Myocastor coypus</i>)	LA (MS River Delta and coastal areas)	Yes	Intestine, liver	UK	22 of 37	Malek et al., 1961
“ ”	LA	UK	Liver	No	UK	Malek, 1970
Swamp rabbit (<i>Sylvilagus aquaticus</i>)	LA (MS River Delta and coastal areas)	Yes	Intestine, liver	UK	1 of 3	Malek et al., 1961
“ ”	LA	UK	Liver	No	UK	Malek, 1970
White tailed deer (<i>Odocoileus virginianus</i>)	SC (Barnwell County)	Yes	UK	UK	4 of 15	Byrd et al., 1967
“ ”	FL (Collier County)	Yes	UK	UK	3 of 40	Forrester et al., 1994
Beaver (<i>Castor canadensis</i>)	TX (McLennan County)	Yes	UK	UK	4 of 36	Fedynich et al., 1986
Mink (<i>Mustela vison</i>)	LA (Atchafalaya Basin)	Yes	UK	UK	2 of 42	Shoop and Corkum, 1982
Brazilian tapir (<i>Tapirus terrestris</i>)	MI*	UK	Small intestine, liver	UK	1 of 1	Yamini and Schillhorn van Veen, 1988

*This animal was diagnosed in a zoo in Michigan, but had previously lived in Mississippi, Florida, and Ohio.

Table 1.2 Summary of reports of *Heterobilharzia americana* infections in dogs and their geographic locations. FEU = fecal exam undefined; DFS = direct fecal smear; FSS = fecal saline sedimentation; PCR = polymerase chain reaction; FNA = fine needle aspirate.

Geographic location	Number of dogs	Diagnosis	Adult worms	Eggs in tissues	Reference
TX (Brazos county)	1	Necropsy	UK	Intestine, liver	Pierce, 1963
TX	1	Necropsy	UK	Intestine, lungs	Sponenberg, 1973
TX	1	Biopsy DFS	UK	Small intestine, pancreas, mesenteric lymph node	Troy et al., 1987
TX	2	Necropsy (2)	Yes (1)	Liver (2), spleen (1), lungs (1), pancreas (1), stomach (1), small intestine (2), large intestine (2), large intestine (2)	Fradkin et al., 2001
TX	1	Biopsy DFS	Yes	Small intestine, liver, pancreas, mesenteric lymph node	Ruth, 2010
TX	22	Necropsy (4) Biopsy (9) FSS (9)	UK	Liver (4), lymph nodes (2), pancreas (3), small and large intestine (4), stomach (1), spleen (1), lungs (1)	Fabrick et al., 2010
TX	1	Necropsy	UK	Small intestine, large intestine, liver, pancreas, lung, kidney	Corapi et al., 2011a
GA (from Gulf Coast Texas)	1	Biopsy FSS	UK	Liver, small intestine, mesenteric lymph node	Stone et al., 2011
LA (MS River Delta and coastal areas)	3	FEU (2) Necropsy (1)	Yes	Intestine (1), liver (1), lung (2), kidneys (1), spleen (1)	Malek et al., 1961
LA	1	Biopsy FSS	UK	Small intestine	Roux et al., 2015
FL	1	Biopsy	UK	Liver	McHenry et al., 2017;
FL	1	Necropsy	UK	Liver	Slaughter et al., 1988

Table 1.2 Continued

Geographic location	Number of dogs	Diagnosis	Adult worms	Eggs in tissues	Reference
FL	1	Necropsy	UK	Small intestine, liver, pancreas, mesenteric lymph node	Rohrer et al., 2000
NC	1	Biopsy FSS DFS	UK	Small intestine, colon, liver, pancreas, mesenteric lymph node	Flowers et al., 2002
KS (Lyon, Greenwood, and Crawford Counties)	5	Biopsy (3) Necropsy (2) FSS (2) PCR (1)	Yes (2)	Small intestine (3), large intestine (3), liver (3), mesenteric lymph node (2), pancreas (2)	Hanzlicek et al., 2011
IN	1	Biopsy FSS	UK	Small intestine	Rodriguez et al., 2016

The genus *Schistosomatium* is the sister taxon to *Heterobilharzia*. The only species in this genus is *S. douthitti*, which is the only other mammalian schistosome in North America. It infects rodents in the north central United States and south central Canada including the muskrat (*Ondatra zibethica*) and the meadow vole (*Microtus pennsylvanicus*) (Kagan et al., 1954; Malek, 1977).

Human schistosomes are second to malaria in being the most devastating parasite of humans, infecting over 200 million people worldwide (Chitsulo et al., 2000). *Schistosoma mansoni*, *S. japonicum*, and *S. haematobium* are the most common schistosome species (Table 1.3). *S. mansoni* is endemic in regions of sub-Saharan Africa, the Middle East, South America, and the Caribbean (Chitsulo et al., 2000). *S. japonicum* is endemic in regions of China, Indonesia, and The Philippines. This species also infects several species of mammals including water buffalo, cattle, pigs, goats, rodents, and dogs (Carabin et al., 2005). *S. haematobium* infects the veins of the urinary system and is distributed in Africa and the Middle East. Recently, *S. haematobium* transmission has been documented in Corsicana, a French Mediterranean island (Berry et al., 2014). *S. mekongi*, *S. intercalatum*, and *S. guineensis* infect fewer people compared to the other schistosomes due to the localized regions of transmission.

Several other schistosomes infect wild and domestic animals outside of North America with some of these species posing a zoonotic concern since they may infect humans as well. *Schistosoma bovis*, *S. curassoni*, and *S. mattheei* are intestinal schistosomes that infect domesticated and wild bovids (Table 1.3). *Schistosoma nasale* is a nasal schistosome of bovids (Ravindran, 2012). Natural human and natural and experimental baboon infections with *S. mattheei* has also been documented (Hira, 1975; Pitchford and

Visser, 1975; Weyher et al., 2010). Hybridization and introgression has occurred primarily in species within the *S. haematobium* group (*S. haematobium*, *S. guineensis*, *S. curassoni*, and *S. bovis*) (Elsa et al., 2016; Leger and Webster, 2016). Other schistosome species primarily infect wildlife including *S. hippopotami* and *S. edwardiense* in hippopotami (Morgan et al., 2003), and *S. margrebowiei* and *S. leiperi* in wild antelopes (Table 1.3) (Wright et al., 1979).

The majority of species in the Schistosomatidae family are avian schistosomes which infect waterfowl worldwide. The genus *Trichobilharzia* comprises the majority of species in this group. Other genera include *Gigantobilharzia*, *Allobilharzia*, *Anserobilharzia*, *Dentritobilharzia*, and *Bilharziella*. *Austrobilharzia* and *Ornithobilharzia* are exclusively marine schistosomes. These species are similar to the mammalian schistosomes in that they primarily infect the veins of the intestine, but some do infect the veins of the nasal cavity (Horák et al., 2015).

Table 1.3 Selected *Schistosoma* spp. of humans and animals. *Primary host.

Schistosome species	Host	Site of infection	Geographic location	Reference
<i>Schistosoma mansoni</i>	Humans*, baboons, rodents	Intestinal veins	Africa, Middle East, South America, Caribbean	Chitsulo et al., 2000
<i>Schistosoma japonicum</i>	Humans, wild and domesticated mammals	Intestinal veins	China, Indonesia, The Philippines	Carabin et al., 2005; Zhou et al., 2005
<i>Schistosoma haematobium</i>	Humans	Bladder veins	Africa, Middle East, France (Corsica)	Berry et al., 2014; Chitsulo et al., 2000
<i>Schistosoma mekongi</i>	Humans*, dogs, pigs	Intestinal veins	Mekong River basin: Laos, Cambodia	Urbani et al., 2002
<i>Schistosoma intercalatum</i>	Humans	Intestinal veins	Central Africa (Democratic Republic of Congo)	Wright et al., 1972
<i>Schistosoma guineensis</i>	Humans	Intestinal veins	West Africa (Lower Guinea)	Webster et al., 2006
<i>Schistosoma mattheei</i>	Bovids*, humans, baboons	Intestinal veins	South Africa, Zimbabwe	Jordan et al., 1993; Pitchford and Visser, 1975
<i>Schistosoma curassoni</i>	Bovids	Intestinal veins	West Africa	Jordan et al., 1993; Rollinson et al., 1990
<i>Schistosoma bovis</i>	Bovids	Intestinal veins	Africa, Middle East, Mediterranean region	Rollinson et al., 1990
<i>Schistosoma nasale</i>	Bovids	Nasal veins	India	Ravindran, 2012
<i>Schistosoma hippopotami</i>	Hippopotami	Intestinal veins	South Africa	Morgan et al., 2003
<i>Schistosoma edwardiense</i>	Hippopotami	Intestinal veins	South Africa	Morgan et al., 2003
<i>Schistosoma margrebowiei</i>	Antelopes	Intestinal veins	Africa	Wright et al., 1979
<i>Schistosoma leiperi</i>	Antelopes	Intestinal veins	Africa	Wright et al., 1979

LIFE CYCLE

Adult worms of the Schistosomatidae family are dioecious. The female lives within a gynaecophoric canal in the larger male worm in veins of the host. Adult schistosomes are long-lived in their human hosts, with an estimated life span of 3-10 years (Colley et al., 2014). *S. mansoni* worms produce hundreds of eggs per day and *S. japonicum* worms lay thousands of eggs per day (Cheever et al., 1994). Eggs penetrate into organs (intestinal tract, urinary tract, nasal cavity) and are released via feces, urine, and nasal secretions. A fully developed miracidium within the egg is the first of several larval stages in the life cycle. Once the egg is shed into the environment, the motile ciliated miracidium hatches out of the egg upon contact with fresh water and penetrates an intermediate aquatic host snail suitable to that species of schistosome. The miracidium develops into a mother (primary) sporocyst larva which elongates into a sac containing germinal cells. From these germinal cells, many daughter sporocyst larvae are produced by asexual reproduction. These secondary sporocysts leave the sac and migrate to the hepatopancreas and gonads of the snail where they elongate into sacs containing germinal cells. From these germinal cells, forked tail cercaria larvae develop and then exit through the sac and then through the surface of the snail into fresh water to seek a definitive host. During enzymatic penetration of the intact skin of the host, the tail of the cercaria is dropped and the body becomes the schistosomule larval stage which then enters a venous or lymphatic vessel and is carried to the heart and then capillaries of the lung where further development occurs. The larva then reenters circulation and reaches the liver vasculature where growth, development, and pairing of adult male and female worms occurs. The worms then migrate to the mesenteric veins (intestinal schistosomes) and

bladder veins (urinary schistosomes) (Goff and Ronald, 1981; He, 1993; Jordan et al., 1993; Lee, 1962).

The intermediate hosts of *H. americana* are the lymnaeid snails, *Pseudosuccinia columella* and *Lymnaea cubensis* (Lee, 1962). In an experimental laboratory study, cercariae were released from snails 21 to 28 days after being infected with *H. americana* miracidia. Eggs were detected in the stool of experimentally infected dogs between 61 and 70 days post infection (prepatent period) (Lee, 1962). Thrasher (1964) experimentally infected 4 dogs, and detected eggs in the feces between 65 and 121 days (average 84 days) post infection. In comparison, the prepatent period in human schistosome infections is 5-7 weeks (Colley et al., 2014).

PATHOGENESIS

Inflammatory response to eggs in different organs (Table 1.3) is the primary pathology induced by intestinal schistosomiasis. The response is characterized by granulomatous inflammation composed of macrophages, giant cells, eosinophils, neutrophils, lymphocytes, and plasma cells with mild to severe fibrosis (Bartsch and Ward, 1976; Flowers et al., 2002). On histopathologic examination, eggs are observed as yellow to clear with or without a multinucleated miracidium larva. During resorption, only partial remnants of eggs may be observed. Complete resorption can occur within granulomas. Eggs can also be mineralized within granulomas appearing a dark purple on Hematoxylin and eosin (HE) stained tissue sections (Kvitko-White et al., 2011). Marked mineralization of eggs and granulomas has been most apparent in horses and a llama case (Corapi et al., 2011b; Corapi et al., 2015; Corapi et al., 2012).

Intestinal schistosomiasis

Intestinal lesions in *H. americana* infected animals are similar to those seen in human schistosomiasis. Adult worms in the mesenteric veins mate and lay eggs that penetrate through the veins and through the wall of the intestine, disrupting the intestinal epithelium as they enter into the lumen. Eggs and associated inflammation are detected in all layers of the intestine and can be seen linearly aligned in the lamina propria (Figure 1.1). Gross lesions associated with egg-associated granulomas include small to medium round white, grey, or tan multifocal lesions on the serosal surface of the liver, intestines, pancreas, and mesentery (Corapi et al., 2012; Hanzlicek et al., 2011; Ruth, 2010). The intestine can be thickened and mesenteric lymph nodes can be enlarged. One report (Rohrer et al., 2000) described a mesenteric lymph node 3 times the expected size in a dog. One dog had a cecocolic intussusception that contained parasite eggs (Hanzlicek et al., 2011). Inflammation can lead to colonic polyps in human schistosomiasis, which is not observed in *H. americana* (Jordan et al., 1993).

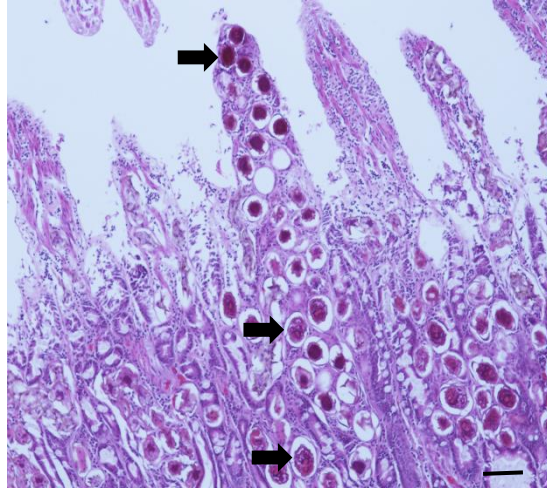


Figure 1.1 Histologic section (H&E staining) showing many *Heterobilharzia americana* eggs (arrows) linearly arranged in lamina propria of small intestine of a dog. Size bar = 100 μm .

Hepatic schistosomiasis

Hepatic pathological lesions have been most extensively documented in humans infected with *S. mansoni* and are similar to other human and animal intestinal schistosomes (Table 1.3). A large number of eggs laid in the mesenteric venules are carried by portal circulation to the liver instead of traversing through the intestine, resulting in granulomatous inflammation and fibrosis centered in the portal triads (Colley et al., 2014). The pathological changes have been termed ‘Symmer’s pipe stem fibrosis,’ ‘Symmer’s fibrosis,’ and ‘clay-pipe stem fibrosis’. These terms refer to the gross fibrosis appearing as if white clay-pipe stems have been inserted through the portal triads (Symmers, 1904). The architecture of the hepatic lobule and hepatocyte function remains intact (Andrade, 1987a). The severity of fibrotic changes is associated with the intensity and chronicity of infection as well as the host’s immunoregulatory mechanisms (Cheever, 1968; Colley, 1986). The portal fibrosis leads to portal hypertension that can lead to hepatosplenomegaly, esophageal varices, and

ascites in some individuals. Esophageal varices may rupture and cause acute death (Jordan et al., 1993). Subjects with portal hypertension can also develop pulmonary hypertension secondary to granulomatous reaction to eggs that reached the lungs via portal caval shunts.

Unlike in human schistosomiasis, hepatosplenomegaly is not a hallmark gross pathological change in *H. americana* infections. On the contrary, small or shrunken livers have been described in a dog and 3 raccoons (Bartsch and Ward, 1976; Corapi et al., 2011a). Periportal and bridging fibrosis has been described in *H. americana* infections but eggs have also been described as ‘scattered’ within the hepatic parenchyma, disrupting the architecture of the hepatic lobules (Figure 1.2) (Bartsch and Ward, 1976; Corapi et al., 2011a; Feldman and Chester, 1968; Pierce, 1963; Stone et al., 2011; Yamini and Schillhorn van Veen, 1988). This differs from what is seen in human schistosomiasis periportal fibrosis, which occurs without disruption of the hepatolobular architecture (Andrade, 2009). Similar to humans, *H. americana* has resulted in portal hypertension and associated sequelae. A raccoon with severe periportal fibrosis had granulomatous pneumonitis with fibrosis associated with parasite eggs (Bartsch and Ward, 1976). Fabrick et al. (2010) described 2 dogs with ascites secondary to severe liver disease and portal hypertension as has been described in humans with hepatosplenomegaly. Hanzlicek et al. (2011) described gross changes consistent with portal hypertension: distension of portal and pancreaticoduodenal veins. A byproduct of blood digestion by the worm, dark hemosiderin pigment, has also been observed in macrophages within the liver (Corapi et al., 2011a; Hanzlicek et al., 2011; Ruth, 2010).

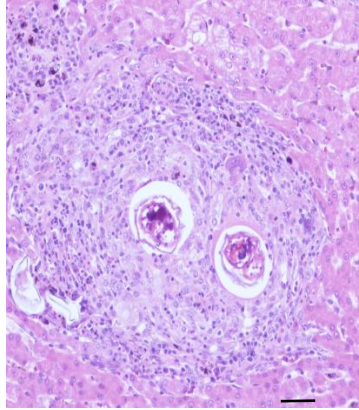


Figure 1.2 Histological section (H&E staining) showing *Heterobilharzia americana* eggs within granuloma in hepatic parenchyma. Size bar = 50 μ m.

Schistosomiasis in other organs/aberrant locations

In *H. americana* infections, eggs are also detected histologically in the pancreas (Table 1.3) with associated inflammation and fibrosis (Figure 1.3). Grossly, the pancreas may appear shrunken, or enlarged, swollen, or thickened with or without nodules on the serosal surface (Flowers et al., 2002; Hanzlicek et al., 2011; Rodriguez et al., 2016; Ruth, 2010; Troy et al., 1987).

In addition, eggs were identified in the mediastinum and heart of a horse, and pericardium and uterus of a llama (Corapi et al., 2015; Corapi et al., 2012). Parasite eggs in the heart of a horse lead to heart failure (Corapi et al., 2012). Myocardial necrosis and fibrosis likely due to vascular compromise by eggs led to congestive heart failure in a llama (Corapi et al., 2015).

In humans, neuroschistosomiasis occurs in a small percentage of people due to aberrant worm location in the brain or spinal cord, or in advanced hepatosplenic schistosomiasis, embolization of eggs via vertebral venous plexuses or portosystemic shunts

(Houston et al., 2004; Ross et al., 2012). Other ectopic locations of human schistosome eggs include the skin, ovaries, and adrenal glands (Poderoso, 2008; van Dijk et al., 2010).

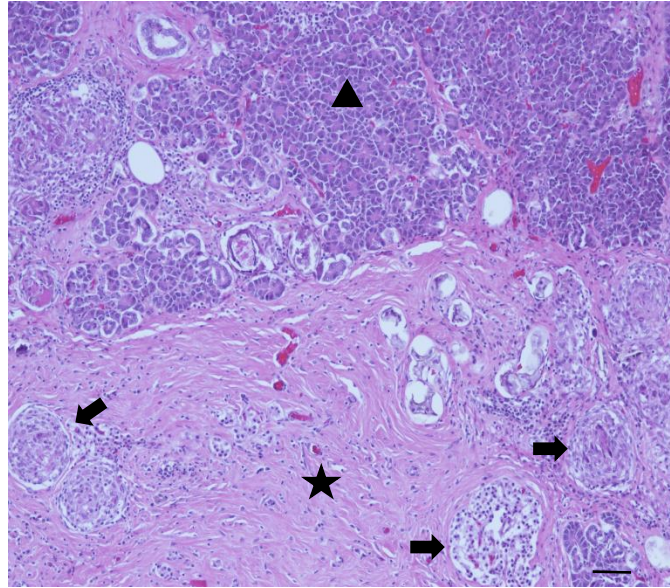


Figure 1.3 Histological section (H&E section) showing marked fibrosis and granulomatous inflammation in the pancreas of a dog secondary to trapped eggs of *Heterobilharzia americana*. Star = fibrosis; arrow = granulomas; triangle = normal pancreatic tissue. Size bar = 100 μ m.

Secondary pathological lesions

Renal disease associated with parasite infection has also been reported. Glomerulonephritis caused by *H. americana* infection was described in a clinical case report about one dog that was successfully treated (Ruth, 2010). Feldman and Chester (1968) described chronic glomerulonephritis in a euthanized dog. Glomerulonephritis associated with immune complex deposition is also documented in some humans infected with schistosomes (Andrade et al., 1971; Rodrigues et al., 2010). Metastatic mineralization of

kidneys and/or other organs has been described in dogs with hypercalcemia associated with *H. americana* (Fradkin et al., 2001; Rohrer et al., 2000).

Cercarial dermatitis

Inflammatory response secondary to skin penetration of cercariae (cercarial dermatitis) is most commonly documented in avian schistosomes infecting humans exposed in freshwater lakes and ponds, termed ‘swimmer’s itch’ (Horák et al., 2015). Dermatitis has also been documented in humans exposed to *H. americana* cercariae (Malek and Armstrong, 1967). In experimental infections, *S. douthitti* cercariae caused dermatitis in dogs (Herber, 1938). In dogs experimentally infected with *H. americana*, mild maculopapular eruptions were noted but resolved within 24 hours (Lee, 1962). These transient skin lesions may occur in naturally infected dogs, but may go unnoticed as it has not been reported in the literature. Similar mild dermatitis may occur in humans infected with human schistosomes (Jordan et al., 1993).

Clinical pathology

The most common laboratory abnormalities noted in confirmed *H. americana* canine case reports were elevated blood urea nitrogen (BUN), hypercalcemia, elevated creatinine, and hyperglobulinemia (Table 1.4). The hyperglobulinemia was characterized as a polyclonal gammopathy in 4 cases (Hanzlicek et al., 2011; Ruth, 2010; Troy et al., 1987). The azotemia (elevated BUN and creatinine) was most often attributed to renal damage secondary to persistent hypercalcemia. It was also attributed to severe protein losing nephropathy in one case (Ruth, 2010). Isosthenuria was present in five dogs, 3 that were hypercalcemic, and one with protein losing nephropathy.

Hypercalcemia cases in *H. americana* is theorized to be due to granulomatous inflammation secondary to eggs trapped in tissues (Fradkin et al., 2001). Similar cases of hypercalcemia has been documented in animals with bacterial and fungal infections; however, hypercalcemia is not present in the majority of these cases (Crews et al., 2007; Dow et al., 1986; Mealey et al., 1999). Activated macrophages produce calcitriol (1,25-dihydroxyvitamin D₃) (Dusso et al., 1990). Interestingly, 2 hypercalcemic dogs had elevated parathyroid hormone related protein (PTHrP), attributed to malignancies, with slightly low parathyroid hormone (PTH) levels and normal calcitriol levels. Both were euthanized with a diagnosis of occult malignancy; however no neoplasia was detected on necropsy (Fradkin et al., 2001). Three other hypercalcemic dogs had normal levels of PTHrP and calcitriol. Two of the three dogs had normal PTH levels (Hanzlicek et al., 2011; Le Donne et al., 2016; Rohrer et al., 2000). One had normal levels of PTH initially and then a low value after hospitalization (Rohrer et al., 2000). Elevated levels of PTHrP in the absence of malignancy has been documented in the human literature associated with benign neoplasms (Khosla and Danks, 1990; Knecht et al., 1996; Ravakhah et al., 1999). Marked elevated calcium levels resulting in renal disturbances has not been documented in the human literature; however, one study in children infected with *S. haematobium* showed elevated calcium levels that improved after treatment with praziquantel (Mohammed et al., 2006).

Table 1.4 Laboratory abnormalities reported for dogs infected with *Heterobilharzia americana*. BUN = blood urea nitrogen; ALT = alanine aminotransferase; ALKP = alkaline phosphatase.

Laboratory abnormality	Number of cases	Reference
Elevated BUN	8	Feldman and Chester, 1968; Fradkin et al., 2001; Hanzlicek et al., 2011; Le Donne et al., 2016; Rohrer et al., 2000; Ruth, 2010
Hypercalcemia	7	Fradkin et al., 2001; Hanzlicek et al., 2011; Le Donne et al., 2016; Rohrer et al., 2000; Troy et al., 1987
Elevated creatinine	6	Fradkin et al., 2001; Hanzlicek et al., 2011; Rohrer et al., 2000; Ruth, 2010
Hyperglobulinemia	6	Flowers et al., 2002; Hanzlicek et al., 2011; Le Donne et al., 2016; Ruth, 2010
Isosthenuria	5	Feldman and Chester, 1968; Le Donne et al., 2016; Rohrer et al., 2000; Ruth, 2010
Non-regenerative anemia	5	Flowers et al., 2002; Hanzlicek et al., 2011; Le Donne et al., 2016; Ruth, 2010; Slaughter et al., 1988
Elevated ALT	4	Flowers et al., 2002; Hanzlicek et al., 2011; Sponenberg, 1973; Troy et al., 1987
Elevated ALKP	4	Corapi et al., 2011a; Flowers et al., 2002; Hanzlicek et al., 2011; Sponenberg, 1973
Hypoalbuminemia	4	Corapi et al., 2011a; Hanzlicek et al., 2011; Roux et al., 2015; Ruth, 2010
Hypocholesterolemia	4	Corapi et al., 2011a; Hanzlicek et al., 2011; Le Donne et al., 2016; Roux et al., 2015

Five dogs from the literature had a non-regenerative anemia likely secondary to the chronic inflammatory condition. Hepatocellular damage and cholestasis in some dogs was documented by increased alanine aminotransferase (ALT) and alkaline phosphatase (ALKP) (Table 1.4). Additionally, severe hepatic disease leading to decreased hepatic function was inferred in dogs with hypoalbuminemia and hypocholesterolemia (Corapi et al., 2011a; Hanzlicek et al., 2011; Le Donne et al., 2016; Roux et al., 2015). Gastrointestinal loss of albumin could also contribute to hypoalbuminemia. Ruth (2010) documented hypoalbuminemia in a dog with protein losing nephropathy.

Fabrick et al. (2010) reviewed case histories of 22 dogs with *H. americana* as a diagnosis in a referral hospital. These cases were not included in this clinical pathology review because this case series consisted of dogs with *H. americana* as a primary (n = 15) and secondary (n = 7) cause of disease and clinicopathological information were combined. The most common hematologic abnormalities were lymphopenia, anemia, and eosinopenia. One dog presented with an eosinophilia, 9 were thrombocytopenic, and 4 were leukopenic. Nine of 11 azotemic dogs were hypercalcemic. Six dogs had an elevated ALT. Three of those dogs presented for primary hepatic disease.

Clinical signs

The most common clinical signs reported from case reports were weight loss, anorexia/hyporexia, and diarrhea (Table 1.5). Further characterizing the diarrhea, 3 fecals were described as bloody, 3 as bloody and/or with mucus, 1 mucoid, and 2 as melena (Flowers et al., 2002; Fradkin et al., 2001; Hanzlicek et al., 2011; Malek et al., 1961; Troy et al., 1987). One dog with glomerulonephritis and protein losing nephropathy was noted to have episodic periods of anorexia and flatulence without diarrhea or vomiting for 4 months (Ruth, 2010). Other reports describe dogs with intermittent diarrhea (Roux et al., 2015; Troy et al., 1987). A few dogs had marked weight loss of 1 to 15 months duration (Flowers et al., 2002; Roux et al., 2015; Stone et al., 2011). Two case reports noted other dogs in the household exhibiting similar clinical signs. (Fradkin et al., 2001; Troy et al., 1987). These clinical signs were similar to those reported by Fabrick et al. (2010) except that lethargy was the most common clinical signs and vomiting was more common than diarrhea. Two dogs were also noted to have borborygmus.

Table 1.5 Most common clinical signs reported in dogs infected with *Heterobilharzia americana*. PU/PD = polyuria/polydipsia.

Clinical sign	Number of cases	Reference
Weight loss	14	Flowers et al., 2002; Fradkin et al., 2001; Hanzlicek et al., 2011; Le Donne et al., 2016; Malek et al., 1961; Pierce, 1963; Rohrer et al., 2000; Roux et al., 2015; Ruth, 2010; Sponenberg, 1973; Stone et al., 2011; Troy et al., 1987
Anorexia/hyporexia	14	Corapi et al., 2011a; Feldman and Chester, 1968; Fradkin et al., 2001; Hanzlicek et al., 2011; Le Donne et al., 2016; Malek et al., 1961; Pierce, 1963; Rohrer et al., 2000; Ruth, 2010; Slaughter et al., 1988; Sponenberg, 1973; Stone et al., 2011
Diarrhea	11	Flowers et al., 2002; Fradkin et al., 2001; Hanzlicek et al., 2011; Malek et al., 1961; Pierce, 1963; Roux et al., 2015; Stone et al., 2011; Troy et al., 1987
Lethargy	10	Corapi et al., 2011a; Feldman and Chester, 1968; Fradkin et al., 2001; Hanzlicek et al., 2011; Le Donne et al., 2016; Rohrer et al., 2000; Slaughter et al., 1988
Vomiting	9	Corapi et al., 2011a; Feldman and Chester, 1968; Fradkin et al., 2001; Hanzlicek et al., 2011; Rodriguez et al., 2016; Roux et al., 2015; Stone et al., 2011
PU/PD	7	Feldman and Chester, 1968; Fradkin et al., 2001; Hanzlicek et al., 2011; Rohrer et al., 2000; Sponenberg, 1973
Tenesmus	2	Flowers et al., 2002; Hanzlicek et al., 2011
Flatulence	2	Flowers et al., 2002; Ruth, 2010

DIAGNOSTICS

The diagnosis of schistosome parasites can be categorized into 3 main categories: parasitological, immunodiagnostic, and molecular.

Parasitological

Fecal saline sedimentation is the main method of diagnosing *H. americana* parasitologically. Feces are mixed with saline in a cylinder and after settling, the supernatant is removed and the feces are washed again until the supernatant is clear. Aliquots of the sediment are observed microscopically for parasite eggs (Zajac and Conboy, 2012). Using saline as the sedimentation media is necessary to prevent miracidia from hatching. It is also possible to identify the eggs on a direct fecal saline wet mount (Ruth, 2010). The egg is clear

to golden brown and is round to oval (74-113 x 60-80 μm) with a thin shell (Zajac and Conboy, 2012). Unlike most trematode eggs, there is no obvious operculum as a distinctive morphologic feature. The clear miracidium within the egg is a distinguishing characteristic (Figure 1.4). Motile miracidia within the egg and partially or fully hatched miracidia may be observed (Figure 1.5).

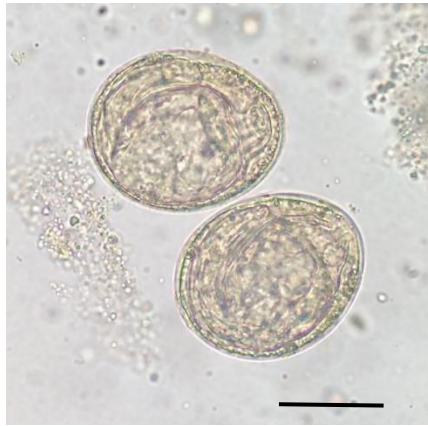


Figure 1.4 *Heterobilharzia americana* eggs from a fecal saline sedimentation test. A larval miracidium is folded inside the thin-shelled egg. Size bar = 50 μm .

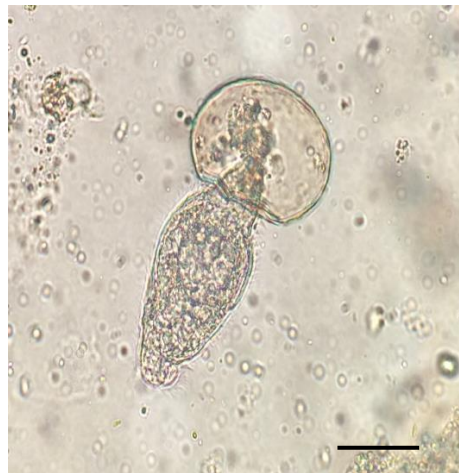

Figure 1.5 Partially hatched miracidium larva from *H. americana* egg. Size bar = 50 μm .

The miracidium hatching technique has also been used to diagnose *H. americana* infection, but is not routinely performed by diagnostic laboratories. Goff and Ronald (1980) evaluated the miracidia hatching technique in naturally infected raccoons and experimentally infected dogs. Feces were mixed with 0.85% saline and passed through a series of sieves and then after a series of washes was placed in a volumetric flask that was filled with distilled water. Water samples were obtained from the surface after 30 minutes and observed in a depression slide for motile miracidia. A similar assay is frequently used to diagnose *S. japonicum* sometimes in combination with immunological and parasitological tests (Fung et al., 2012; Yu et al., 2007).

In field studies determining schistosome infections in humans, the Kato-Katz method (KK) is the most commonly used technique (Katz et al., 1972). Feces are screened through a nylon seive and an aliquot is placed in a cardboard template that is standardize to measure 41.75 mg of feces for egg per gram (EPG) calculations. A cellophane strip that has been soaked in glycerin and malachite green is placed on the sample. The specimen is allowed to clear for up to 24 hours for proper visualization of schistosome eggs. Low egg numbers and day to day variation in egg shedding may lead to false negative test results. Eberl et al. (2002) concluded that the KK method could not reliably detected infections in fecal samples containing fewer than 100 EPG. Many studies have demonstrated that multiple Kato Katz examinations on a single stool sample and on multiple day samples increases prevalence in populations compared to a single sample. This is more apparent in low prevalent populations (de Vlas and Gryseels, 1992; Utzinger et al., 2001; Yu et al., 1998).

Sedimentation methods are less often used in detecting schistosome infections in humans in epidemiologic studies compared to KK due to the increased time and equipment

needed. Variations of sedimentation techniques include passive sedimentation similar to what is used to diagnose *H. americana* in dogs, formol ether sedimentation (FES), and the Percoll® technique (Eberl et al., 2002; Faust, 1946; Ritchie, 1948).

Multiple variations and modifications from the saline or water sedimentation have been described. Shidham (1991) described a passive digestion-sedimentation procedure that suspends feces with glycerol and benzoic acid. The solution compared to saline sedimentation appeared to clear debris to allow better visualization of eggs. Borel et al. (1999) showed that a similar digestion-sedimentation technique, using potassium hydroxide for digestion, was more sensitive in detecting light *S. mansoni* infections (1-100 EPG), detecting 100 infections that were missed by a single KK test; however, 35 KK positive subjects were not identified by the digestion-sedimentation technique. The sedimentation-selective filtration method involves mixing stool with water and glycerin, then after repeat washes, passing the sediment through a series of meshes. The filtered sample is then centrifuged or passed over filter paper and stained. This procedure had a relative sensitivity of 81.4% compared to 61.6% for a duplicate KK test; however the author noted that extensive time involved in this procedure may preclude its routine use (Polderman et al., 1994).

The Formol-ether sedimentation technique was developed to be a more sensitive method to detect parasite ova and oocysts than a direct fecal wet mount examination. Feces are homogenized with 10% formol-saline and strained through gauze into a centrifuge tube. Ether is added and the tube is centrifuged after vigorous shaking. The sediment at the bottom is observed microscopically for eggs (Ridley and Hawgood, 1956). Young et al. (1979) replaced the ether with ethyl acetate to reduce the use of a hazardous chemical. When

compared with the KK test, the sensitivity was comparable to 2 KK tests on the same sample, but was lower when 4 KK tests on the same sample were performed (Ebrahim et al., 1997).

The Percoll® technique is a fecal concentration method that involves mixing a 250 mg fecal sample in 3 ml of phosphor-buffered saline (PBS) which is then layered on top of 3 ml of 0.9% NaCl/60% Percoll® solution (Eberl et al., 2002). After centrifugation, the supernatant is removed and the remaining pellet is resuspended in 1 ml of PBS. The sample is then passed through a 150 µm mesh sieve into a collection tube. The eggs are then pelleted and transferred onto a glass slide with malachite green for observation. This method detected more experimentally infected chimpanzees (11 of 12) compared to triplicate KK on the same sample evaluated (3 of 12) (Eberl et al., 2002). When evaluated in humans, the Percoll® method detected patients with low egg counts more accurately and showed less variability in results when performed in duplicate on the same sample compared to KK performed in triplicates on the same sample. In addition, the Percoll® test detected 100% of infections in 14 subjects on the second day of testing versus the KK still not detecting 2 infections by the third sampling (Eberl et al., 2002). Additional studies further validated that the Percoll® method consistently outperformed KK when evaluating low endemic areas (Allam et al., 2015; Allam et al., 2009).

More recently, the FLOTAC® method has been evaluated for its performance in detecting schistosome infections in humans. It was developed to qualitatively and quantitatively detect parasite ova and cysts in stool samples (Cringoli, 2006). More recently it has been modified into the mini-FLOTAC to bypass the centrifugation step required in the original version (Barda et al., 2013). The benefit of this test is that it allows for a larger volume of feces to be analyzed, but because a zinc sulphate solution is used,

some deformation occurs with schistosome eggs compared to the KK method (Glinz et al., 2010).

Immunodiagnosics

Immunologic methods of diagnosing human schistosomiasis far outweigh other methods in the number of assays that have been developed (Gomes et al., 2014).

Immunodiagnostic methods have been primarily used to detect schistosome exposure by detecting parasite-specific humoral antibodies. More recently, antigen detection has also been employed.

Antibody detection

Currently there are no commercial immunodiagnostic tests available to detect exposure to *H. americana*, however an indirect hemagglutination assay (IHA) was developed using whole adult worm antigen (Goff and Ronald, 1982). This assay detected *H. americana* antibodies at least 60 days post experimental infection in 4 specific pathogen free dogs and 14 mixed breed dogs with other concurrent helminth infections. The majority of dogs with other concurrent helminth infections had baseline titers of <1:80 from before infection to up to 60 days post infection. In comparison, there was no detectable titer in the pathogen free dogs until day 60 except for one dog with a 1:40 titer on day 44 post infection. Because no further studies have evaluated the immune response of dogs to *H. americana*, the duration of time that antibodies persist post infection and post treatment is unknown.

Antibody detection in humans is useful in detecting infection in travelers not having been previously exposed to schistosome parasites, and in screening populations for exposure (Hinz et al., 2017). In general, the specificity of schistosome antibody detection tests is lower than parasitological methods due to cross-reactivity with other helminths as well as

residual titers after treatment to remove parasitic infections (Wen et al., 2005). It is unknown to what degree the low specificity of these antibody detecting immunodiagnostic tests is affected by the methods of gold standard comparison used in estimating test performance. Typically the KK method is used as the ‘gold standard’ comparison with variable numbers of replicates per sample and variable numbers of samples per subject. The sensitivity of KK has been shown to be low in lighter infections. Using imperfect gold standards can artificially lower the estimated specificity of immunodiagnostic tests (Goncalves et al., 2006; Hamilton et al., 1999; Kongs et al., 2001).

Hinz et al. (2017) thoroughly reviewed antigens and assays that have been used to detect human schistosome species. Antigens used in commercially available tests include the following: *S. mansoni* adult worm (*SmAW*) sections used in indirect immunofluorescence antibody test (IFAT); *S. mansoni* adult worm extract (*SmAWE*) and adult worm antigen (*AWA*); *S. haematobium* adult worm extract (*ShAWE*); microsomal *SmAWA* (*MAMA*), microsomal *S. haematobium* *AWA* (*HAMA*), and microsomal *S. japonicum* *AWA* (*JAMA*); *S. mansoni* soluble egg antigen (*SmSEA*); and *S. japonicum* soluble egg antigen (*SjSEA*). Recombinant and synthetic antigens are also being used on experimental bases with goals of improving specificity and not relying on an animal model to maintain the parasite life cycle for an antigen source (Hinz et al., 2017). Test formats include ELISA, immunomagnetic separation (IMS), and LMI (Luminex multiplex immunoassay).

SEA is the most common antigen used; however, cross reactivity to other trematodes (*Paragonimus* sp., *Opisthorchis* sp., *Fasciola* sp.), nematodes, and cestodes increases the rate of false positives depending on the human population being tested (Kinkel et al., 2012; Zhu et al., 2005; Zhu et al., 2002). Treating and purifying SEA improves the specificity (Alarcón

de Noya et al., 2000; Zhu, 2005). In China, serologic testing in epidemiologic studies of human exposure to *S. japonicum* have been used to a far greater extent compared to other schistosome species in other geographic areas. The IHA test using SEA is widely used in screening human populations in endemic regions for treatment. Yu et al. (2007) estimated the IHA test to be 80.3% sensitive and 48.4% specific when using the hatching test and duplicate KK tests on 7 consecutive fecal samples as the gold standard comparison.

A dipstick dye immunoassay (DDIA; Wuxi Saide Medical Technology Co. Ltd, Jiangsu, P.R. China) is a commercially available test that is convenient for field studies of *S. japonicum* in humans. The test has a high sensitivity but a moderate specificity (Xu et al., 2011). The DDIA test also exhibited excellent cross reactivity with *S. mekongi*, a closely related schistosome for which the life cycle is not readily maintained in a laboratory (Zhu et al., 2005).

Kinkel et al. (2012) directly compared 8 serological tests on sera from travelers known to be infected with *S. mansoni* or *S. haematobium*, including one in-house IFAT on paraffin-embedded adult *S. mansoni* worms; 3 in-house, non-commercial ELISAs using different crude *S. mansoni* antigen preparations (CA, AWA, SEA); 1 commercial ELISA test using AWA; 2 commercial ELISAs using SEA; and a commercial IHA using AWA. Serum samples from 37 known parasitologically positive travelers were compared and 35 of those were positive by at least one serological test, with a range in sensitivity per individual test from 40.5% to 78.3%. The two individuals with sera that were negative on all tests were infected with *S. haematobium*. There were 99 false negative results. There were also 48 of 832 (5.7%) false positive results when testing individuals with other parasitic infections and not from schistosome endemic regions, with individual test specificities ranging from 75.9%

to 100%. The test with the lowest specificity was an ELISA-SEA test. The authors determined that combining all in-house tests increased overall test sensitivity to 95.2% with a 93.3% specificity for detecting *S. mansoni* and that combining all commercial tests resulted in a 100% sensitivity for *S. mansoni*, but with a 75% specificity.

Antibody testing is useful for determining exposure to schistosome parasites and can be useful in detecting individuals with low egg counts that may be missed with parasitological testing. The cross reactivity of antibodies with other schistosome species is advantageous in detecting species of schistosomes that are not maintained in a laboratory setting; however, the cross reactivity with other parasitic infections is the main limitation of this diagnostic approach. The Kinkel et al. (2012) study, along with others, highlights the importance of using multiple diagnostic test methods to improve overall test performance (da Frota et al., 2011; Goncalves et al., 2006); however, increased expense may be a limiting factor.

Antigen detection

Circulating cathodic antigen (CCA) and circulating anodic antigen (CAA) are gut-associated antigens that are regurgitated from schistosome worms and detected in serum and urine of infected hosts. These highly glycosylated antigens are heat stable and soluble in trichloroacetic acid. These antigens are first produced in the cercarial stage (de Water et al., 1986). In experimentally infected mice, *S. mansoni* circulating antigens can be detected as early as 16-18 days post infection, before eggs are detected in feces (van Dam et al., 1996a). Antigen levels correlate with adult worm burden and egg excretion numbers and also vary less from day to day compared to egg counts in *S. mansoni* infections (de Jonge et al., 1989; Polman et al., 1998; Qian and Deelder, 1983; Van Etten et al., 1996). Antigen detection

directly correlates with an active infection with adult parasites compared to current or previous exposure measured by detection of antibodies resulting from the host immune response. Antigen levels decrease in a short time after treatment (Coulibaly et al., 2013; De Clercq et al., 1997; Kreamsner et al., 1994; Lamberton et al., 2014; van Lieshout et al., 1994). In one study, patients with *S. mansoni* infections were treated with a high dose of praziquantel and serum CAA levels dropped to 10% of the original value 48 hours after treatment (de Jonge et al., 1989).

Evidence of conserved structure and antigenicity of CCA and CAA in *Schistosoma* spp. is demonstrated by anti-*S. mansoni* CCA and CAA monoclonal antibodies in various antigen capture immunoassays detecting circulating antigens of *S. haematobium*, *S. japonicum*, *S. intercalatum*, *S. mattheei*, *S. bovis*, and *S. mekongi* (De Bont et al., 1996a; Johansen et al., 1996; Kreamsner et al., 1993; Kreamsner et al., 1994; Qian and Deelder, 1993; van Dam et al., 2015). Nonetheless, the amount of antigen produced by each parasite species and the clearance of these antigens in different host species may affect the ability to detect these antigens. Evidence of difference in clearance mechanisms or antigen production was shown in mice experimentally infected with *S. mansoni* and *S. japonicum* (Van 't Wout et al., 1995). Serum CAA concentrations were higher in *S. japonicum* infected mice compared to *S. mansoni* infected mice despite the recovery of lower numbers of *S. japonicum* worms. Relatively higher levels of CAA are detected in the serum and higher levels of CCA are detected in the urine of humans and animal models (Deelder et al., 1994; Krijger et al., 1994; van Dam et al., 1996a). This is in contrast to the relative levels of CCA and CAA produced by schistosomula and 7-week-old adult worms in culture (van Dam et al., 1996b). Although higher concentrations of CCA are produced by the parasites, it appears that CCA is more

readily cleared from host circulation. Abdeen et al. (1998) determined that CCA was excreted in the urine as a smaller molecular weight structure, theorizing that CCA is preferentially deglycosylated in the liver making it more readily filtered by the kidney compared to CAA. The neutral to positive charge of CCA compared to the negative charge of CAA may also contribute to the differential concentration of the antigens in the urine (van Dam et al., 1996a).

Antigen capture ELISAs using monoclonal antibodies were the most widely used laboratory assays to detect CCA and CAA (De Jonge et al., 1990; Deelder, 1989). More recently, a lateral flow, point-of-care assay detecting CCA (POC-CCA) in the urine was developed as a cost effective method for field use with the goal of replacing the need for fecal exam (van Etten et al., 1994).

The POC-CCA test is commercially available through Rapid Medical Diagnostics® (Pretoria, RSA) and has been used in several field studies to detect *S. mansoni* and other schistosomes. The test is comprised of a nitrocellulose strip that is held in a plastic cassette with a sample application window and a test result window. The conjugate pad contains colloidal carbon-labeled anti-CCA IgG1 monoclonal antibody conjugate that moves along the nitrocellulose strip with the 30 µl urine sample and 30 µl of a borate buffer. The test line contains IgG1 capture antibody. The control line contains polyclonal anti-mouse antibodies that capture the residual carbon-labeled antibodies (van Dam et al., 2004). A positive and valid result is indicated by a pink line at both the test and control line. More recently, the colloidal carbon label has been replaced with a gold label (Shane et al., 2011).

Since POC-CCA went on the market in 2008, several studies have compared this test performance with KK testing in different populations in Africa for *S. mansoni* and

secondarily for other related schistosome species. In a systematic review of these studies, it was found that the prevalence estimated by the POC-CCA and KK agreed well when the prevalence by 2 KK on a single stool or 2 KK on 3 daily samples was greater than 50% (Kittur et al., 2016). When the prevalence by KK was between 29-29%, the prevalence by POC-CCA was 2.5 times higher. When the prevalence was less than 10% by KK (2 studies), the prevalence by POC-CCA was 6 times greater than KK.

In the absence of a true gold standard, it can be difficult to determine if KK negative/CCA positive samples are true positive POC-CCA results. Mwinzi et al. (2015) demonstrated that KK negative/CCA positive subjects converted to CCA negative after 1-2 treatments with praziquantel, providing supportive evidence that those cases were true antigen positives. Other studies demonstrated better agreement between tests when more KK replicates on multiple fecal samples were used (Erko et al., 2013; Tchuem Tchuente et al., 2012). Specificity has also been evaluated by testing individuals in areas not endemic for schistosomes. Erko et al. (2013) tested 100 children in an area not endemic for schistosomes. Fifty percent of children had ascariasis and/or trichuriasis, and only one child tested positive on POC-CCA, demonstrating the high specificity of the assay in regards to coinfections with intestinal helminths. On the contrary, Coelho et al. (2016) detected false positive cases in individuals infected with *Ancylostoma*, *Hymenolepis nana*, *Enterobius vermicularis*, and *Ascaris lumbricoides* when a trace results were considered positive.

The presence of granulocytes in a urine sample could be the cause for trace or false positive tests. The main carbohydrate fraction of CCA contains Lewis-x repeating units (Van Dam et al., 1994). The surface of granulocytes also contain Lewis-x repeats (van Dam et al., 1996b) and binding of *S. mansoni* anti-CCA monoclonal antibodies to these repeats on

human granulocytes was demonstrated by positive antigen-capture ELISA results (van Dam et al., 1996b). Furthermore, sera from schistosome positive patients showed in vitro granulocytic activity. This activity was not observed in sera from patients with positive serology for *Fasciola hepatica*, *Onchocerca volvulus*, *Echinococcus granulosus*, *Loa loa*, or *Strongyloides stercoralis* (van Dam et al., 1996b). This epitope is not known to be present on other trematodes and nematodes except for *Dictyocaulus viviparus* (Cummings and Nyame, 1999; Haslam et al., 2000; Nyame et al., 1998). To ameliorate this potential for cross-reactivity, Grenfell et al. (2014) produced antibodies against the peptide backbone of CCA and selected for antibodies that did not bind to Lewis-X repeats.

Although several studies demonstrate superior performance of the POC-CCA, there is also evidence that this diagnostic test is less reliable in light to moderate infections with false negative rates ranging from 10-44% depending on whether or not a trace reading was considered positive (Legesse and Erko, 2007; Silveira et al., 2016; Stothard et al., 2006). The general consensus is that POC-CCA can be employed in areas with moderate to heavy *S. mansoni* infections but that areas of light infections need more sensitive methods, multiple testing, and/or a combination of different diagnostic tests (Coulibaly et al., 2011; Gomes et al., 2014).

POC-CCA tests have also been used in the field to detect other schistosome parasites with varying degrees of success. Stothard et al. (2006) showed a 0% sensitivity in children with parasitologically confirmed *S. haematobium* infections. To verify that the *S. mansoni* anti-CCA antibodies could detect *S. haematobium* CCA, crude worm antigen preparations were tested on the POC-CCA assays and were positive. This led the authors to conclude that the *S. haematobium* worms do not produce high enough levels of antigen to be detected by

this assay or that the *S. mansoni* anti-CCA antibodies have a greater affinity to *S. mansoni* CCA. It was also theorized that antigen-antibody complexes could have prevented test binding, but when samples were dissociated in buffer there was no change to positivity. It is also possible that if the CCA antigen is excreted in the urine in a peptide form, that the test antibodies may have a poorer affinity to this deglycosylated structure (Abdeen et al., 1998). Lastly, the *S. haematobium* antigens may be catabolized and cleared more quickly compared to *S. mansoni* (Kittur et al., 2016). Other field studies determined 41% (Obeng et al., 2008) and 52% (Ayele et al., 2008) sensitivities; however after test improvements were made (maintaining use of the same antibody) sensitivity increased to 79% in one study (Midzi et al., 2009).

In one study, the POC-CCA assay detected *S. intercalatum* antigens in infected schoolchildren (Kabore et al., 2017). Out of 50 tested, 24 subjects were positive by both KK and POC-CCA. Four were co-infected with *S. mansoni*. In addition, POC-CCA on banked urine samples of patients infected with *S. mekongi* resulted in 39 or 49% positive cases (trace negative versus trace positive) (van Dam et al., 2015). POC-CCA detected all but one sample with greater than 100 EPG based on KK test results. The POC-CCA test was also 65% sensitive for *S. japonicum* detection when trace was considered positive (van Dam et al., 2015).

An ultrasensitive method of CAA detection using sample concentration and up-converting phosphor technology shows promise to overcome the limitations of POC-CCA tests (Corstjens et al., 2014; van Dam et al., 2013). The test uses the same lateral flow format as the POC-CCA; however, it is not a field-based test and requires special equipment

including an ELISA shaker and an infrared reader. Standard purified antigen concentrations are used to determine antigen concentration of the samples.

Molecular

Molecular diagnostic methods are increasingly used for the detection of a variety of pathogens of medical and/or veterinary importance. A fecal *H. americana* PCR test is commercially available for dogs (Gastrointestinal Laboratory, Texas A&M University, College Station, TX); however, there are no literature reports on its methodology or sensitivity or specificity. One scientific abstract described designing a conventional PCR targeting the 18S ribosomal DNA gene (Bishop et al., 2008). Three dogs with detectable eggs on fecal saline sedimentation were positive on this PCR assay.

Fecal PCR has recently been used for detection of schistosomiasis in human epidemiologic studies. The number of PCR assays described in the literature is extensive. DNA targets for amplification include several sections of ribosomal RNA genes (large subunit 28S rDNA and internal transcribed spacer rDNA ITS1 and 2), cytochrome oxidase 1 (*cox1*), NADH dehydrogenase 1 (*nad1*) and 5 (*nad5*), and microsatellite DNA (Cnops et al., 2012; Weerakoon et al., 2015).

Cnops et al. (2012) designed primers to amplify a portion of the 28S rDNA gene of all schistosome species, termed ‘genusPCR’. This probe-based real-time PCR detected DNA in the feces and urine of travelers infected with *S. mansoni* and *S. haematobium*; however, it performed poorly on serum samples.

Highly repetitive DNA targets have also been commonly used in schistosome PCR assays with the advantage of high copy numbers in the genome and high species specificity. A 121 base pair (bp) tandem repeat sequence (Sm1-7) was determined to comprise at least

12% of the *S. mansoni* genome of both sexes (Hamburger et al., 1991). This target was used in the development of the first conventional PCR assay to detect *S. mansoni* in feces (Pontes et al., 2002). No amplification of DNA was detected when testing other human intestinal parasites for cross reactivity. Feces were artificially spiked and diluted 10 fold to make samples containing 216 EPG, 21.6 EPG, 2.16 EPG, and 0.216 EPG. PCR did not detect DNA in the most dilute sample, however it was superior to KK because the KK did not detect the eggs in the samples at the two highest dilutions. DNA was also detected in the serum of two infected individuals with feces containing 96 and 216 EPG. In a follow-up study performed on 194 individuals, PCR on a single fecal sample yielded a 38.1% prevalence compared to 30.9% prevalence by combining the results of the KK method on 3 consecutive fecal samples (Pontes et al., 2003). This tandem repeat molecular target has been used in several other studies. Oliveira et al. (2010) performed conventional PCR using the Sm1-7 repeat target on stool samples of individuals in low endemic setting with positive antibody serologic tests and negative KK tests. When combining these PCR results with a *nad1* gene target conventional PCR, PCR detected 59% of patients that were antibody positive and parasitologically negative on fecal exam. Both PCRs were highly specific due to the lack of DNA amplification of other parasites. Although the combination of these PCRs detected all subjects with fecal samples containing greater than 10 EPG, both PCRs missed detection of 3 out of 18 subjects with fecal samples containing fewer than 10 EPG. These discrepancies could be attributed to only performing PCR on a 1 gram aliquot of one of the three fecal samples submitted for parasitological exam, potentially resulting in the absence of an egg in the sample extracted. Nevertheless, overall the PCR tests detected more positive individuals using only 1 sample compared to KK on 3 samples.

Repeat sequence targets have also been used in developing PCR assays for other schistosome species. A 121 bp tandem repeat sequence (*DraI*), comprising approximately 15% of the *S. haematobium* genome (Hamburger et al., 2001) was used as a target to develop a sensitive real-time PCR test to detect cell free DNA in serum samples of humans (Cnops et al., 2013). A non-long terminal repeat retrotransposon was discovered in the *S. japonicum* genome (*SjR2*) (Laha et al., 2002). At roughly 10,000 copies it comprises up to 14% of the *S. japonicum* genome. A conventional PCR assay was developed targeting a 230 bp segment of *SjR2* (Xia et al., 2009). The PCR did not amplify DNA from *S. mansoni* or *Clonorchis sinensis*. In an experimental rabbit model, DNA was detected in the serum as early as 1 week after infection compared to a detection of an antibody response at 4 weeks and fecal egg detection at 7 weeks post infection (Xia et al., 2009). These data demonstrate the potential to use PCR assays to detect early infection in humans, especially in travelers.

Overall, PCR methods to detect schistosome infections in feces and body fluids seem promising; however, false negative results still occur due to absence of the parasite in a small extracted sample, or due to PCR inhibitors (Hoorfar et al., 2004). Including PCR testing in a series of testing may help to increase overall sensitivity of detection. Even though there is evidence of superior overall performance of PCR assays to parasitological methods, the added expense and equipment needed may prevent justification of this method in field studies. To counteract that limitation, loop mediated isothermal amplification (LAMP) is being used in field studies to detect DNA of schistosomes and other parasites. Only a water bath is needed to amplify DNA and a dye is used to visualize a positive result using that technique (Xu et al., 2010).

Surgical

H. americana has also been diagnosed by histopathological examination of biopsied tissues via exploratory laparotomy (Fabrick et al., 2010; Hanzlicek et al., 2011; McHenry et al., 2017; Ruth, 2010; Stone et al., 2011). Diagnosis has also been achieved via upper gastrointestinal endoscopy (Fabrick et al., 2010; Flowers et al., 2002; Hanzlicek et al., 2011; Rodriguez et al., 2016; Roux et al., 2015; Troy et al., 1987). One dog was also diagnosed by endoscopic lower gastrointestinal biopsy (Hanzlicek et al., 2011). *H. americana* diagnosis is usually inferred based on morphology of eggs or egg fragments, or characteristic granulomatous lesions in various tissues. Definitive diagnosis can be confirmed by PCR detection of parasite DNA in fresh or paraffin embedded formalin fixed tissues (Corapi et al., 2011a; Corapi et al., 2011b; Corapi et al., 2015; Corapi et al., 2012).

In addition to biopsies, Le Donne et al. (2016) described cytological diagnosis from a fine needle aspirate (FNA) of a dog liver, identifying egg shell fragments, rare miracidia, extracellular hematin, and mesenchymal cells likely from fibrous tissue.

Imaging

In addition to laboratory testing, discussed in *Clinicopathology*, imaging diagnostics used as an ancillary tool may increase clinical suspicion of *H. americana* infection. Granulomas and mineralized eggs may appear as hyperechoic pinpoint foci in ultrasound evaluation of the liver, pancreas, and intestines of infected dogs (Corapi et al., 2011a; Kvitko-White et al., 2011; Le Donne et al., 2016). The liver may also appear heterogenic or hyperechoic (Corapi et al., 2011a; Hanzlicek et al., 2011; Le Donne et al., 2016). Intestinal walls may appear thickened and/or hyperechoic (Flowers et al., 2002; Hanzlicek et al., 2011; Rohrer et al., 2000). The submucosal layer is most often described as thickened and

hyperechoic (Corapi et al., 2011a; Hanzlicek et al., 2011; Kvitko-White et al., 2011; Le Donne et al., 2016). Enlarged mesenteric and hepatic lymph nodes have also been detected by ultrasonography in dogs (Hanzlicek et al., 2011; Le Donne et al., 2016; Rohrer et al., 2000; Roux et al., 2015). Hyperechoic kidneys and nephroliths have been detected in hypercalcemic dogs (Le Donne et al., 2016; Rohrer et al., 2000). Visualization of mineralized eggs in tissues via ultrasound was documented in a canine case where high velocity Doppler produced a ‘twinkle artifact’ below the area of mineralization, appearing as if the area consisted of turbulent blood flow (Kvitko-White et al., 2011). Hyperechoic foci in horse livers with some acoustic shadowing termed ‘starry sky liver’ are documented in horses with mineralized fibrotic granulomas most likely attributed to *H. americana* infection (Carlson et al., 2011). Ultrasound is used to diagnose and to grade the severity of disease in humans with schistosomiasis in field settings. The appearance of periportal fibrosis is termed ‘bulls-eye’ lesions (Weerakoon et al., 2015).

Radiographic abnormalities are less apparent and have been described from a small number of severely affected cases. Linear mineralization in the wall of the intestines and stomach of infected dogs have been visualized, representing large numbers of mineralized eggs (Corapi et al., 2011a; Hanzlicek et al., 2011; Kvitko-White et al., 2011; Roux et al., 2015).

TREATMENT

There is no veterinary anthelmintic product that is labeled for treatment of *H. americana* in animals, and current extra-label recommendations lack significant evidence of efficacy. Currently suggested extra-label treatments for *H. americana* infection in dogs are

either fenbendazole granules (40 mg/kg by mouth PO every 24 hours for 10 days) (Ronald and Craig, 1983) or praziquantel (25 mg/kg PO every 8 hours for 2 days) (Troy et al., 1987). The fenbendazole dosage is based on data from an experimentally infected and treated dog (Ronald and Craig, 1983). The praziquantel dosage is directly extrapolated by Troy et al. (1987) from a dog with paragonimiasis that was successfully treated with that regimen (Kirkpatrick and Shelly, 1985). Several other case reports describe various treatments that include combining the 2 drugs (Fabrick et al., 2010; Ruth, 2010); however, data from clinical trials performed to compare different treatment protocols have not been published.

Praziquantel is the treatment of choice in human schistosomiasis at 40 mg/kg once for *S. haematobium* and *S. mansoni* and 60 mg/kg for *S. japonicum* and *S. mekongi* (Colley et al., 2014). The drug requires the host's immune response to be efficacious. Praziquantel is most effective against adult worms; therefore in areas of active transmission, immature stages may persist after one treatment, and it is recommended to repeat the treatment after 3 to 6 weeks (Colley et al., 2014).

DISSERTATION AIMS

Compared to the human literature on schistosomiasis, comprehensive knowledge of the clinicopathology, regional geographic distribution, and diagnosis of *H. americana* is lacking. The aims of this dissertation are to better characterize the disease caused by *H. americana* in dogs, map the distribution of cases in Texas, evaluate performance of parasitological and molecular methods of diagnosis, determine if circulating antigens are detectable in the serum and urine of infected dogs, and to determine highly repetitive DNA

sequence targets in the *H. americana* genome to develop a novel probe-based real-time PCR assay.

CHAPTER II
DISTRIBUTION AND CHARACTERIZATION OF *HETEROBILHARZIA AMERICANA* IN
DOGS IN TEXAS*

INTRODUCTION

Heterobilharzia americana is a trematode parasite endemic to the Gulf coast and south Atlantic region of the USA. The life cycle is similar to *Schistosoma mansoni* in humans. Male and female parasites live and reproduce in the mesenteric veins of mammalian hosts, and eggs migrate to the intestinal lumen and are excreted via the feces. A miracidium hatches from the egg, penetrates a fresh water snail (*Lymnaea cubensis* and *Pseudosuccinea columella*), multiplies and develops in the snail, and emerges in water as cercariae that infect the definitive host by penetration of the skin. Infection with *H. americana* is often termed schistosomiasis. As in *S. mansoni* infections, the eggs have the potential to disperse via circulation to multiple organs. The associated granulomatous inflammation can lead to a spectrum of clinical presentations from asymptomatic to severe disease and death.

Raccoons and nutria are considered to be natural hosts with infections also reported in opossums (Kaplan, 1964), bobcats, mountain lion (McKown et al., 1991), armadillo (Krotoski et al., 1984), white tail deer (Byrd et al., 1967), coyotes, red wolves (Custer, 1981), beaver (Fedynich et al., 1986), mink (Shoop and Corkum, 1982), swamp rabbits (Malek et al., 1961), and a captive born Brazilian tapir (Yamini and Schillhorn van Veen, 1988).

*Reprinted with permission from “Distribution and characterization of *Heterobilharzia americana* in dogs in Texas” by Rodriguez, J.Y., Lewis, B.C., Snowden, K.F., 2014. *Vet. Parasitol.*, 203, 35-42, Copyright 2014 by Elsevier B.V.

Parasites have been identified in wild hosts in an expanding range of geographic locations including Texas, Louisiana, Mississippi, Georgia, Florida, North Carolina, South Carolina, and Kansas (McKown et al., 1991). This wildlife-associated parasite has also been reported in horses in Texas (Corapi et al., 2011b). Additionally, dogs across the southern USA, and as far north as Kansas and Oklahoma have been documented with *H. americana* (Fabrick et al., 2010; Flowers et al., 2002; Hanzlicek et al., 2011; Johnson, 2010; McKown et al., 1991; Rohrer et al., 2000; Stone et al., 2011).

Multiple published case reports describe severely ill dogs at referral hospitals with patients typically undergoing a multitude of diagnostic procedures (Corapi et al., 2011a; Fabrick et al., 2010; Flowers et al., 2002; Fradkin et al., 2001; Hanzlicek et al., 2011; Rohrer et al., 2000; Stone et al., 2011). Based on clinical parallels with other schistosome parasites, we believe that these reports describing some dramatic clinical presentations, represent only the most severe cases from a spectrum of host–parasite interactions ranging from asymptomatic to fatal outcomes. To better document the spectrum of clinical presentations of dogs infected with this parasite, we conducted a retrospective case series review of canine *H. americana* cases from primary and referral veterinary hospitals in Texas.

MATERIALS AND METHODS

Texas canine *H. americana* case information was retrieved from several sources including histopathology and diagnostic parasitology records at the Texas Veterinary Medical Diagnostic Laboratory (TVMDL), College Station, Texas, for the period 1 January 1999 through 31 August 2012. Cases were also obtained from clinical records at the Veterinary Medical Teaching Hospital (VMTH) and necropsy/biopsy records of the

Diagnostic Pathology Service, Department of Veterinary Pathobiology (VTPB) at Texas A&M University (TAMU), College Station, Texas, for the period 1 January 1991 to 31 August 2012. Similarly, cases were obtained from the diagnostic parasitology records at the Clinical Parasitology Laboratory, VTPB, TAMU, for the period of 1 January 2007 to 31 August 2012. Positive cases using the fecal PCR (polymerase chain reaction) test for canine schistosomiasis from the Gastrointestinal Laboratory (GI Lab) at TAMU were collected from 28 February 2008 to 31 August 2012. This case series includes 20 patients that were previously described in a publication focusing on clinical features of the infection (Fabrick et al., 2010). Because this manuscript focuses on the characterization and distribution of *H. americana* cases in Texas, eight cases from other states were identified in the records review but not analyzed as part of the case series. These cases were from Kansas (Riley county, n = 2), Oklahoma (Pontotoc county, n = 1), Arkansas (Hempstead county, n = 1; Pulaski county, n = 1), Louisiana (East Baton Rouge Parish, n = 1; Jefferson Parish, n = 1), and Georgia (Thomas county, n = 1).

Histopathologically positive cases were defined as dogs with microscopic lesions consistent with infection by *H. americana*, in formalin-fixed, paraffin-embedded tissue sections stained with hematoxylin and eosin (H&E). Diagnostic parasitology positive cases were defined as dogs with microscopic identification of *H. americana* eggs on fecal sedimentation, flotation, or direct examination. Results reported by a fee-for-service laboratory (GI lab) are included for dogs diagnosed by molecular methods.

When available, history, signalment, clinical presentation, and county level geographic data were abstracted from all records. Because most cases did not have full clinicopathological information available and the ones that did consisted mainly of the cases

previously reviewed (Fabrick et al., 2010), the available laboratory data were not evaluated in depth for this case series; however, reported clinicopathological abnormalities by veterinarians upon sample submission were noted. Location data for canine cases were mapped using ArcGIS version 10.1 (ESRI, Redlands, CA). When possible, zip codes were obtained from the dog owner's address; however, many cases utilized the zip code information from the submitting veterinary clinic.

RESULTS

A total of 238 canine cases of *H. americana* in Texas confirmed by histopathology, fecal examination, and/or by PCR analysis were reported during the study period of approximately 22 years (Figure 2.1). Of these cases, 26 patients had 1–2 repeat positive tests ranging from 15 days to 4 years apart making a total of 268 positive tests (26 biopsies, 39 necropsies, 160 fecal examinations, and 43 PCR assays). There were 12 households with multiple infected dogs, ranging from 2 to 4 dogs.

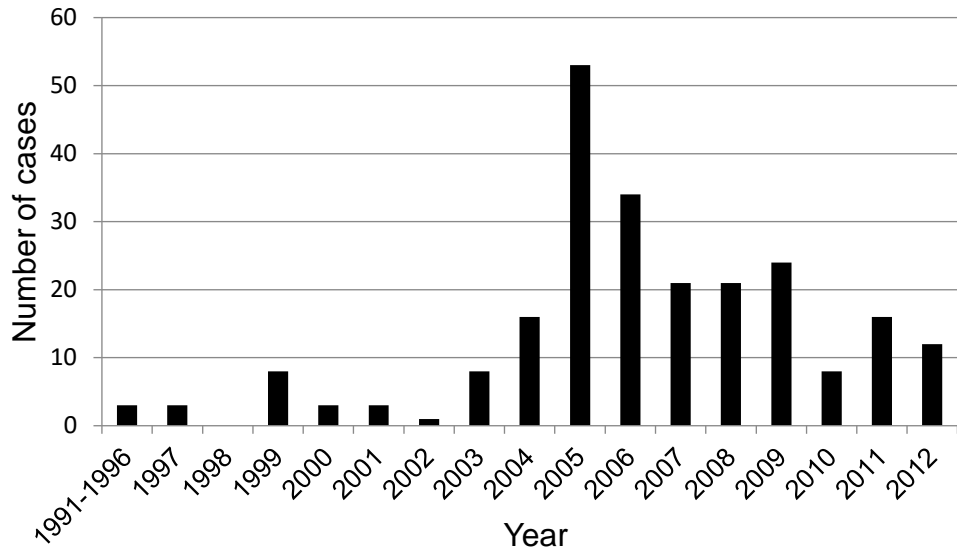


Figure 2.1 *Heterobilharzia americana* diagnosis among dogs in Texas by biopsy, fecal examination, or fecal PCR from 1991 to 2012 by year.

Geographic information was available for 236 dogs. Cases were distributed primarily in the eastern region of Texas from 42 of 254 counties (Figure 2.2). Kerr county was the furthest west location for a positive case. Five of the 11 counties along the Gulf of Mexico had infected dogs. Cases were also seen in Cooke and Fannin counties, bordering Oklahoma; Jefferson county, bordering Louisiana; and Hidalgo county, bordering Mexico. Bexar (n = 47; 2010 Census population of 1,714,773, including the city of San Antonio), Harris (n = 32; 2010 Census population of 4,092,459, including the city of Houston), and Galveston (n = 43; 2010 Census population of 291,309, coastal county south of Harris County) counties contained more than half of all cases.

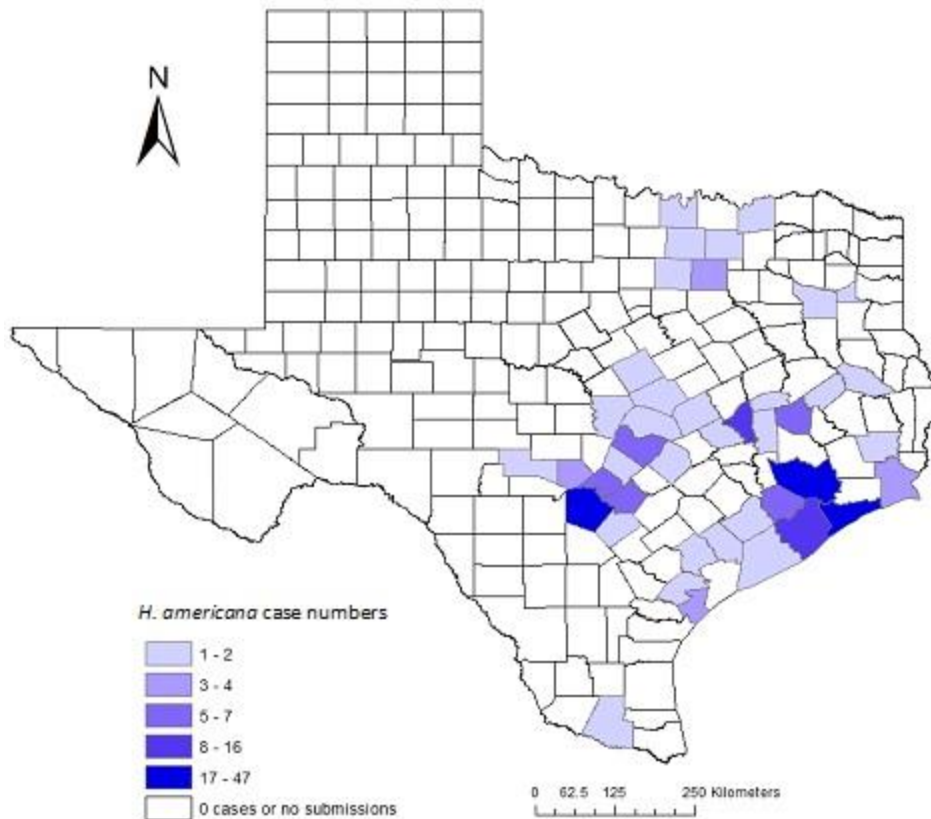


Figure 2.2 *Heterobilharzia americana* cases among dogs in Texas by county from 1991 to 2012.

Age of the dog was reported for 214 cases with a range of 0.4–17.2 years and a median of 5.5 years. Weight was reported for 170 cases with a range of 1–61.6 kg and a median of 19.6 kg. Gender was reported for 206 cases with 47.1% males (25.7% castrated, 21.4% intact) and 52.9% females (38.3% spayed, 14.6% intact). Breed was reported for 186 cases and all AKC breed groups were represented with crossbred, herding, and sporting groups in the highest numbers (Fig. 2.3). Dogs were diagnosed with the parasite infection year round (Fig. 2.4).

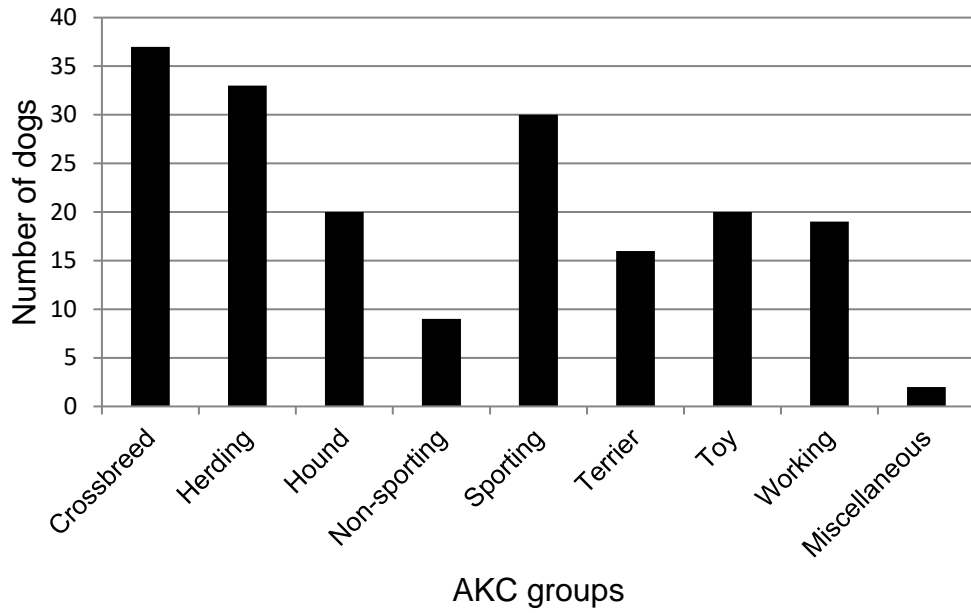


Figure 2.3 Breed distribution of canine *Heterobilharzia americana* cases in Texas by American Kennel Club (AKC) breed group.

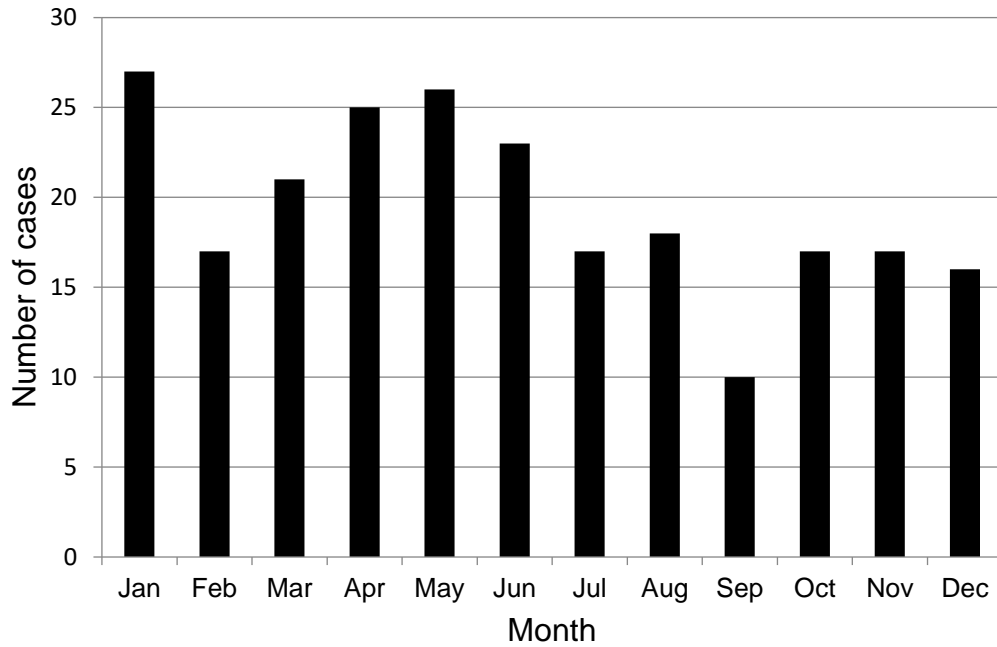


Figure 2.4 *Heterobilharzia americana* diagnosis in dogs by month in Texas.

Clinical signs were reported for 90 cases, and the most common include diarrhea (n = 60, 67%), weight loss (n = 34, 38%), anorexia/hyporexia (n = 24, 27%), vomiting (n = 20, 22%), hematochezia (n = 18, 20%), lethargy (n = 15, 17%), polyuria/polydipsia (n = 5, 6%), and collapse (n = 3, 3%) (Table 2.1).

Table 2.1 Clinical signs reported in 90 dogs diagnosed with *Heterobilharzia americana*

	Number of dogs (%)
Diarrhea	60 (67)
Weight loss	34 (38)
Anorexia/hyporexia	24 (27)
Vomiting	20 (22)
Hematochezia	18 (20)
Lethargy	15 (17)
Polyuria/polydipsia	5 (6)
Collapse	3 (3)

The majority of the 160 positive fecal examinations were by sedimentation; however, 7 were diagnosed by a direct fecal smear in saline and 3 by fecal flotation. Out of 38 fecal submissions, that included clinicopathological information in the patient history, the most common reported abnormalities were hypercalcemia (n = 13, 34%), elevated liver enzymes (alanine aminotransferase and/or alkaline phosphatase; n = 13, 34%), and elevated kidney values (blood urea nitrogen and/or creatinine; n = 5, 13%). Other reported abnormalities included eosinophilia, hyperglobulinemia, hyperbilirubinemia, and hypoalbuminemia.

A total of 39 dogs were diagnosed with *H. americana* at necropsy by histopathologic examination. Eggs were most commonly located in the small intestine, liver, large intestine, and pancreas (Table 2.2). Granulomatous inflammation associated with trapped eggs was the most common histopathologic change reported (n = 34, 87%). Less commonly, eosinophilic (n = 9, 23%) and lymphoplasmacytic (n = 5, 13%) inflammation were reported. Other histopathologic changes reported were fibrosis (n = 10, 26%), pigment in macrophages (n = 9, 23%), mineralization (n = 6, 15%), and bile duct hyperplasia (n = 2, 5%). Adult parasites were identified in three cases, and locations included veins of the small intestine, colon,

rectum, liver, lung, and pancreas. Granulomas consistent with *H. americana* infection were present in one kidney, however no parasite eggs were visualized.

Table 2.2 Proportion of tissues containing *H. americana* eggs in 39 canine necropsy cases. a. Two intestinal cases (not included) did not specify small or large intestine for egg location. b. Two were identified as mesenteric lymph nodes and one did not specify.

	# Positive/Total #	% Positive
Small intestine ^a	27/32	84
Liver	27/32	84
Large intestine ^a	11/28	39
Pancreas	11/31	35
Lymph node ^b	3/28	11
Lung	3/32	9
Spleen	1/22	5
Stomach	1/32	3

Based on pathology reports, death related to the presence of this parasite occurred in just over half (n = 20) of the 39 necropsy cases. Causes of death in these cases included euthanasia and apparent liver and/or renal failure. In all but one of these 20 cases, initial diagnosis was by post-mortem exam. That case had been previously diagnosed by liver biopsy. In five cases, dogs died acutely with no opportunity for diagnostics to be performed. In 11 cases, dogs were examined by a veterinarian and had various diagnostic tests performed. Differential diagnoses of these patients (when reported) included cholecalciferol toxicity, ethylene glycol toxicity, lymphoma, and pancreatitis. Seven of these 11 cases were euthanized, 2 died naturally, and there was incomplete information for the other 2 patients. In one case, *H. americana* was considered a differential diagnosis because another household dog had been diagnosed, and in another case because of stomach and small intestinal mineralization and infiltration changes seen on abdominal ultrasonography.

Based on pathology reports, in 19 of 39 (49%) cases, *H. americana* infection was an incidental finding and the cause of death or euthanasia was for other reasons including neoplasia, toxicities, congenital cardiomyopathy, bone fracture, pneumonia, gastric perforation, anesthesia complications, and polyradiculoneuritis.

A total of 24 dogs were diagnosed with *H. americana* by biopsy. Two dogs each had one repeat biopsy due to worsening of clinical signs despite treatment, for a total of 26 positive biopsy submissions. Biopsies were retrieved by endoscopy for 6 dogs and were collected during laparotomy for 18 dogs. Adult parasites were found in one biopsy sample. Submitted tissues containing eggs were the liver (13/13), small intestine (13/14), large intestine (7/8), pancreas (2/2), and the stomach (1/7). Inflammatory changes were similar to those of the necropsy cases. Fibrotic changes were seen in 31% of cases. Mineralization in biopsied tissues was not reported.

Of the 24 dogs diagnosed by biopsy, 23 had enough information to infer whether or not *H. americana* infection was related to the clinical signs warranting a biopsy. Disease related to the presence of the parasite occurred in 16 (70%) cases. Of those 16, *H. americana* was not reported as a differential diagnosis in 14 (88%) cases. Reported differential diagnoses were neoplasia and hepatic disease. In one case, *H. americana* was a reported differential because it had been diagnosed previously in a biopsy, and in another case, the radiologist reported that ultrasonographic changes suggested infection. Reasons for surgery in incidentally diagnosed cases (n = 7) were splenic masses/hemoabdomen (n = 4), gastric dilatation volvulus (n = 1), ovariohysterectomy (n = 1), and bile peritonitis (n = 1). Reasons for obtaining biopsy samples at the time of surgery in these cases were due to gross lesions of the small intestine or liver, or to rule out metastatic disease.

Therapeutic treatment and outcome were not available for the majority of cases diagnosed through TVMDL (fecal sedimentations, biopsies, and necropsies) which comprises the majority of cases in this case series. Detailed treatment (n = 16) and outcome (n = 18) information was available for dogs in this case series admitted to TAMU VMTH and have previously been described in detail by Fabrick et al. (2010).

DISCUSSION

This case series of canine *H. americana* infections reviews a large number of records from multiple sources over a long time period. The majority of the cases were patients from primary care veterinarians which represents the general population of dogs affected by this parasite. *H. americana* infections were identified in dogs from a broad range of ages, sizes and breeds, with an even gender distribution and no obvious seasonality. The highest number of cases were diagnosed in 2005 (n = 55) with 17 cases being diagnosed the previous year. No statistical analyses have been performed to determine the significance of the increased cases or potential causes; however, the number of submitted fecal sedimentation tests increased over eight times that of submissions the year before.

H. americana infected dogs were disbursed widely across the eastern region of Texas, along the Gulf Coast and reaching the borders of Oklahoma, Louisiana, and Mexico. Relatively higher county case numbers were in some coastal and major metropolitan areas. Because all sample submissions were received in College Station, Texas, it is possible that geographic representation of cases may be biased toward this area. The distribution of canine cases in higher populated areas (Houston and San Antonio) may be linked to the higher human population numbers; however, the focus of this report is clinical in nature, and

population-based spatial and statistical analyses were not conducted for this study. One factor contributing to the high number of cases recorded in Bexar county was a cluster of infection in a group of working dogs (n = 16) that was associated with a common source of infected water in 2005–2009 (outbreak details are unpublished). Ten of these dogs were diagnosed in 2005 and contributed to the increased number of positive cases and test submissions compared to the year prior. Also for many of the TVMDL submissions, only the zip code of the veterinary clinic was provided which may differ from the pet residence; however, because counties were used for case counts, this source of location is unlikely to affect the overall distribution map for this parasite. No cases were identified in west Texas or the panhandle. This absence may be because the snail intermediate host is not present or because submissions were not made to the TVMDL and no referrals were made to TAMU. Because no travel history for animals was obtained, it is possible that a positive case was acquired in a different county or state, but transmission through local water source exposure and cercaria penetration of skin is the most likely source of exposure.

Twenty-six dogs had repeat positive tests including one case that was positive for eggs by biopsy 4 years apart. The dog was treated orally with 25 mg/kg of fenbendazole twice a day for 14 days and 25 mg/kg of praziquantel three times a day for one day. Based on available information in that case, it is unclear whether treatment failed and the parasite had longevity greater than 4 years, or if this was an example of a repeat infection. To the authors' knowledge, there is no documentation of the longevity of the parasite in dogs; however, evidence from an immigrant to the USA showed the closely related parasites, *S. mansoni* and *S. haematobium*, to have a parasite longevity as long as 26–40 years (Berberian et al., 1953). In another report regarding a population where transmission of *S. mansoni* was stopped,

worm survival estimates calculated in untreated individuals ranged from 5.5 to 35 years (Vermund et al., 1983). It is likely that parasite survival in dogs is similar to these schistosome species in humans. It is also possible that some repeated tests were performed too early (as little as 15 days from initial testing), and even in successful parasite treatment, residual eggs were still being shed.

In 12 households, diagnostic testing showed that more than one dog was infected. Dogs were usually diagnosed concurrently a few days apart, but some up to almost 3 years apart. In one household, four dogs were admitted to the intensive care unit at the VMTH for hypercalcemia within a period of 10 days. In another household, two dogs were admitted to the VMTH for severe illness and died within 4 days of one another, and both were initially diagnosed at necropsy. Based on the parasite life cycle, it is probable that the animals were exposed to a common water source where infective cercariae were present. These data emphasize the importance of testing all dogs in the household if one animal is positive for the parasite. Additionally, owners should be informed of the life cycle of the parasite and questioned regarding the possible exposure of the dog to a water source with cercariae and appropriate snail intermediate hosts in order to prevent further exposure to the parasite.

There were several differences in the presenting clinical signs between our larger series of cases and the previous clinical report of 20 patients that presented to a tertiary care facility (VMTH, TAMU). In Fabrick et al. (2010), the most common clinical signs reported were lethargy, weight loss, and hyporexia, followed by vomiting, anorexia, and diarrhea. In this case series, diarrhea was the most commonly reported clinical sign, followed by weight loss, anorexia/hyporexia, and vomiting. Because the majority of cases in this case series consists of patients diagnosed by a fecal examination submitted by their primary care

veterinarian, diarrhea may be an important first clinical sign before disease progresses and other more severe signs develop.

Clinicopathologic data was most complete for patients referred to the VMTH at TAMU. In this review, the most common clinicopathologic abnormalities reported on the submission forms for fecal exam by veterinarians were hypercalcemia, elevated liver enzymes, and elevated kidney values (in descending order). These lab results differ from Fabrick et al. (2010) in which hyperglobulinemia, elevated prothrombin time, and hypercalcemia were the most common changes reported.

In schistosome infections, the broad tissue distribution of parasite eggs can result in varied and confusing clinical presentations. In humans, the most common locations for ectopic schistosome parasite eggs are the lungs, reproductive organs, and central nervous system (Gryseels et al., 2006). Other reported locations include the skin, thyroid, pancreas, adrenals, and heart (Andrade, 1987b). Some proposed mechanisms for aberrant location of eggs include hematogenous dissemination of eggs and migration of adult worms (Carod-Artal, 2010; Feldmeier et al., 1998). Worm migration with *H. americana* was evident histologically in two necropsy cases with worms found in the lung and pancreas. Proposed reasons for migration of adult worms in human schistosomiasis include fibrosis of the liver in chronic infections and overcrowding (Feldmeier et al., 1998); however, aberrant egg location has been seen in several travelers with low burdens of worms (Gryseels et al., 2006). In this case series, the pancreas was the third most common organ containing parasite eggs. This is an important observation for dogs in endemic areas presenting with signs of pancreatitis. Fecal sedimentation/PCR testing and deworming are not standard protocols for pancreatitis patients.

Fibrosis was the second most common histopathologic change after inflammation and was seen most commonly in the liver. Periportal bridging fibrosis was reported in seven cases. In at least one case, fibrosis in the liver was severe enough to lead to portal hypertension and acquired portosystemic shunts. Similar changes occur in humans infected with *S. mansoni*. The severity of changes in humans is primarily linked to parasite load. Interestingly, with successful treatment, hepatic fibrosis in people can regress, but may take years for infections of long duration (Andrade, 2009). It is unknown if fibrosis regression also occurs in affected dogs with *H. americana*. In several cases, the death or euthanasia in dogs was attributed to fibrotic changes in the liver, which stresses the importance of early diagnosis and proper treatment. If the potential for regression of fibrotic lesions exists in dogs, supportive care during the reparative process would be beneficial.

In 26 of 62 (42%) cases of necropsies and biopsies, *H. americana* was an incidental finding. This observation suggests that there are dogs with *H. americana* infection but lacking overt clinical signs. Whether or not these infections would lead to disease is unknown; however, it may be warranted to perform annual fecal sedimentation or PCR exams along with the recommended fecal flotations on dogs in endemic areas, especially dogs that are exposed to fresh water sources that could serve as a habitat for the appropriate snail intermediate host.

The small number of cases that had *H. americana* as a differential diagnosis stresses the lack of awareness of this parasite and the importance of history and ancillary diagnostics. In two cases, ultrasonographic changes suggested mineralized intestinal granulomas and *H. americana* was suspected. A previous case report of a severe infection describes ultrasonographic changes seen in detail (Kvitko-White et al., 2011). The most common

intraoperative and necropsy gross findings were due to granulomas on the serosal surface of the intestine and liver. In a biopsy case, visible lesions were assumed to be neoplasia by a submitting veterinarian. It is important to remember that infectious and inflammatory processes can grossly resemble neoplasia and cytology and/or histopathology should be performed before a presumptive diagnosis is made intraoperatively.

As discussed previously, detailed therapeutic treatment and outcome information was available primarily for cases admitted to TAMU VMTH and have been previously described in Fabrick et al. (2010) with a potential good to excellent prognosis with proper diagnosis and treatment. Reported treatments for *H. americana* include fenbendazole (40 mg/kg every 24 h for 10 days) (Ronald and Craig, 1983), and praziquantel (25 mg/kg every 8 h for 2 days) (Slaughter et al., 1988). Variations and combinations of these treatments have been reported in the literature (Fabrick et al., 2010; Flowers et al., 2002; Ruth, 2010; Troy et al., 1987). Oral tablets or subcutaneous injections of praziquantel have been administered based on the available formulation of the drug and whether or not the patient was vomiting (Fabrick et al., 2010). One patient was successfully treated with fenbendazole at 24 mg/kg every 24 h for 7 days, concurrently with praziquantel at 10 mg/kg every 8 h for 2 days (Ruth, 2010). Treatment failed in one dog that was administered praziquantel at the recommended cestocidal dose (5 mg/kg). This dog was then treated successfully with a single subcutaneous dose of 11.3 mg/kg of praziquantel concurrently with an oral dose of praziquantel at 30 mg/kg (Flowers et al., 2002).

Glomerulonephritis associated with *H. americana* has been reported previously in 1 canine case (Ruth, 2010). In our case series, glomerulopathies were present in 11.8% (4/34) of necropsy cases, with 3 incidences of membranous glomerulonephritis and 1 with

glomerulosclerosis. In the human literature membranous glomerulonephritis and glomerulosclerosis have been associated with hepatosplenic schistosomiasis caused by *S. mansoni*. The prevalence of glomerulonephritis in our case series is similar to a retrospective cases series of autopsies of humans with hepatosplenic schistosomiasis (12%) (Andrade et al., 1971) and a prospective human study evaluating percutaneous renal biopsies of affected patients (12.7%) (Rodrigues et al., 2010). Renal damage is probably due to immune complex deposition on the glomerular basement membrane (Andrade and Van Marck, 1984; dos-Santos et al., 2011; Rocha et al., 1976). Based on these findings from medical literature, monitoring renal function may be warranted in canine *H. americana* cases. Chronic proteinuria, isosthenuria, and/or elevated creatinine values may suggest glomerulopathies that have the potential to affect the long-term prognosis for dogs with this parasite infection.

There has been one report of concurrent neoplasia (lymphosarcoma) and *H. americana*, suggesting an association (Stone et al., 2011) as has been suggested with schistosomiasis in humans (Palumbo, 2007). In this case series, there were 14 dogs with concurrent neoplasia (4.5–12.1 years old). The types of neoplasms present were hemangiosarcoma (n = 5), lymphoma (n = 1), hepatocellular carcinoma (n = 2), invasive carcinoma (n = 1), hepatocellular adenoma (n = 1), chemodectoma (n = 1), osteosarcoma (n = 1), leiomyoma (n = 1) and multiple myeloma (n = 1). There were four cases where parasite eggs and neoplasia were present in the same organ: lymphoma in the small intestine, hemangiosarcoma in the liver, leiomyoma in the jejunum, and adenoma in the liver. At this stage no associations of neoplasia and *H. americana* in dogs can be made without epidemiologic studies including a larger number of cases.

This retrospective study has some limitations. Although we have included a large number of positive dogs in Texas, cases that may have been diagnosed by histopathology at commercial diagnostic labs were not evaluated. To the authors' knowledge, fecal sedimentation tests are not offered at major commercial labs in Texas. It is possible that this parasite can be diagnosed by a direct fecal exam or flotation as was seen with a small number of cases in this series, however, the sensitivity of these methods is very low. It is unknown how many practitioners now recognize and treat this parasite without using external diagnostic support from fee-for-service diagnostic laboratories, but these potential cases would not be included in this study.

H. americana is more common in dogs and the distribution in Texas is more widespread than generally recognized. Because current fecal tests are not readily performed in house and rely on egg shedding which may be intermittent, additional diagnostic testing methods need to be explored. Also, prospective epidemiologic studies may help increase clinical knowledge by identifying significant risk factors. There is a broad range of clinical presentations of this parasite, from acute to chronic, and from asymptomatic to fatal. A key importance for early and proper diagnosis of *H. americana* is awareness of the parasite by the veterinarian.

CHAPTER III
DETECTING CIRCULATING CATHODIC AND ANODIC ANTIGENS IN DOGS
NATURALLY INFECTED WITH *HETEROBILHARZIA AMERICANA*: A
COMPARATIVE DIAGNOSTIC METHODS STUDY

INTRODUCTION

Heterobilharzia americana is a trematode parasite (Family: Schistosomatidae) of dogs, raccoons, and other mammals in the southeastern United States and parts of the Midwest (Johnson, 2010; Rodriguez et al., 2016). Dogs become infected through exposure to fresh water containing larval cercariae released from intermediate host lymnaeid snails. Adult worms live in the mesenteric veins, and eggs migrate into the intestinal lumen to be released in the feces. Eggs are also associated with granulomatous inflammation in other organs (pancreas, spleen, lung) via circulation or aberrant worm location (Corapi et al., 2011a; Fabrick et al., 2010). Affected dogs may be asymptomatic or have a wide range of non-specific clinical signs including weight loss, diarrhea, vomiting, and anorexia (Fabrick et al., 2010; Rodriguez et al., 2014).

H. americana is an under-recognized parasite because of its inability to be detected on routine fecal flotation methods, variable clinical presentations in dogs, regional geographic distribution, and relative lower prevalence compared to common intestinal parasites. Commercially available diagnostic tests for veterinary use for detecting *H. americana* are limited and including fecal saline sedimentation tests at some fee-for-service laboratories, and a fecal real time PCR test (Gastrointestinal Laboratory, Texas A&M University, College Station, TX). No studies have compared performance of these two tests,

leaving veterinarians unable to make informed decisions on diagnostic test choices. In addition, egg shedding may be low or intermittent, leading to false negative parasitological test results.

Human schistosome parasites, primarily *Schistosoma mansoni*, *S. haematobium* and *S. japonicum*, are ranked the second most devastating parasite to humans worldwide, infecting more than 250 million people worldwide (Colley et al., 2014). Eradication efforts and detection of infection among travelers and laboratory workers rely on accurate diagnostic testing. Currently employed medical diagnostics include parasitological, immunodiagnostic, and molecular testing (Colley et al., 2014). In addition to serologic detection of host antibodies, antigen detection is being used to detect active infection and to decrease the cost and time of conducting surveys of target human populations (Colley et al., 2013).

Circulating cathodic antigen (CCA) and circulating anodic antigen (CAA) are gut associated antigens of schistosome parasites that have been utilized as immunodiagnostic targets (Deelder et al., 1976). These antigens are regurgitated from the worm and are detected in the urine and serum of the hosts (Deelder et al., 1994). These highly charged antigens are partially conserved across schistosome species and have been detected in humans infected with *S. mansoni*, *S. haematobium*, *S. japonicum*, *S. mekongi*, and *S. intercalatum* (Kremsner et al., 1993; Midzi et al., 2009; van Dam et al., 2015). Similarly, these antigens have also been detected in cattle infected with *S. mattheei* and *S. bovis* (de Bont et al., 1996b; Johansen et al., 1996). A commercially available point-of-care lateral flow assay (POC-CAA; Rapid Medical Diagnostics, Pretoria, RSA) has been developed to rapidly detect antigen in the urine of humans infected with *S. mansoni*, a parasite similar in life cycle and pathology to *H. americana* (van Dam et al., 2004). These point of care tests

have shown varying sensitivities in detecting *S. haematobium* and *S. japonicum* infections (Midzi et al., 2009; van Dam et al., 2015).

In this study, we aim to determine if these point-of-care tests can be used to detect CCA and/or CAA antigen in urine or serum from dogs naturally infected with *H. americana* by comparing test performance with fecal saline sedimentation and fecal PCR tests. In doing so, we also evaluate test performance for all of these diagnostic test methods.

MATERIALS AND METHODS

Selection of dogs and data collection

Sample submissions from client-owned animal cases were recruited from referring veterinarians by distributing *H. americana* informational brochures at veterinary related events, and emailing local veterinary medical associations and clinicians at the Texas A&M Veterinary Teaching Hospital (VMTH). We targeted potential *H. americana* cases using the following inclusion criteria: clinical signs consistent with infection; current diagnosis of *H. americana* based on fecal saline sedimentation tests, fecal PCR tests, or liver/intestinal biopsies; or shared environment with suspected or confirmed cases (cohort dogs), whether or not dogs were exhibiting clinical signs. Age, breed, and geographic location were obtained. When available, a clinical history for each submitted case was obtained from the referring veterinarian.

Voided urine and stool samples were collected by the veterinary staff or pet owner. Veterinary staff performed venipuncture on the jugular, cephalic, or lateral saphenous veins to collect up to 3 mls of whole blood for serum. Samples were mailed by the submitting veterinary clinic overnight on ice to our laboratory at Texas A&M University College of

Veterinary Medicine and Biomedical Sciences (TAMU-CVMBS). Samples collected at the VMTH were hand delivered to the laboratory.

Feces for fecal saline sedimentation test (FSS) were either immediately tested or refrigerated overnight. Two 200 mg aliquots of feces were stored at -20°C and DNA was extracted for PCR testing within one week. Urine and serum were tested within 24 hours of receipt and remaining samples were frozen at -20°C. All diagnostic tests were performed at TAMU-CVMBS.

All work was conducted under an animal use protocol (AUP) approved by the Institutional Animal Care and Use Committee (IACUC) at Texas A&M University.

Fecal saline sedimentation test (FSS)

The fecal saline sedimentation procedure (FSS) followed a standard published protocol (Zajac and Conboy, 2012). Ten grams of feces were mixed with 100 mls of 0.2% NaCl solution and poured into a 100 ml cylinder after straining through gauze. After one hour, the supernatant was decanted and the sediment was resuspended in additional 0.2% NaCl. This process was repeated until the supernatant was clear. The entire sediment sample was then transferred into a 50 ml conical vial and allowed to settle for one hour and the supernatant was decanted. Ten, 30 µl aliquots of the sample were examined under light microscopy using 100 x magnification. Samples were considered positive if at least one *H. americana* egg was observed. Samples were considered negative if no egg was observed in the aliquots. Egg counts from each slide were compiled and recorded.

Concentration of fecal sediment for DNA extraction

The remaining fecal sediment was centrifuged at 5,000 x g for 10 minutes and the supernatant was decanted. A 200 mg aliquot was retained for DNA extraction and PCR testing, and a second 200 mg aliquot was stored at -20°C for future evaluation.

Fecal DNA extraction and PCR (PCR-ff and PCR-sedi)

DNA was extracted from 200 mg of fresh feces (PCR-ff) and 200 mg of concentrated fecal sediment (PCR-sedi) from each case using a commercial kit according to the manufacturer's protocol (QIAamp Fast DNA Stool Mini Kit, Qiagen, Valencia, CA) with modifications to increase DNA yield: The fecal supernatant from the centrifuged fecal lysate was doubled from 200 µl to 400 µl. Accordingly, proteinase K, Buffer AL, and ethanol quantities were doubled, as well as repeating the initial spin column step to accommodate the doubled lysate volume. After completing the DNA extraction, the DNA was concentrated using isopropanol precipitation and dissolved into 25 µl of Tris-EDTA (TE) buffer either overnight at room temperature or at 55°C for 1-2 hours. The DNA concentration was determined using spectrophotometry (NanoDrop, Thermo Scientific, Waltham, MA).

Conventional PCR was performed to amplify a 487 base pair fragment of the 18S rRNA gene (rDNA) of *H. americana* using a previously published protocol (Corapi et al., 2011a). The 50 µl reaction mix contained 25 µl of master mix containing *Taq* DNA polymerase, dNTPs, MgCl₂, and reaction buffers (GoTaq® Green Mastermix, Promega, Madison, WI), 10 pmol of each primer (Het 1298F 5'-ATGGCCGTTCTTAGTTGGTG-3' and Het 1824R 5'-CGTCTTCTCAGCATCAGTCG-3'), 2 mM MgCl₂, 0.5 mg of bovine serum albumin (BSA), 20.5 µl of sterile water, and 50 ng of DNA template. The PCR reaction was set to the following conditions on a thermocycler (MyCycler™ Thermal Cycler,

Bio-Rad Laboratories, Inc., Hercules, CA): Initial denaturation at 95°C for 2 minutes; 35 cycles of a denaturing step at 95°C for 45 seconds, annealing step at 55°C for 45 seconds, and an elongation step at 72°C for 60 seconds; followed by a final elongation step at 72°C for 5 minutes. Amplicons were analyzed on 1.5% agarose gel stained with ethidium bromide. Appropriately sized bands were excised from a low molecular weight agarose gel, and DNA was extracted using a commercial kit according to the manufacturer's protocol (Wizard® SV Gel and PCR Clean-Up System. Promega, Madison, WI).

Small subunit rRNA gene sequencing

Sequencing was performed on all amplicons of appropriate size in both directions using the same primer set. Each sequencing reaction was performed according to the manufacturer's instructions (BigDye® Terminator v3.1 Cycle Sequencing Kit, Life Technologies, Carlsbad, CA) and amplicons were purified using gel filtration cartridges (Performa® DTR Gel Filtration Cartridges, EdgeBio, Gaithersburg, MD). The purified amplicons were submitted to a fee-for-service laboratory (Gene Technologies Laboratory, College Station, TX) for Sanger sequencing.

DNA sequence analysis software (Sequencher 5.0, Gene Codes Corporation, Ann Arbor, MI) was used to assemble consensus DNA sequences from forward and reverse sequences. *H. americana* identity was verified using the National Center for Biotechnology Information Basic Local Alignment Search Tool (NCBI BLAST) which contains 18S ribosomal DNA sequences for *H. americana* (accession nos. DQ230918 and AY157220).

Point-of-care antigen testing (POC-CCA and POC-CAA)

POC-CCA: The commercial point-of-care lateral flow assay (Urine-CCA cassette test; Rapid Medical Diagnostics, Pretoria, South Africa) was used for canine urine samples

following manufacturer's instructions. One drop of urine (30 μ l) was applied in the test well of the cassette, followed by 1 drop of buffer supplied in the kit. The urine sample was considered positive if a pink test line of any intensity was visible after the recommended 20 minute incubation time.

POC-CAA: The experimental point-of-care lateral flow assay (Urine-CAA cassette test; Rapid Medical Diagnostics, Pretoria, South Africa), which is designed to use with human urine samples, was used with concentrated serum after protein precipitation. To precipitate proteins, 350 μ l of serum was vortexed with 350 μ l of 4% trichloroacetic acid (TCA). After 5 minutes, the sample was centrifuged at 17,000 x g for 5 minutes. The supernatant was then concentrated using a centrifugal filter (Amicon® Ultra Centrifugal Filters 0.5 ml 10K, Merck Millipore Ltd., Tullagreen, Co. Cork, IRL) with centrifugation at 17,000 x g for 45 minutes. One drop (30 μ l) of the filtered serum was administered into the test well, followed by 4 drops (120 μ l) of buffer from the test kit. The serum sample was considered positive if a pink test line of any intensity was visible after the 20 minute incubation time.

Statistical analysis

STATA® Data Analysis and Statistical Software version 14.2 (StataCorp LLC, College Station, TX) was used for all statistical analyses. The prevalence, sensitivity, and negative predictive value of FSS, PCR-ff, PCR-sedi, POC-CCA, and POC-CAA were calculated with 95% confidence intervals (CIs). Combined results from all tests were used as a composite reference gold standard, making the assumption that the specificity and positive predictive value of each test is 100%. Differences in sensitivity between each test pair was determined using the Exact binomial test. The agreement between each test pair was

evaluated by Kappa (κ) statistics: $\kappa < 0$: no agreement; $\kappa = 0-0.20$: slight agreement; $\kappa = 0.21-0.40$: fair agreement; $\kappa = 0.41-0.60$: moderate agreement; $\kappa = 0.61-0.80$: substantial agreement; $\kappa = 0.81-1.00$: almost perfect agreement.

RESULTS

A total of 69 dogs were enrolled in the study. Age was reported for 68 dogs with a range of 7 months to 14 years and a median of 7 years. American Kennel Club groups represented were sporting (n=24); herding (n=12); terrier (n=8); working (n=4); toy (n=4); hound (n=1); and nonsporting (n=1). Fifteen dogs were crossbreeds. Dogs in the study were currently living in Texas (n=60), Ohio (n=5), North Carolina (n=2), Florida (n=1), and Maryland (n=1).

Eleven dogs were enrolled in the study because they were currently diagnosed with *H. americana* either by liver biopsy (n=3); intestinal biopsy (n=2); fecal PCR by the GI Laboratory (n=5); or by direct fecal smear (n=1). Forty-one dogs had clinical signs consistent with *H. americana* infection and had not been diagnosed at the time of the study. Seventeen enrolled dogs were cohort dogs: dogs sharing the same environment with a dog that was diagnosed with *H. americana* or with a dog that was exhibiting clinical signs consistent with *H. americana*.

Of the 69 dogs, 24 (34.8%) dogs were positive on at least one diagnostic test. Age of positive dogs ranged from 1 to 12 years with a median of 6 years. Breeds of positive dogs were sporting (n=10); terrier (n=3); herding (n=3); toy (n=2); non sporting (n=1), working (n=1), and crossbred (n=4). Positive dogs were living in Brazoria county, TX (n=5); Travis county, TX (n=4); Wichita county, TX (n=4); Denton county, TX (n=1); Calhoun county, TX

(n=1); Brazos county, TX (n=1); Belton county, TX (n=1), Brown county, TX (n=1), Alachua county, FL (n=1); Pitt county, NC (n=1); Mercer county, OH (n=3); and Montgomery county, MD (n=1). The positive dog in Maryland originally lived in North Carolina.

All dogs previously diagnosed by biopsy (n=5) were positive by at least one diagnostic test. None of the 5 dogs diagnosed by fecal PCR by the GI Laboratory were positive in this study. The dog previously diagnosed by direct fecal smear was positive in this study. Twelve of the 41 dogs (29.2%) with clinical signs consistent with *H. americana* and without a current diagnosis were positive in this study. Six of the 17 cohort dogs (35.3%) were positive by at least one diagnostic test method.

Test performance results are shown in Table 3.1 A. The combination of all test results is used as the reference 'gold standard'. The PCR-sedi accounted for the majority of positive tests and was more sensitive than FSS (p=0.0010) and PCR-ff (p=0.0117). The FSS and PCR-ff were equally as sensitive in detecting *H. americana* infection (p=0.6875). When the PCR-sedi is excluded from the analysis, demonstrating the use of an inferior gold standard composite, FSS sensitivity increases from 50% to 75%, and PCR-ff sensitivity increases from 58.3% to 87.5%.

Test agreements are shown in Table 3.2. The POC-CCA and POC-CAA tests had an almost perfect agreement $\kappa = 0.93$, although these immunodiagnostic methods detected the least number of positive cases (Table 3.1). Samples from each dog that were positive by a POC test were also positive by all other diagnostic tests. PCR-ff detected 4 dogs as positive that were negative by FSS, and 2 dogs that were positive by FSS were negative by the PCR-ff (Table 3.1).

Table 3.1 Diagnostic characteristics of parasitological, molecular, and immunological tests for detecting *H. americana* infection in naturally infected dogs using A. Composite ‘gold standard’ of all diagnostic tests and B. Composite ‘gold standard’ excluding PCR of the fecal sediment (PCR-sedi). PCR-sedi is not a routine diagnostic method used for *H. americana*, but demonstrates a higher sensitivity compared to other methods. Not using this method in the gold standard composite would result erroneous higher estimates of sensitivity for the other test methods. PPV = positive predictive value; NPV = negative predictive value

A.

Test method	Positive n (%)	Sensitivity % (95% CI)	NPV % (95% CI)
Fecal saline sedimentation	12 (17.4)	50 (29.1-70.9)	78.9 (66.1-88.6)
PCR - fresh feces	14 (20.3)	58.3 (36.6-77.9)	81.8 (69.1-90.9)
PCR - fecal sediment	23 (33.3)	95.8 (78.9-99.9)	97.8 (88.5-99.9)
POC-CCA	7 (10.1)	29.2 (12.6-51.1)	72.6 (59.8-83.1)
POC-CAA	8 (11.6)	33.3 (15.6-55.3)	73.8 (60.9-84.2)

B.

Test method	Positive n (%)	Sensitivity % (95% CI)	NPV % (95% CI)
Fecal saline sedimentation	12 (17.4)	75 (47.6-92.7)	93.5 (83-98.1)
PCR - fresh feces	14 (20.3)	87.5 (61.7-98.4)	96.4 (87.5-99.6)
POC-CCA	7 (10.1)	43.8 (19.8-70.1)	85.5 (74.2-93.1)
POC-CAA	8 (11.6)	50 (24.7-75.3)	86.9 (75.8-94.2)

Table 3.2 Comparisons of positive and negative results between each diagnostic test pair. FSS = fecal saline sedimentation test; PCR-ff = PCR-fresh feces; PCR-sedi = PCR-fecal sediment; POC-CCA = point of care circulating cathodic antigen test (urine); POC-CAA = point of care circulating anodic antigen test (serum); κ = kappa; CI = confidence interval.

PCR-ff				POC-CCA			
FSS	Pos	Neg	κ (95% CI)	PCR-ff	Pos	Neg	κ (95% CI)
Pos	10	2	0.72 (0.60-0.84)	Pos	7	7	0.61 (0.50-0.73)
Neg	4	53		Neg	0	55	

PCR-sedi				POC-CAA			
FSS	Pos	Neg	κ (95% CI)	PCR-ff	Pos	Neg	κ (95% CI)
Pos	12	0	0.60 (0.49-0.70)	Pos	8	6	0.68 (0.57-0.79)
Neg	11	46		Neg	0	55	

POC-CCA				POC-CCA			
FSS	Pos	Neg	κ (95% CI)	PCR-sedi	Pos	Neg	κ (95% CI)
Pos	7	5	0.70 (0.58-0.81)	Pos	7	16	0.37 (0.28-0.46)
Neg	0	57		Neg	0	46	

POC-CAA				POC-CAA			
FSS	Pos	Neg	κ (95% CI)	PCR-sedi	Pos	Neg	κ (95% CI)
Pos	8	4	0.77 (0.65-0.88)	Pos	8	15	0.42 (0.32-0.51)
Neg	0	57		Neg	0	51	

PCR-sedi				POC-CAA			
PCR-ff	Pos	Neg	κ (95% CI)	POC-CCA	Pos	Neg	κ (95% CI)
Pos	13	1	0.60 (0.49-0.72)	Pos	7	0	0.93 (0.81-1)
Neg	10	45		Neg	1	61	

Total egg counts ranged from 1 to 1,416 (Table 3.3). Only one egg was detected in 4 dogs, and half of those dogs were POC-CCA and POC-CAA positive. All dogs with greater than 60 eggs were positive by POC-CCA and POC-CAA except for one dog (Dog 11) that had undergone intravenous fluid therapy before a urine sample was collected. Antigen was detected only in this dog's serum.

FSS additionally detected *Ancylostoma caninum* in one dog and *Dipylidium caninum* in another dog. Both of those dogs were negative by POC-CCA and POC-CAA.

Table 3.3 Total egg counts of positive fecal saline sedimentation tests with accompanying molecular and immunodiagnostic test results. PCR-sedi = PCR-fecal sediment; PCR-ff = PCR-fresh feces; POC-CCA = point of care circulating cathodic antigen (urine); POC-CAA = point of care circulating anodic antigen (serum) *Dog treated with intravenous fluid therapy before urine collection.

	Total egg count	PCR-ff	PCR-sedi	POC-CCA	POC-CAA
Dog 1	7	+	+	-	-
Dog 2	1	+	+	+	+
Dog 3	1	+	+	+	+
Dog 4	2	-	+	-	-
Dog 5	1,416	+	+	+	+
Dog 6	309	+	+	+	+
Dog 7	60	+	+	+	+
Dog 8	350	+	+	+	+
Dog 9	1	+	+	-	-
Dog 10	1	-	+	-	-
*Dog 11	661	+	+	-	+
Dog 12	184	+	+	+	+

DISCUSSION

We conclude that *H. americana* diagnostic test concordance is suboptimal in many cases, verifying that this parasite can be challenging to diagnose accurately. If only one diagnostic test was performed on each dog, there could have been several dogs with false negative diagnoses. Because no individual test identified all cases, none of these tests could be considered single gold standard tests in future studies; however, the PCR-sedi had the highest sensitivity, detecting 23 of the 24 combined positive cases.

Had the PCR-sedi assay not been used in this study, the FSS and the PCR-ff tests would have appeared to have a higher sensitivity (Table 3.1). When comparing the performance of the two molecular tests using fresh fecal samples (PCR-ff) and the concentrated fecal sediment (PCR-sedi), the PCR-sedi was significantly more sensitive than the PCR-ff. We attribute this improved test performance to a combination of sample concentration and potential reduction of PCR inhibitors prior to DNA extraction. Concentrating a large fecal sample (10 grams) through the sedimentation and centrifugation process increases the likelihood of parasite egg or parasite DNA presence in the sample compared to an equivalent weight of fresh feces. During the fecal sedimentation process, the feces are washed several times, likely decreasing the presence of PCR inhibitors in the feces prior to DNA extraction. Commercial fecal DNA extraction kits are designed to remove these inhibitors; however, they may not be completely removed. A study comparing 4 commercial DNA extraction kits for the detection of *Tritrichomonas foetus* using spiked cat feces showed variability in PCR test results among kits and between individual fecal samples using the same kit, suggesting that inhibitors still remained in some fecal samples and that the presence of inhibitors varied between individual samples (Stauffer et al., 2008).

Comparing PCR test performance using different DNA extraction kits on known numbers of parasite eggs in fecal samples could determine the impact of fecal inhibitors on the molecular diagnosis of *H. americana* in dogs. Internal controls could also be used to rule out inhibition as the cause of negative PCR tests (Hoorfar et al., 2004). Although performing washes on a fecal sediment increases sample processing time, it is a simple step that can be taken to increase the sensitivity of this fecal PCR and should be considered as a pre-fecal DNA extraction step when feasible.

Because the POC-CCA and POC-CAA tests agreed in most dogs, and because the antigen positive dogs were also positive by all other testing methods (Table 3.3), we can conclude that CCA and CAA are present and detectable in dogs infected with *H. americana*, similar to results in humans and other animals infected with other schistosome species. Because the POC-CCA and POC-CAA tests detected the lowest number of positive dogs, they cannot currently be used as reliable testing methods for diagnosing infection in dogs. Because all 8 serum antigen positive dogs and all 7 urine antigen positive dogs were also positive by the other test methods, we speculate that the POC-CCA and POC-CAA tests have a high threshold of detection for *H. americana* antigen levels. Based on clinical histories provided by referring practitioners, the antigen positive dogs exhibited severe clinical signs including marked weight loss, diarrhea, vomiting, and/or hypercalcemia. Three of these dogs showed abdominal ultrasonographic changes consistent with egg-induced granulomas (Rodriguez et al., 2014). Interestingly, 3 of the 4 egg positive/antigen negative dogs exhibited no abnormal clinical signs: Dog 1 underwent a liver biopsy during a gastric foreign body removal due to gross pathology of the liver observed during surgery. Dog 2 had a persistent elevated alanine aminotransferase (ALT) without clinical signs and

underwent a liver biopsy to assess the underlying disease process. Dog 10 was in the same household as a severely affected dog (Dog 8, antigen positive) and was asymptomatic. The fourth egg positive/antigen negative dog, Dog 9, was also in the same household as Dog 8 and 10 and had experienced intermittent diarrhea for 2 months but was asymptomatic at the time of sampling. These correlations between clinical presentation and antigen test results further supports our theory that the POC tests can only detect dogs with high levels of worm burdens. It is possible that the majority of the infected dogs did not carry high adult worm burdens, and thereby did not have adequate levels of circulating or urinary antigen to be detected by these methods. A more recently developed immunodiagnostic test detects CAA on concentrated samples using monoclonal antibodies tagged with an up-converting phosphor label that is analyzed by an infrared reader (UCP-CAA) (van Dam et al., 2013). This test has shown promise in detecting low-intensity schistosome infections in humans and should be further explored as a more sensitive test for use in dogs with *H. americana*.

Currently fee-for-service laboratory diagnostic tests for *H. americana* are fecal saline sedimentation and fecal PCR (PCR-ff). In this study, we did not demonstrate a statistical difference in the sensitivities of these two tests (Table 3.1). It is difficult to directly compare our methods to the methods used in fee-for-service laboratories. Five of the 12 dogs in this study had 1-2 total eggs counted from examining 10 aliquots of feces, which takes approximately 20 minutes to perform. If laboratory personnel examine fewer aliquots of sediment, this will decrease the sensitivity of this test compared to the method in this study. Additionally, we performed conventional PCR targeting a segment of the 18S rDNA gene. Real-time PCR methods and/or different gene targets may increase the sensitivity of PCR-ff compared to our method.

The low sensitivity of the fecal saline sedimentation test and fecal PCR of fresh feces, make it difficult for the veterinary clinician to confidently rule out *H. americana* infection in negative patients. Performing these tests on multiple fecal samples may increase the overall sensitivity. Data from other schistosome parasites show that parasitological test sensitivity increases when fecal samples from more than one day are tested (Carabin et al., 2005; Lamberton et al., 2014). The chronicity of infection could also affect diagnostic success. In a previous experimental infection study, eggs were not detected in 2 out of 6 dogs on some days when monitoring egg output (Malek, 1969). In the 6 previously described experimentally infected dogs, egg output decreased over time (Malek, 1969). This diminishing egg output has also been observed with other schistosome species and has been attributed to adult worm attrition and/or decreased egg production by female worms over time (Agnew et al., 1993; Lier et al., 2008).

Our goal in this study was to compare currently available diagnostic techniques for *H. americana* in dogs and to examine the ability to detect worm antigens in urine and serum using tests developed for *S. mansoni* in humans. Until better testing techniques or methods are developed and available, the veterinarian should consider using a combination of diagnostic tests, submitting multiple samples, and using additional supportive diagnostic tests when an *H. americana* infection is included in a differential diagnostic list. These additional test abnormalities could include abdominal ultrasonographic evidence of granulomatous disease, hematological and biochemical panel abnormalities (elevated ALT, elevated calcium with or without azotemia, hyperglobulinemia, anemia, etc.), and endoscopic or laparoscopic biopsies (Fabrick et al., 2010; Hanzlicek et al., 2011; Rodriguez et al., 2014).

The ability to detect circulating cathodic and anodic antigens in some of these dogs is promising and immunodiagnostic antigen detection test options should be further investigated as a valid method to detect active *H. americana* infections in dogs.

CHAPTER IV
UTILIZING NEXT GENERATION SEQUENCING TO DISCOVER HIGHLY
REPETITIVE DNA SEQUENCE TARGETS FOR REAL TIME PCR DIAGNOSIS OF
HETEROBILHARZIA AMERICANA

INTRODUCTION

In the previous chapter parasitological, immunodiagnostic, and molecular tests were compared for the diagnosis of *H. americana* in naturally infected dogs. The PCR-sedi (PCR performed on DNA extracted from the pelleted fecal sediment) detected 23 of 24 of the combined positive tests. The PCR-ff (PCR performed on fresh feces) detected 14 of 24 combined positive results. It detected four more positive tests than the fecal saline sedimentation test (FSS) but also failed to detect two FSS positive samples. The target for the conventional PCR was a 487 bp region of the 18S ribosomal RNA gene.

Traditionally, common targets of PCR amplification in parasitic diagnostic tests include ribosomal RNA genes (rRNA) due to the multiple copies that are arranged in tandem repeats, and mitochondrial genes due to the multiple mitochondria in most eukaryotic cells (Alberts et al., 2008; Gatehouse and Malone, 1998). However, in portions of non-coding DNA regions, nematodes can contain repetitive DNA elements exceeding 1,000 copies per haploid genome (*C. elegans* Sequencing Consortium, 1998; Ghedin et al., 2004). In addition to being highly abundant, these regions are also highly divergent and unique when compared to highly conserved rRNA gene and mitochondrial DNA sequences. These attributes of these non-coding DNA regions make them good candidates for highly specific and sensitive PCR assays.

The historical approach for determining these repeat regions was a laborious process involving genomic DNA restriction endonuclease digestion, gel electrophoresis, and Sanger sequencing (Hamburger et al., 1991; Lier et al., 2006). Recently, next generation sequencing (NGS) and bioinformatics have expedited the process of determining repetitive DNA elements (Novak et al., 2010; Novák et al., 2013; Roset et al., 2003; Subirana and Messeguer, 2013; Treangen and Salzberg, 2012). Novak et al. (2010) developed an approach that compares similarities between unassembled DNA sequences from NGS. From these similarities, a graph is constructed that reveals clusters of common DNA reads. Tools were developed using this approach and adapted to use on the online data analysis platform, Galaxy (Goecks et al., 2010; Novák et al., 2013).

Pilotte et al. (2016) used this approach to determine repetitive elements in several species of soil transmitted helminths in humans. Primers for repetitive non-coding sequences were designed for *Necator americanus*, *Ancylostoma duodenale*, *Trichuris trichiura*, and *Strongyloides stercoralis*. When comparing these real-time PCR assays with existing assays using ITS1 and ITS2 primer targets, more positive cases were detected for *N. americanus* by the new assay. The new assay also distinguished between *A. duodenale* and *A. ceylanicum* infections and *T. trichiura* and *T. vulpis* infections, showing excellent specificity over traditional DNA targets. These results support the idea that these highly repetitive, non-coding DNA sequences are good targets for developing highly sensitive and specific PCR diagnostic tests.

In this study, we aim to determine the most abundant DNA sequences in the *H. americana* genome and to use these regions as targets for real-time PCR diagnostic test development to improve molecular diagnostic test performance for this parasite.

MATERIALS AND METHODS

Isolation of parasite genomic DNA

One and a half male worms and 1 female adult worm that were previously collected from the mesentery of raccoon carcasses and stored in 70% ethanol underwent DNA extraction (XIT™ Genomic DNA Isolation Kit, G-Biosciences®, St. Louis, MO) using the ‘Genomic DNA from Tissue’ protocol.

Next generation sequencing of genomic DNA

Genomic DNA was submitted to the Genomics and Bioinformatics Service for library preparation and NGS (Texas A&M University, College Station, TX) using the Illumina TruSeq DNA Sample Preparation Kit (Illumina, San Diego, CA). The library was sequenced on the MiSeq platform (Illumina) using the MiSeq Reagent Kit v3 (Illumina) and the paired-ended read approach to obtain 300 base read lengths.

Repeat analysis

Raw sequencing reads were uploaded to the Galaxy-based RepeatExplorer web server (Novák et al., 2013). Reads were pre-processed to allow for the identification of high-copy repeat DNA sequences. In short, the FASTQ Groomer tool was executed in order to filter the reads by quality to remove low quality reads. The FASTQ to FASTA converter was run in order to convert the sequences to FASTA format to use in the repeat analysis. The FASTA interlacer tool was used to arrange the paired sequences consecutively. The clustering tool was then used to perform an ‘all to all’ comparison of sequences in the genome. Graphical layout results were visually analyzed for clusters containing reads highly similar to each other as depicted by nodes connected to one another by lines (edges). The closer in proximity the nodes to each other, the higher the similarity of reads within that cluster.

Output files of each candidate cluster were evaluated. Each output file contained consensus DNA sequences paired with numerical values corresponding to the frequency that the nucleotide occurred at that location within the reads in the cluster. Candidate repeat sequences were selected and evaluated for specificity using the online Nucleotide Blast tool (blast.ncbi.nlm.nih.gov/Blast.cgi; National Center for Biotechnology Information, Bethesda, MD).

Primer and probe design, testing, and optimization

Primer and probe design

Using selected candidate repeat sequences that met specificity requirements, candidate primer and probe pairings were designed using the PrimerQuest online tool (Integrated DNA Technologies, Coralville, IA). Primer-BLAST software (blast.ncbi.nlm.nih.gov/Blast.cgi) was used to examine the species-specificity of each primer pair.

Assay specificity

Specificity of each of the primer/probe sets was evaluated by testing template DNA from human and canine parasites, known *H. americana* negative dog feces, *Trichobilharzia querquedulae*, and *E. coli* in triplicates. *H. americana* adult worm genomic DNA (1 ng/ μ l) was also included as a positive control. Reactions were performed using the StepOne Plus Real-Time PCR System (Life Technologies). Reactions were performed in 7 μ l volumes with 2 μ l template DNA, 3.5 μ l 2X TaqMan Fast Universal PCR Master Mix (Life Technologies, Carlsbad, CA), 125 nmol probe labeled with a 6FAM fluorophore at the 5' end, and double quenched using the internal quencher ZEN and a 3IABkFQ at the 3' end (Integrated DNA Technologies, Coralville, IA), 250 nM forward, and 250 nM reverse

primers. Cycling conditions were an initial 2 minute incubation step at 50°C, a 10 minute incubation at 95°C, followed by 40 cycles of 95°C for 15 seconds for denaturation and 1 minute at 59°C for annealing and extension.

Primer/probe set selection and optimization

The two primer sets resulting in the lowest Ct values for *H. americana* were selected for primer optimization. Each primer set was tested in all possible combinations of concentrations (62.5 nM, 125 nM, 250 nM, 500 nM, and 1000 nM) using 1 ng/μl *H. americana* worm genomic DNA as a template in triplicates.

Assay sensitivity

Test detection limit of the final primer/probe set with the optimum primer concentrations was determined by testing serial 10 fold dilutions of *H. americana* 1 ng/μl DNA stock concentrations.

Testing of canine samples

DNA frozen and stored at -20°C from previously analyzed canine fecal samples collected in the Chapter III study were tested with this assay. These samples were tested at the Molecular Genomics Shared Workspace of the Texas A&M Institute for Genome Sciences and Society using the CFX96 Touch™ Real-Time PCR Detection System (Bio-Rad, Hercules, CA) scaled up to a 25 μl assay volume, keeping the template DNA volume standard at 2 μl. Samples were tested in duplicates. Samples were considered positive if DNA amplification reached the threshold by cycle 40 (Ct ≤40).

Statistical analysis

STATA® Data Analysis and Statistical Software version 14.2 (StataCorp LLC, College Station, TX) was used for all statistical analyses. Pairwise comparisons were made

between results of the real-time PCR assay and previously analyzed fecal saline sedimentation and conventional PCR results from a collection of canine fecal samples. The agreement between each test pair was evaluated by Kappa (κ) statistics: $\kappa < 0$: no agreement; $\kappa = 0-0.20$: slight agreement; $\kappa = 0.21-0.40$: fair agreement; $\kappa = 0.41-0.60$: moderate agreement; $\kappa = 0.61-0.80$: substantial agreement; $\kappa = 0.81-1.00$: almost perfect agreement.

RESULTS

Repeat analysis

Candidate repeat sequences were selected from six clusters (Figs. 4.1 and 4.2). BLAST analysis of candidate repeat sequences did not fully or partially match to a characterized gene, including any ribosomal or mitochondrial sequences. Partial identity to several scaffold sequences of *Trichobilharzia regent*, a nasal schistosome of birds in Europe, occurred with all sequence cluster candidates ranging from a query cover of 90% with 82% identity (GenBank accession number LL018337.1), to a query cover of 100% with 84% identity (GenBank accession number LL065184.1).




Figure 4.1 Graphical layout output of RepeatAnalysis. Each node represents a DNA read and the line (edge) connecting one node to the other represents a similarity. The shorter the distance between nodes, the higher the similarity. The top row contains DNA reads that are highly similar (4 of 6 clusters chosen) compared to the bottom row of less similar reads.



Figure 4.2 Output file of a cluster of similar DNA reads. Numerical values represent the number of instances that a nucleotide occurs at that position. Highlighted values correspond to the highlighted DNA sequence. DNA sequence containing the highest number of nucleotide occurrences is targeted for further analysis.

Primer and probe design, testing, and optimization

Primer and probe design

Using the PrimerQuest tool on candidate repeat sequences, four specific candidate primer/probe sets were selected for testing (Table 4.1).

Table 4.1 Candidate primer/probe sequences targeting high copy sequence targets.

Primer/Probe set	Sequence
Set 1 F	5'-GACGCGCCAAGTCTCTG-3'
Set 1 R	5'-ATGTGGAACAAGATACGGATT-3'
Set 1 Probe	5'-/56-FAM/AGAGCACTG/ZEN/ACTTGACGTTGGTGT/3IABkFQ/-3'
Set 1 Amplicon length	75 bp
Set 2 F	5'-CCAGTGTTTCGTAGAAAGTGTCT-3'
Set 2 R	5'-GCTCAACGACAAGAGGAACT-3'
Set 2 Probe	5'-/56-FAM/TGTCTTTGC/ZEN/GTGCACTCTTCTTCACT/3IABkFQ/-3'
Set 2 Amplicon length	100 bp
Set 3 F	5'-CTTTGCGTGCACTCTTCTTC-3'
Set 3 R	5'-GAAGATAAACCAGTGCAAGGATG-3'
Set 3 Probe	5'-/56-FAM/TGTGCTCAG/ZEN/TTCCTCTTGTCGTTGAG/3IABkFQ/-3'
Set 3 Amplicon length	95 bp
Set 4 F	5'-GCCTAATGTCACATAAACTTGAAGA-3'
Set 4 R	5'-TGTCTTCTCTATATTCACCTGAAGTC-3'
Set 4 Probe	5'-/56-FAM/TTGACAGAA/ZEN/GAGGCAGCGAAGACG/3IABkFQ/-3'
Set 4 Amplicon length	98 bp

Assay specificity

No DNA amplification was detected when this assay was tested on DNA from *Toxocara canis*, *Ancylostoma caninum*, *A. duodenale*, *A. ceylanicum*, *Trichuris trichiura*, *Ascaris lumbricoides*, *Necator americanus*, *Dirofilaria immitis*, *Strongyloides stercoralis*, *Schistosoma mansoni*, *Trichobilharzia querquedulae*, and *E. coli*. This assay also did not amplify DNA from dog and feces from known negative *H. americana* dogs.

Primer/probe set selection and optimization

Primer/probe Sets 3 and 4 yielded the lowest Ct values for 1 ng/ μ l *H. americana* DNA using 250 nM concentration of each primer. After performing real-time PCR reactions using all possible primer combinations, primer/probe set 3: 62.5 nM forward, 250 nM reverse, yielded the lowest Ct values for *H. americana* detection.

Assay sensitivity

The optimum primer/probe set concentration detected *H. americana* DNA dilutions consistently as low as 1 fg/ μ l (Figure 4.3).

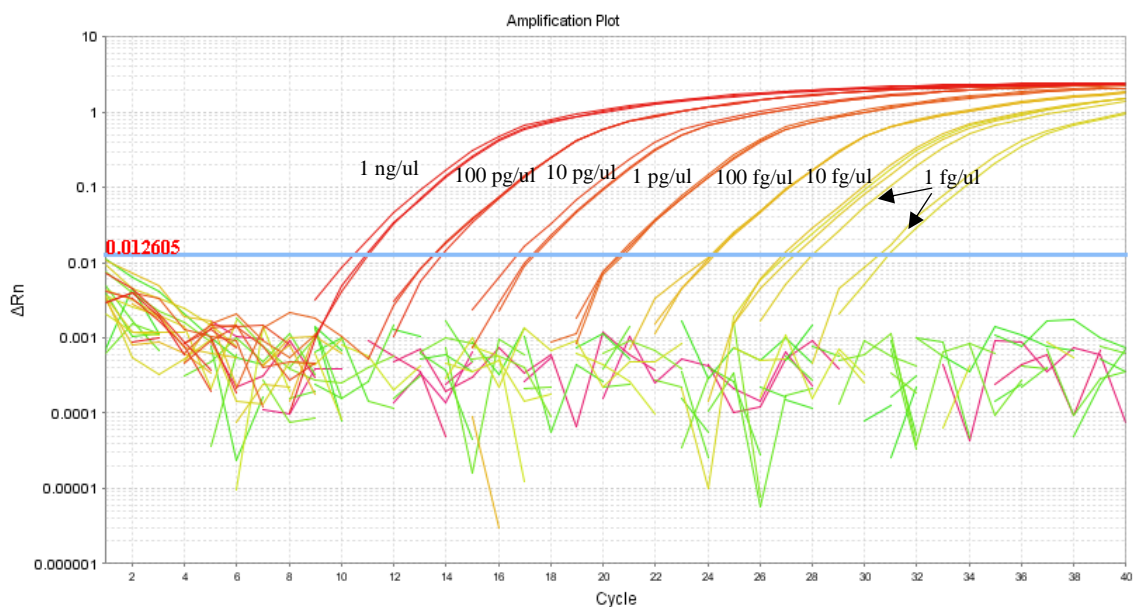


Figure 4.3 Sensitivity analysis of primer/probe Set 3. Limit of detection is 1 fg/ μ l *H. americana* genomic DNA.

Testing of canine samples

Primer/probe Set 3 at the optimum concentrations was used to screen previously collected and DNA extracted canine fresh fecal samples. Seventy-two of 74 samples previously tested in Chapter III were tested using this real-time assay. Inadequate DNA volume was available to test two samples; however, these were negative samples by all methods used in Chapter III.

Results of the new assay tested on fresh feces (real-time-PCR-ff) are compared to PCR of fresh feces (PCR-ff) in Table 4.2. The tests agreed moderately; $\kappa = 0.59$ (0.48-0.7). Real-time-PCR-ff detected 10 of the 12 PCR-ff positive samples. In addition, the real-time assay detected 9 samples as positive that were negative by PCR-ff.

Table 4.3 shows how real-time-PCR-ff and PCR-ff compare with previously collected results of fecal saline sedimentation (FSS) and PCR of the fecal sediment (PCR-sedi). The real-time-PCR-ff detected all FSS positive tests, unlike the PCR-ff which did not detect 2 of the 12 positive FSS samples. Three of the 10 false negative PCR-ff samples from the Chapter III study were detected as positive using the real-time-PCR-ff assay. Overall the PCR-ff-real-time detected 20 positive cases compared to 14 cases detected as positive by the PCR-ff.

Table 4.2 Comparison of real-time assay (Real-time-PCR-ff) with conventional PCR of fresh feces (PCR-ff). PCR-ff was performed in Chapter III.

	Real-time-PCR-ff +	Real-time-PCR-ff -	Total
PCR-ff +	12	2	14
PCR-ff -	9	49	58
Total	21	51	72

Table 4.3 Comparison of real-time assay targeting highly repetitive DNA sequence (Real-time-PCR-ff) and conventional PCR of fresh feces (PCR-ff) with fecal saline sedimentation (FSS) and conventional PCR of the fecal sediment (PCR-sedi). FSS, PCR-ff, and PCR-sedi were performed in Chapter III.

	FSS			PCR-sedi		
	+	-	κ (95% CI)	+	-	κ (95% CI)
Real-time-PCR-ff +	12	9	0.65 (0.54-0.76)	14	7	0.48 (0.36-0.59)
Real-time-PCR-ff -	0	51		9	42	
PCR-ff +	10	4	0.72 (0.60-0.84)	13	1	0.61 (0.50-0.72)
PCR-ff -	2	58		10	50	

DISCUSSION

A new molecular target for real-time PCR diagnosis of *H. americana* was identified by performing NGS and determining repetitive sequences in the genome. These sequences did not match to ribosomal or mitochondrial sequences of *H. americana*, or of any other schistosome parasite. These analyses lead us to conclude that these are most likely non-gene coding, highly repetitive sequences in the *H. americana* genome.

Although in the BLAST analysis, some partial identity was present to a scaffold sequence of *T. regenti*, a European nasal avian schistosome, the high specificity of this target was demonstrated by the lack of amplification of DNA from closely related *Schistosoma mansoni* and *Trichobilharzia querquedulae* parasites. In addition, dogs in North America are

not infected with any other schistosome parasite, further lowering the possibility of cross reactivity of this assay with related parasites using canine samples.

Using this repeat sequence as a target improved detection of parasite in canine fecal samples as demonstrated by the real-time PCR assay detecting all parasitologically positive samples as PCR-positive, compared to the ribosomal target conventional PCR assay not identifying 2 of these 12 fecal saline sedimentation positive dogs (Table 4.3). Overall, the real-time-PCR-ff detected 9 samples as positive that were negative by PCR-ff (Table 4.2). Although three of these positive samples agree with fecal sedimentation and PCR-sedi results, there were 6 samples that were positive only by PCR-ff-real-time. The Ct values for these 6 samples ranged from 33 to 39. Because of a lack of a true gold standard, it is difficult to definitively determine these as true positive samples. If *H. americana* DNA was truly present in this sample, the DNA was present in such low concentrations that amplification above threshold did not occur until the last few cycles. Late off-target amplification and potential DNA contamination could be a cause of these positive results as well. Further work to determine Ct cut-off values could result in fewer of these samples being considered positive.

The increase in positive samples detected by the new assay cannot be completely attributed to the highly repetitive DNA target used. The real-time PCR method compared to conventional, may alone contribute to this apparent increase in test sensitivity. To truly compare the different DNA targets, a validated real-time PCR assay that targets a mitochondrial or rRNA gene sequence should be used as a direct comparison; however, there are no published studies on a validated assay of this type.

The main limitation of this study was the difference in points in time that the PCR assays were performed. The test results for two PCR-ff positive/real-time-PCR-ff negative samples were unexpected. When retesting these samples with the conventional PCR from Chapter III, after storage, both samples were negative. Because these samples were stored at -20°C for over 2 years, it is possible that the DNA degraded, making *H. americana* DNA no longer detectable in both PCR assays. Further comparison of these discrepant samples should be repeated using the two assays on freshly extracted samples.

This highly repetitive non-gene coding DNA target was discovered using a user-friendly online bioinformatics software. The apparent increase in sensitivity and the high specificity of this real-time PCR assay make this a promising new molecular test for the diagnosis of *H. americana*. This method of determining these highly abundant and specific DNA sequences can be used in developing other molecular diagnostic tests for a number of parasites of veterinary importance in domestic animal hosts.

CHAPTER V

SUMMARY AND CONCLUSIONS

Heterobilharzia americana is an under recognized parasite of dogs that can lead to death if not diagnosed and treated in a timely matter. Awareness by the veterinarian is key to reaching a non-invasive diagnosis because routine parasitological diagnostic tests do not detect *H. americana*. In addition, diagnostic test performance data for this parasite is lacking. This dissertation research aimed to fill in the gaps of knowledge for this parasite.

This study (Chapter II) demonstrates a lack of knowledge of the parasite in dogs that died with the infection. Compiling clinical records from multiple sources, data from 238 canine cases of *H. americana* infection were documented. In 20 dogs whose deaths were attributed to *H. americana* infection, only 1 dog was diagnosed ante mortem. In addition, in only two dogs did the veterinarian suspect *H. americana* infection.

In the literature, the majority of case reports described severely affected cases that were diagnosed primarily by biopsy or necropsy, with weight loss and anorexia/hyporexia as the most common clinical signs. This study shows that the majority of dogs diagnosed with *H. americana* have been diagnosed by fecal saline sedimentation and that diarrhea is the most common clinical sign. According to these results, diarrhea is likely the first clinical signs exhibited by infected dogs. Based on these data, *H. americana* should be included in a differential diagnostic list for dogs in endemic areas exhibiting diarrhea.

Over one third of dogs necropsied (11 of 31) had parasite eggs in the pancreas with associated inflammation and fibrosis, based on histopathological results. Pancreatic inflammation and fibrosis were present. It is likely that dogs with pancreatic inflammation

secondary to *H. americana* exhibit clinical signs similar to dogs with pancreatitis due to other causes. The condition of pancreatitis in dogs in the U.S. is often considered a sterile pancreatitis with causative factors attributed to genetics and diet. Because *H. americana* diagnostics and deworming are not part of the standard protocol for managing patients with pancreatitis, it is important for veterinarians to consider *H. americana* as a causative agent in dogs presenting with pancreatitis in endemic areas.

Over one quarter of dogs necropsied had fibrosis present in the intestine, liver, or pancreas based on histopathological results. Potential clinical sequelae of fibrosis in these organs include intestinal malabsorptive disorders, hepatic insufficiency, portal hypertension, and exocrine pancreatic insufficiency. Early diagnosis and treatment is key to preventing these pathologic changes.

Four necropsied dogs had concurrent glomerulonephritis and *H. americana* infection. As demonstrated by a previous case report (Ruth, 2010), *H. americana* can cause glomerulonephritis and a protein losing nephropathy. Along with other infectious etiologies, *H. americana* should be considered as a potential cause of glomerulonephritis in dogs.

The second study (Chapter III) provided a comprehensive comparison of parasitological, immunologic, and molecular diagnostic test data. Conventional PCR on fresh feces performed with equal sensitivity to the fecal saline sedimentation; however, both tests lacked sensitivity when compared to PCR of the fecal sediment. Concentrating fecal sediment using a washing and centrifugation protocol before DNA extraction resulted in a statistically significant increase in assay sensitivity. Pre-processing of the fecal sample before DNA extraction and PCR is a simple additional step to take to increase sensitivity of PCR assays and should be evaluated for use in diagnostic labs offering *H. americana* PCR.

This study also determined that circulating cathodic and anodic parasite antigens are detectable in some dogs infected with *H. americana* using point of care antigen detection tests designed to detect *S. mansoni* antigen in human urine. All antigen positive dogs were positive by all other diagnostic testing methods and exhibited severe clinical signs. It is likely that these tests can only detect dogs with a high burden of adult worm parasite infection. Unfortunately, in its current form this test is not sensitive enough for use in dogs as a rapid point-of-care assay, but further work to develop more sensitive tests detecting these antigens is worthwhile.

In the final study (Chapter IV), non-gene coding, highly abundant DNA in the *H. americana* genome was discovered through an online bioinformatics tool that uses an “all to all” DNA sequence comparison approach that clusters highly similar DNA sequences generated from NGS. When targeting these DNA sequences in a probe-based real-time PCR assay, additional dogs were diagnosed as positive compared to conventional PCR with a ribosomal RNA gene target. This PCR target was also highly specific demonstrated by the lack of amplification of DNA from closely related schistosome parasites. This assay shows promise and will be further evaluated as a clinically useful, rapid, sensitive fecal diagnostic test.

H. americana will continue to be a problem for dogs in the southeastern United States. In addition, evidence of an autochthonous case in Indiana (Rodriguez et al., 2016) supports the concept that this parasite is more geographically widespread than originally reported. Changes in climate and continued human encroachment on wildlife habitats are factors that could contribute to continued expansion and increased exposure of dogs to this parasite. Continued education about this parasite to veterinarians is crucial to minimize

canine illness and deaths related to this parasite. Sensitive and reliable diagnostic tests will be necessary to accurately diagnose dogs and to determine clearance of infection after treatment. Novel methodologies of diagnosing *H. americana* in dogs should continue to be explored.

REFERENCES

- Abdeen, H.H., Attallah, A.F., El-Mohamady, H.I., Harrison, R.A., Mansour, M.M., 1998. *Schistosoma mansoni*: the circulating cathodic antigen forms an abundant product of 41/42 kDa in the urine of infected patients. *Exp. Parasitol.* 90, 286-289.
- Agnew, A.M., Murare, H.M., Doenhoff, M.J., 1993. Immune attrition of adult schistosomes. *Parasite Immunol.* 15, 261-271.
- Alarcón de Noya, B., Colmenares, C., Lanz, H., Caracciolo, M.A., Losada, S., Noya, O., 2000. *Schistosoma mansoni*: Immunodiagnosis is improved by sodium metaperiodate which reduces cross-reactivity due to glycosylated epitopes of soluble egg antigen. *Exp. Parasitol.* 95, 106-112.
- Alberts, B., Johnson, A., Lewis, J., Raff, M., Roberts, K., Walter, P (Eds.), 2008. *Molecular Biology of the Cell*, 5th ed. Garland Science, New York City, 1268 pp.
- Allam, A.F., Farag, H.F., Zaki, A., Kader, O.A., Abdul-Ghani, R., Shehab, A.Y., 2015. Detection of low-intensity *Schistosoma mansoni* infection by Percoll sedimentation and real-time PCR techniques in a low-endemicity Egyptian setting. *Trop. Med. Int. Health* 20, 658-664.
- Allam, A.F., Kader, O., Zaki, A., Shehab, A.Y., Farag, H.F., 2009. Assessing the marginal error in diagnosis and cure of *Schistosoma mansoni* in areas of low endemicity using Percoll and PCR techniques. *Trop. Med. Int. Health* 14, 316-321.
- Andrade, Z., 1987a. Pathology of human schistosomiasis. *Mem. Inst. Oswaldo Cruz* 82, 17-23.

- Andrade, Z.A., 1987b. Pathogenesis of pipe-stem fibrosis of the liver (experimental observation on murine schistosomiasis). Mem. Inst. Oswaldo Cruz 82, 325-334.
- Andrade, Z.A., 2009. Schistosomiasis and liver fibrosis. Parasite Immunol. 31, 656-663.
- Andrade, Z.A., Andrade, S.G., Sadigursky, M., 1971. Renal changes in patients with hepatosplenic schistosomiasis. Am. J. Trop. Med. Hyg. 20, 77-83.
- Andrade, Z.A., Van Marck, E., 1984. Schistosomal glomerular disease (a review). Mem. Inst. Oswaldo Cruz 79, 499-506.
- Ayele, B., Erko, B., Legesse, M., Hailu, A., Medhin, G., 2008. Evaluation of circulating cathodic antigen (CCA) strip for diagnosis of urinary schistosomiasis in Hassoba school children, Afar, Ethiopia. Parasite 15, 69-75.
- Barda, B.D., Rinaldi, L., Ianniello, D., Zepherine, H., Salvo, F., Tsetan, S., Cringoli, G., Clementi, M., Albonico, M., 2013. Mini-FLOTAC, an innovative direct diagnostic technique for intestinal parasitic infections: experience from the field. PLoS Negl. Trop. Dis. 7, e2344.
- Bartsch, R.C., Ward, B.C., 1976. Visceral lesions in racoons naturally infected with *Heterobilharzia americana*. Vet. Pathol. 13, 241-249.
- Berberian, D.A., Paquin, H.O., Jr., Fantauzzi, A., 1953. Longevity of *Schistosoma hematobium* and *Schistosoma mansoni*: observations based on a case. J. Parasitol. 39, 517-519.
- Berry, A., Moné, H., Iriart, X., Mouahid, G., Aboo, O., Boissier, J., Fillaux, J., Cassaing, S., Debusson, C., Valentin, A., Mitta, G., Théron, A., Magnaval, J.F., 2014. Schistosomiasis haematobium, Corsica, France. Emerg. Infect. Dis. 20, 1595-1597.

- Bishop, M.A., Suchodolski, J.S., Steiner, J.M., 2008. Development of a PCR test for the detection of *Heterobilharzia americana* DNA in dog feces. *J. Vet. Intern. Med.* 22, 804-805.
- Borel, E., Etard, J.F., Addo, A., Diakite, M., 1999. Comparison of a digestion-sedimentation technique with the Kato-Katz technique in the detection and quantification of *S. mansoni* eggs in light to moderate infections. *Parasite* 6, 175-178.
- Buergelt, C.D., Greiner, E.C., 1995. Fibrosing granulomas in the equine liver and peritoneum: a retrospective morphologic study. *J. Vet. Diagn. Invest.* 7, 102-107.
- Byrd, E.E., Prestwood, A.K., Maples, W.P., 1967. A new host and two new locality records for the blood fluke, *Heterobilharzia americana* Price, 1929. *J. Parasitol.* 53, 1115-1116.
- C. elegans* Sequencing Consortium, 1998. Genome sequence of the nematode *C. elegans*: a platform for investigating biology. *Science* 282, 2012-2018.
- Carabin, H., Balolong, E., Joseph, L., McGarvey, S.T., Johansen, M.V., Fernandez, T., Willingham, A.L., Olveda, R., 2005. Estimating sensitivity and specificity of a faecal examination method for *Schistosoma japonicum* infection in cats, dogs, water buffaloes, pigs, and rats in Western Samar and Sorsogon Provinces, The Philippines. *Int. J. Parasitol* 35, 1517-1524.
- Carlson, K.L., Chaffin, M.K., Corapi, W.V., Snowden, K.F., Schmitz, D.G., 2011. Starry sky hepatic ultrasonographic pattern in horses. *Vet. Radiol. Ultrasound* 52, 568-572.
- Carod-Artal, F.J., 2010. Neuroschistosomiasis. *Expert Rev. Anti. Infect. Ther.* 8, 1307-1318.
- Cheever, A.W., 1968. A quantitative post-mortem study of schistosomiasis mansoni in man. *Am. J. Trop. Med. Hyg.* 17, 38-64.

- Cheever, A.W., Macedonia, J.G., Mosimann, J.E., Cheever, E.A., 1994. Kinetics of egg production and egg excretion by *Schistosoma mansoni* and *S. japonicum* in mice infected with a single pair of worms. *Am. J. Trop. Med. Hyg.* 50, 281-295.
- Chitsulo, L., Engels, D., Montresor, A., Savioli, L., 2000. The global status of schistosomiasis and its control. *Acta Trop.* 77, 41-51.
- Cnops, L., Soentjens, P., Clerinx, J., Van Esbroeck, M., 2013. A *Schistosoma haematobium*-specific real-time PCR for diagnosis of urogenital schistosomiasis in serum samples of international travelers and migrants. *PLoS Negl. Trop. Dis.* 7, e2413.
- Cnops, L., Tannich, E., Polman, K., Clerinx, J., Van Esbroeck, M., 2012. *Schistosoma* real-time PCR as diagnostic tool for international travellers and migrants. *Trop. Med. Int. Health* 17, 1208-1216.
- Coelho, P.M.Z., Siqueira, L.M.V., Grenfell, R.F.Q., Almeida, N.B.F., Katz, N., Almeida, Á., Carneiro, N.F.D.F., Oliveira, E., 2016. Improvement of POC-CCA interpretation by using lyophilization of urine from patients with *Schistosoma mansoni* low worm burden: towards an elimination of doubts about the concept of trace. *PLoS Negl. Trop. Dis.* 10, e0004778.
- Colley, D.G., 1986. Immune responses during human schistosomiasis: XII. Differential responsiveness in patients with hepatosplenic disease. *Am. J. Trop. Med. Hyg.* 35, 793-802.
- Colley, D.G., Binder, S., Campbell, C., King, C.H., Tchuem Tchuente, L.A., N'Goran, E.K., Erko, B., Karanja, D.M., Kabatereine, N.B., van Lieshout, L., Rathbun, S., 2013. A five-country evaluation of a point-of-care circulating cathodic antigen urine assay for the prevalence of *Schistosoma mansoni*. *Am. J. Trop. Med. Hyg.* 88, 426-432.

- Colley, D.G., Bustinduy, A.L., Secor, W.E., King, C.H., 2014. Human schistosomiasis. *Lancet* (London, England) 383, 2253-2264.
- Corapi, W.V., Ajithdoss, D.K., Snowden, K.F., Spaulding, K.A., 2011a. Multi-organ involvement of *Heterobilharzia americana* infection in a dog presented for systemic mineralization. *J. Vet. Diagn. Invest.* 23, 826-831.
- Corapi, W.V., Birch, S.M., Carlson, K.L., Chaffin, M.K., Snowden, K.F., 2011b. *Heterobilharzia americana* infection as a cause of hepatic parasitic granulomas in a horse. *J. Am. Vet. Med. Assoc.* 239, 1117-1122.
- Corapi, W.V., Eden, K.B., Edwards, J.F., Snowden, K.F., 2015. *Heterobilharzia americana* infection and congestive heart failure in a llama (*Lama glama*). *Vet. Pathol.* 52, 562-565.
- Corapi, W.V., Snowden, K.F., Rodrigues, A., Porter, B.F., Buote, M.A., Birch, S.M., Jackson, N.D., Eden, K.B., Whitley, D.B., Mansell, J., Edwards, J.F., Hardy, J., Chaffin, M.K., 2012. Natural *Heterobilharzia americana* infection in horses in Texas. *Vet. Pathol.* 49, 552-556.
- Corstjens, P.L., de Dood, C.J., Kornelis, D., Tjon Kon Fat, E.M., Wilson, R.A., Kariuki, T.M., Nyakundi, R.K., Loverde, P.T., Abrams, W.R., Tanke, H.J., van Lieshout, L., Deelder, A.M., GJ, van Dam, G.J., 2014. Tools for diagnosis, monitoring and screening of *Schistosoma* infections utilizing lateral-flow based assays and upconverting phosphor labels. *Parasitology*, 1-15.
- Coulibaly, J.T., Knopp, S., N'Guessan, N.A., Silue, K.D., Furst, T., Lohourignon, L.K., Brou, J.K., N'Gbesso, Y.K., Vounatsou, P., N'Goran, E.K., Utzinger, J., 2011. Accuracy of

- urine circulating cathodic antigen (CCA) test for *Schistosoma mansoni* diagnosis in different settings of Cote d'Ivoire. PLoS Negl. Trop. Dis. 5, e1384.
- Coulibaly, J.T., N'Gbesso, Y.K., Knopp, S., N'Guessan, N.A., Silué, K.D., van Dam, G.J., N'Goran, E.K., Utzinger, J., 2013. Accuracy of urine circulating cathodic antigen test for the diagnosis of *Schistosoma mansoni* in preschool-aged children before and after treatment. PLoS Negl. Trop. Dis. 7, e2109.
- Crews, L.J., Sharkey, L.C., Feeney, D.A., Jessen, C.R., Ruska, T., 2007. Evaluation of total and ionized calcium status in dogs with blastomycosis: 38 cases (1997–2006). J. Am. Vet. Med. Assoc. 231, 1545-1549.
- Cringoli, G., 2006. FLOTAC, a novel apparatus for a multivalent faecal egg count technique. Parassitologia 48, 381-384.
- Cummings, R.D., Nyame, A.K., 1999. Schistosome glycoconjugates. Biochim. Biophys. Acta. 1455, 363-374.
- Custer, J.W., Pence, D.B., 1981. Ecological analyses of helminth population of wild canids from the gulf coastal prairies of Texas and Louisiana. J. Parasitol. 67, 289-307.
- da Frota, S.M., Carneiro, T.R., Queiroz, J.A., Alencar, L.M., Heukelbach, J., Bezerra, F.S., 2011. Combination of Kato-Katz faecal examinations and ELISA to improve accuracy of diagnosis of intestinal schistosomiasis in a low-endemic setting in Brazil. Acta Trop. 120 Suppl 1, S138-141.
- de Bont, J., Van Lieshout, L., Deelder, A.M., Ysebaert, M.T., Vercruyse, J., 1996a. Circulating antigen levels in serum of cattle naturally infected with *Schistosoma mattheei*. Parasitology 113 (Pt 5), 465-471.

- de Bont, J., Vercruyse, J., Massuku, M., 1996b. Variations in *Schistosoma mattheei* egg morphology and viability according to age of infection in cattle. *J. Helminthol.* 70, 265-267.
- de Clercq, D., Sacko, M., Vercruyse, J., vanden Bussche, V., Landoure, A., Diarra, A., Gryseels, B., Deelder, A., 1997. Circulating anodic and cathodic antigen in serum and urine of mixed *Schistosoma haematobium* and *S. mansoni* infections in Office du Niger, Mali. *Trop. Med. Int. Health* 2, 680-685.
- de Jonge, N., Hilberath, G.W., Krijger, F.W., Polderman, A.M., Deelder, A.M., De Caluwé, P., 1989. Circulating anodic antigen levels in serum before and after chemotherapy with praziquantel in schistosomiasis mansoni. *Trans. R. Soc. Trop. Med. Hyg* 83, 368-372.
- de Jonge, N., Krijger, P.G., Fflié, F.W., Kornelis, G., van Zeyl, Y.E., Van Dam, D., Deelder, R.J.M., Kremsner, G.J., Schommer, H., Feldmeier, A.M., 1990. Detection of the schistosome circulating cathodic antigen by enzyme immunoassay using biotinylated monoclonal antibodies. *Trans. R. Soc. Trop. Med. Hyg* 84, 815-818.
- de Vlas, S.J., Gryseels, B., 1992. Underestimation of *Schistosoma mansoni* prevalences. *Parasitol. Today* 8, 274-277.
- de Water, R., Fransen, J.A., Deelder, A.M., 1986. Ultrastructural localization of the circulating anodic antigen in the digestive tract of *Schistosoma mansoni* using monoclonal antibodies in an immunogold labeling procedure. *Am. J. Trop. Med. Hyg.* 35, 549-558.

- Deelder, A.M., 1989. Sensitive determination of circulating anodic antigen in *Schistosoma mansoni* infected individuals by an enzyme-linked immunosorbent assay using monoclonal antibodies. *Am. J. Trop. Med. Hyg.* 40, 268-272.
- Deelder, A.M., Klappe, H.T.M., van den Aardweg, G.J.M.J., van Meerbeke, E.H.E.M., 1976. *Schistosoma mansoni*: Demonstration of two circulating antigens in infected hamsters. *Exp. Parasitol.* 40, 189-197.
- Deelder, A.M., Qian, Z.L., Kremsner, P.G., Acosta, L., Rabello, A.L., Enyong, P., Simarro, P.P., van Etten, E.C., Krijger, F.W., Rotmans, J.P., et al., 1994. Quantitative diagnosis of *Schistosoma* infections by measurement of circulating antigens in serum and urine. *Trop. Geogr. Med* 46, 233-238.
- dos-Santos, W.L.C., Sweet, G.M.M., Bahiense-Oliveira, M., Rocha, P.N., 2011. Schistosomal glomerulopathy and changes in the distribution of histological patterns of glomerular diseases in Bahia, Brazil. *Mem. Inst. Oswaldo Cruz* 106, 901-904.
- Dow, S.W., Legendre, A.M., Stiff, M., Greene, C., 1986. Hypercalcemia associated with blastomycosis in dogs. *J. Am. Vet. Med. Assoc.* 188, 706-709.
- Dusso, A., Finch, J., Delmez, J., Rapp, N., Lopez-Hilker, S., Brown, A., Slatopolsky, E., 1990. Extrarenal production of calcitriol. *Kidney Int. Suppl.* 29, S36-40.
- Eberl, M., al-Sherbiny, M., Hagan, P., Ljubojevic, S., Thomas, A.W., Wilson, R.A., 2002. A novel and sensitive method to monitor helminth infections by faecal sampling. *Acta Trop.* 83, 183-187.
- Ebrahim, A., El-Morshedy, H., Omer, E., El-Daly, S., Barakat, R., 1997. Evaluation of the Kato-Katz thick smear and formol ether sedimentation techniques for quantitative diagnosis of *Schistosoma mansoni* infection. *Am. J. Trop. Med. Hyg.* 57, 706-708.

- Elsa, L., Amadou, G., Amina, A.H., Bonnie, L.W., Tom, P., David, R., Joanne, P.W., 2016. Introgressed animal schistosomes *Schistosoma curassoni* and *S. bovis* naturally infecting humans. *Emerg. Infect. Dis.* 22, 2212.
- Erko, B., Medhin, G., Teklehaymanot, T., Degarege, A., Legesse, M., 2013. Evaluation of urine-circulating cathodic antigen (Urine-CCA) cassette test for the detection of *Schistosoma mansoni* infection in areas of moderate prevalence in Ethiopia. *Trop. Med. Int. Health* 18, 1029-1035.
- Fabrick, C., Bugbee, A., Fosgate, G., 2010. Clinical features and outcome of *Heterobilharzia americana* infection in dogs. *J. Vet. Intern. Med.* 24, 140-144.
- Faust, E.C., 1946. The diagnosis of schistosomiasis japonica; the diagnostic characteristics of the eggs of the etiologic agent *Schistosoma japonicum*. *Am. J. Trop. Med. Hyg.* 26, 113-123.
- Fedynich, A.M., Pence, D.B., Urubek, R.L., 1986. Helminth fauna of beaver from central Texas. *J. Wildl. Dis.* 22, 579-582.
- Feldman, R.G., Chester, K., 1968. Heterobilharziasis in a dog. *Southwest. Vet.* 21, 115-118.
- Feldmeier, H., Daccal, R.C., Martins, M.J., Soares, V., Martins, R., 1998. Genital manifestations of schistosomiasis mansoni in women: important but neglected. *Mem. Inst. Oswaldo Cruz* 1, 127-133.
- Flowers, J.R., Hammerberg, B., Wood, S.L., Malarkey, D.E., van Dam, G.J., Levy, M.G., McLawhorn, L.D., 2002. *Heterobilharzia americana* infection in a dog. *J. Am. Vet. Med. Assoc.* 220, 193-196, 183.
- Forrester, D.J., 1985. Parasites of the Florida panther (*Felis concolor coryi*). *Proc. Helminthol. Soc. Wash* 52, 95-97.

- Forrester, D.J. (Ed.), 1992. Parasites and diseases of wild mammals in Florida. University Press of Florida, Gainesville, 459 pp.
- Forrester, D.J., Telford, S.R., Foster, G.W., 1994. *Heterobilharzia americana* (Trematoda, Schistosomatidae) from white-tailed deer (*Odocoileus virginianus*) in southern Florida. J. Helminthol. Soc. Wash. 61, 128-129.
- Fradkin, J.M., Braniecki, A.M., Craig, T.M., Ramiro-Ibanez, F., Rogers, K.S., Zoran, D.L., 2001. Elevated parathyroid hormone-related protein and hypercalcemia in two dogs with schistosomiasis. J. Am. Anim. Hosp. Assoc. 37, 349-355.
- Fung, M.S., Xiao, N., Wang, S., Carlton, E.J., 2012. Field evaluation of a PCR test for *Schistosoma japonicum* egg detection in low-prevalence regions of China. Am. J. Trop. Med. Hyg. 87, 1053-1058.
- Gatehouse, H.S., Malone, L.A., 1998. The ribosomal RNA gene region of *Nosema apis* (Microspora): DNA sequence for small and large subunit rRNA genes and evidence of a large tandem repeat unit size. J. Invertebr. Pathol. 71, 97-105.
- Ghedini, E., Wang, S., Foster, J.M., Slatko, B.E., 2004. First sequenced genome of a parasitic nematode. Trends Parasitol. 20, 151-153.
- Glinz, D., Silue, K.D., Knopp, S., Lohourignon, L.K., Yao, K.P., Steinmann, P., Rinaldi, L., Cringoli, G., N'Goran, E.K., Utzinger, J., 2010. Comparing diagnostic accuracy of Kato-Katz, Koga agar plate, ether-concentration, and FLOTAC for *Schistosoma mansoni* and soil-transmitted helminths. PLoS Negl. Trop. Dis. 4, e754.
- Goecks, J., Nekrutenko, A., Taylor, J., 2010. Galaxy: a comprehensive approach for supporting accessible, reproducible, and transparent computational research in the life sciences. Genome Biol. 11, R86.

- Goff, W.L., Ronald, N.C., 1980. Miracidia hatching technique for diagnosis of canine schistosomiasis. *J. Am. Vet. Med. Assoc.* 177, 699-700.
- Goff, W.L., Ronald, N.C., 1981. Certain aspects of the biology and life cycle of *Heterobilharzia americana* in east central Texas. *Am. J. Vet. Res.* 42, 1775-1777.
- Goff, W.L., Ronald, N.C., 1982. Indirect hemagglutination for the diagnosis of *Heterobilharzia americana* infections in dogs. *Am. J. Vet. Res.* 43, 2038-2041.
- Gomes, L.I., Enk, M.J., Rabello, A., 2014. Diagnosing schistosomiasis: where are we? *Rev. Soc. Bras. Med. Trop* 47, 3-11.
- Goncalves, M.M., Barreto, M.G., Peralta, R.H., Gargioni, C., Goncalves, T., Igreja, R.P., Soares, M.S., Peralta, J.M., 2006. Immunoassays as an auxiliary tool for the serodiagnosis of *Schistosoma mansoni* infection in individuals with low intensity of egg elimination. *Acta Trop.* 100, 24-30.
- Grenfell, R.F., Coelho, P.M., Taboada, D., de Mattos, A.C., Davis, R., Harn, D.A., 2014. Newly established monoclonal antibody diagnostic assays for *Schistosoma mansoni* direct detection in areas of low endemicity. *PLoS ONE* 9, e87777.
- Gryseels, B., Polman, K., Clerinx, J., Kestens, L., 2006. Human schistosomiasis. *Lancet* 368, 1106-1118.
- Hamburger, J., He, N., Abbasi, I., Ramzy, R.M., Jourdane, J., Ruppel, A., 2001. Polymerase chain reaction assay based on a highly repeated sequence of *Schistosoma haematobium*: a potential tool for monitoring schistosome-infested water. *Am. J. Trop. Med. Hyg.* 65, 907-911.

- Hamburger, J., Turetski, T., Kapeller, I., Deresiewicz, R., 1991. Highly repeated short DNA sequences in the genome of *Schistosoma mansoni* recognized by a species-specific probe. *Mol. Biochem. Parasitol.* 44, 73-80.
- Hamilton, J.V., Klinkert, M., Doenhoff, M.J., 1999. Diagnosis of schistosomiasis: antibody detection, with notes on parasitological and antigen detection methods. *Parasitology* 117, 41-57.
- Hanzlicek, A.S., Harkin, K.R., Dryden, M.W., Chun, R., Payne, P.A., Nietfeld, J.C., Debey, B.M., 2011. Canine schistosomiasis in Kansas: five cases (2000-2009). *J. Am. Anim. Hosp. Assoc.* 47, e95-e102.
- Harkema, R., Miller, G.C., 1964. Helminth parasites of the raccoon, *Procyon lotor* in the southeastern United States. *J. Vet. Parasitol.* 50, 60-66.
- Haslam, S.M., Coles, G.C., Morris, H.R., Dell, A., 2000. Structural characterization of the N-glycans of *Dictyocaulus viviparus*: discovery of the Lewis(x) structure in a nematode. *Glycobiology* 10, 223-229.
- He, Y.X., 1993. Biology of *Schistosoma japonicum*. From cercaria penetrating into host skin to producing egg. *Chin. Med. J.* 106, 576-583.
- Herber, E.C., 1938. Schistosome dermatitis in dogs. *J. Parasitol.* 24, 474-475.
- Hinz, R., Schwarz, N.G., Hahn, A., Frickmann, H., 2017. Serological approaches for the diagnosis of schistosomiasis – A review. *Mol. Cell. Probes* 31, 2-21.
- Hira, P.R., 1975. Observations on *Schistosoma mattheei* Veglia and Le Roux, 1929 infections in man in Zambia. *Ann. Soc. Belg. Med. Trop.* 55, 633-642.

- Hoorfar, J., Malorny, B., Abdulmawjood, A., Cook, N., Wagner, M., Fach, P., 2004. Practical considerations in design of internal amplification controls for diagnostic PCR assays. *J. Clin. Microbiol.* 42, 1863-1868.
- Horák, P., Mikeš, L., Lichtenbergová, L., Skála, V., Soldánová, M., Brant, S.V., 2015. Avian schistosomes and outbreaks of cercarial dermatitis. *Clin. Microbiol. Rev.* 28, 165-190.
- Houston, S., Kowalewska-Grochowska, K., Naik, S., McKean, J., Johnson, E.S., Warren, K., 2004. First report of *Schistosoma mekongi* infection with brain involvement. *Clin. Infect. Dis.* 38, e1-6.
- Johansen, M.V., Fillie, Y., Monrad, J., Christensen, N.O., Deelder, A., 1996. Experimental *Schistosoma bovis* infection in goats. Circulating antigen and antibody responses to egg and adult worm antigens during infection and following treatment with praziquantel. *Parasitology* 113 (Pt 4), 367-375.
- Johnson, E., 2010. Canine schistosomiasis in North America: an underdiagnosed disease with an expanding distribution. *Compend. Contin. Educ. Vet.* 32, E1-4.
- Jordan, P., Webbe, G., Sturrock, R.F. (Eds.), 1993. Human schistosomiasis. CAB International, Wallingford, 465 pp.
- Kabore, A., Ibikounle, M., Tougoue, J.J., Mupoyi, S., Ndombe, M., Shannon, S., Ottesen, E.A., Mukunda, F., Awaca, N., 2017. Initiating NTD programs targeting schistosomiasis and soil-transmitted helminthiasis in two provinces of the Democratic Republic of the Congo: Establishment of baseline prevalence for mass drug administration. *Acta Trop.* 166, 177-185.

- Kagan, I.G., Short, R.B., Nez, M.M., 1954. Maintenance of *Schistosomatium douthitti* (Cort, 1914) in the Laboratory (Trematoda: Schistosomatidae). *J. Parasitol.* 40, 424-439.
- Kaplan, E.H., 1964. *Heterobilharzia americana* Price, 1929, in the opossum from Louisiana. *J. Parasitol.* 50, 797.
- Katz, N., Chaves, A., Pellegrino, J., 1972. A simple device for quantitative stool thick-smear technique in schistosomiasis mansoni. *Rev. Inst. Med. Trop. Sao Paulo* 14, 397-400.
- Kelley, S.W., 2010. Heterobilharziasis (Trematoda: Schistosomatidae) in raccoons (*Procyon lotor*) of north-central Texas. *Tex. J. Sci.* 62, 41-48.
- Khosla, S., Danks, J., 1990. Parathyroid hormone-related protein and hypercalcemia secondary to massive mammary hyperplasia. *New Engl. J. Med.* 322, 1157-1157.
- Kinkel, H.-F., Dittrich, S., Bäumer, B., Weitzel, T., 2012. Evaluation of eight serological tests for diagnosis of imported schistosomiasis. *Clin. Vaccine Immunol.* 19, 948-953.
- Kirkpatrick, C.E., Shelly, E.A., 1985. Paragonimiasis in a dog: treatment with praziquantel. *J. Am. Vet. Med. Assoc.* 187, 75-76.
- Kittur, N., Castleman, J.D., Campbell, C.H., King, C.H., Colley, D.G., 2016. Comparison of *Schistosoma mansoni* prevalence and intensity of infection, as determined by the circulating cathodic antigen urine assay or by the kato-katz fecal assay: a systematic review. *Am. J. Trop. Med. Hyg.* 94, 605-610.
- Knecht, T.P., Behling, C.A., Burton, D.W., Glass, C.K., Deftos, L.J., 1996. The humoral hypercalcemia of benignancy: a newly appreciated syndrome. *Am. J. Clin. Pathol.* 105, 487-492.

- Kongs, A., Marks, G., Verle, P., Van der Stuyft, P., 2001. The unreliability of the Kato-Katz technique limits its usefulness for evaluating *S. mansoni* infections. Trop. Med. Int. Health 6, 163-169.
- Kremsner, P.G., de Jonge, N., Simarro, P.P., Muhlschlegel, F., Mir, M., Sima, F.O., Feldmeier, H., Bienzle, U., Deelder, A.M., 1993. Quantitative determination of circulating anodic and cathodic antigens in serum and urine of individuals infected with *Schistosoma intercalatum*. Trans. R. Soc. Trop. Med. Hyg 87, 167-169.
- Kremsner, P.G., Enyong, P., Krijger, F.W., de Jonge, N., Zotter, G.M., Thalhammer, F., Muhlschlegel, F., Bienzle, U., Feldmeier, H., Deelder, A.M., 1994. Circulating anodic and cathodic antigen in serum and urine from *Schistosoma haematobium*-infected Cameroonian children receiving praziquantel: a longitudinal study. Clin. Infect. Dis. 18, 408-413.
- Krijger, F.W., van Lieshout, L., Deelder, A.M., 1994. A simple technique to pretreat urine and serum samples for quantitation of schistosome circulating anodic and cathodic antigen. Acta Trop. 56, 55-63.
- Krotoski, W.A., Job, C.K., Cogswell, F.B., Malek, E.A., 1984. Enzootic schistosomiasis in a Louisiana armadillo. Am. J. Trop. Med. Hyg. 33, 269-272.
- Kvitko-White, H.L., Sayre, R.S., Corapi, W.V., Spaulding, K.A., 2011. Imaging diagnosis-*Heterobilharzia americana* infection in a dog. Vet. Radiol. Ultrasound 52, 538-541.
- Laha, T., Brindley, P.J., Smout, M.J., Verity, C.K., McManus, D.P., Loukas, A., 2002. Reverse transcriptase activity and untranslated region sharing of a new RTE-like, non-long terminal repeat retrotransposon from the human blood fluke, *Schistosoma japonicum*. Int. J. Parasitol. 32, 1163-1174.

- Lamberton, P.H., Kabatereine, N.B., Oguttu, D.W., Fenwick, A., Webster, J.P., 2014. Sensitivity and specificity of multiple Kato-Katz thick smears and a circulating cathodic antigen test for *Schistosoma mansoni* diagnosis pre- and post-repeated-praziquantel treatment. PLoS Negl. Trop. Dis. 8, e3139.
- Le Donne, V., McGovern, D.A., Fletcher, J.M., Grasperge, B.J., 2016. Cytologic diagnosis of *Heterobilharzia americana* infection in a liver aspirate from a dog. Vet. Pathol. 53, 633-636.
- Lee, H.F., 1962. Life history of *Heterobilharzia americana* Price 1929, a schistosome of the raccoon and other mammals in southeastern United States. J. Parasitol. 48, 728-739.
- Leger, E., Webster, J.P., 2016. Hybridizations within the genus *Schistosoma*: implications for evolution, epidemiology and control. Parasitology 144, 65-80.
- Legesse, M., Erko, B., 2007. Field-based evaluation of a reagent strip test for diagnosis of *Schistosoma mansoni* by detecting circulating cathodic antigen in urine before and after chemotherapy. Trans. R. Soc. Trop. Med. Hyg. 101, 668-673.
- Lier, T., Johansen, M.V., Hjelmevoll, S.O., Vennervald, B.J., Simonsen, G.S., 2008. Real-time PCR for detection of low intensity *Schistosoma japonicum* infections in a pig model. Acta Trop. 105, 74-80.
- Lier, T., Simonsen, G.S., Haaheim, H., Hjelmevoll, S.O., et al., 2006. Novel real-time PCR for detection of *Schistosoma japonicum* in stool. Southeast Asian J. Trop. Med. Public Health 37, 257-264.
- Malek, E., 1969. Correlation analyses of cercarial exposure, worm load and egg content in stools of dogs infected with *Heterobilharzia americana*. Z. Tropenmed. Parasitol. 20, 333-340.

- Malek, E.A., 1970. Further studies on mammalian susceptibility to experimental infection with *Heterobilharzia americana*. J. Parasitol. 56, 64-66.
- Malek, E.A., 1977. Geographical distribution, hosts, and biology of *Schistosomatium douthitti* (Cort, 1914) Price, 1931. Can. J. Zool. 55, 661-671.
- Malek, E.A., Armstrong, J.C., 1967. Infection with *Heterobilharzia americana* in primates. Am. J. Trop. Med. Hyg. 16, 708-714.
- Malek, E.A., Ash, L.R., Lee, H.F., Little, M.D., 1961. *Heterobilharzia* infection in the dog and other mammals in Louisiana. J. Parasitol. 47, 619-623.
- McHenry, K.M., Dujowich, M., Oliveira, C.R., 2017. What is your diagnosis? J. Am. Vet. Med. Assoc. 250, 505-507.
- McKown, R.D., Veatch, J.K., Fox, L.B., 1991. New locality record for *Heterobilharzia americana*. J. Wildl. Dis. 27, 156-160.
- Mealey, K.L., Willard, M.D., Nagode, L.A., Helman, R.G., 1999. Hypercalcemia associated with granulomatous disease in a cat. J. Am. Vet. Med. Assoc. 215, 959-962.
- Midzi, N., Butterworth, A.E., Mduluzi, T., Munyati, S., Deelder, A.M., van Dam, G.J., 2009. Use of circulating cathodic antigen strips for the diagnosis of urinary schistosomiasis. Trans. R. Soc. Trop. Med. Hyg. 103, 45-51.
- Miller, G.C., Harkema, R., 1960. A new locality record for *Heterobilharzia americana* Price, 1929. J. Parasitol. 46, 206.
- Mohammed, E.H.A., Eltayeb, M., Ibrahim, H., 2006. Haematological and biochemical morbidity of *Schistosoma haematobium* in school children in Sudan. Sultan Qaboos Univ. Med. J. 6, 59-64.

- Morgan, J.A.T., DeJong, R.J., Kazibwe, F., Mkoji, G.M., Loker, E.S., 2003. A newly-identified lineage of *Schistosoma*. *Int. J. Parasitol.* 33, 977-985.
- Mwinzi, P.N.M., Kittur, N., Ochola, E., Cooper, P.J., Campbell, C.H., King, C.H., Colley, D.G., 2015. Additional evaluation of the point-of-contact circulating cathodic antigen assay for *Schistosoma mansoni* infection. *Front. Public Health* 3, 48.
- Novák, P., Neumann, P., Macas, J., 2010. Graph-based clustering and characterization of repetitive sequences in next-generation sequencing data. *BMC Bioinformatics* 11, 378.
- Novák, P., Neumann, P., Pech, J., Steinhaisl, J., Macas, J., 2013. RepeatExplorer: a Galaxy-based web server for genome-wide characterization of eukaryotic repetitive elements from next-generation sequence reads. *Bioinformatics* 29, 792-793.
- Nyame, A.K., Debose-Boyd, R., Long, T.D., Tsang, V.C., Cummings, R.D., 1998. Expression of Le^x antigen in *Schistosoma japonicum* and *S. haematobium* and immune responses to Le^x in infected animals: lack of Le^x expression in other trematodes and nematodes. *Glycobiology* 8, 615-624.
- Obeng, B.B., Aryeetey, Y.A., de Dood, C.J., Amoah, A.S., Larbi, I.A., Deelder, A.M., Yazdanbakhsh, M., Hartgers, F.C., Boakye, D.A., Verweij, J.J., van Dam, G.J., van Lieshout, L., 2008. Application of a circulating-cathodic-antigen (CCA) strip test and real-time PCR, in comparison with microscopy, for the detection of *Schistosoma haematobium* in urine samples from Ghana. *Ann. Trop. Med. Parasitol.* 102, 625-633.
- Oliveira, L.M.A., Santos, H.L.C., Goncalves, M.M.L., Barreto, M.G.M., Peralta, J.M., 2010. Evaluation of polymerase chain reaction as an additional tool for the diagnosis of low-intensity *Schistosoma mansoni* infection. *Diagn. Micr. Infec Dis.* 68, 416-421.

- Palumbo, E., 2007. Association between schistosomiasis and cancer: a review. *Infect. Dis. Clin. Pract.* 15, 145-148.
- Pierce, K.R., 1963. *Heterobilharzia americana* infection in a dog. *J. Am. Vet. Med. Assoc.* 143, 496-499.
- Pilotte, N., Papaiakovou, M., Grant, J.R., Bierwert, L.A., Llewellyn, S., McCarthy, J.S., Williams, S.A., 2016. Improved PCR-based detection of soil transmitted helminth infections using a next-generation sequencing approach to assay design. *PLoS Negl. Trop. Dis.* 10, e0004578.
- Pitchford, R.J., Visser, P.S., 1975. Excretion of *Schistosoma mattheei* eggs from man, baboons and cattle living in their normal environment. *J. Helminthol.* 49, 137-142.
- Poderoso, W.L.S., 2008. Ectopic schistosomiasis: Description of five cases involving skin, one ovarian case and one adrenal case. *Rev. Soc. Bras. Med. Trop.* 41, 668-671.
- Polderman, A.M., Panday, U.G., Ramkisoen, S., Lieshout, L.v., Oostburg, B.F.J., 1994. A sedimentation-selective filtration method for the diagnosis of light infections with *Schistosoma mansoni*. *Acta Trop.* 58, 221-227.
- Polman, K., Engels, D., Fathers, L., Deelder, A.M., Gryseels, B., 1998. Day-to-day fluctuation of schistosome circulating antigen levels in serum and urine of humans infected with *Schistosoma mansoni* in Burundi. *Am. J. Trop. Med. Hyg.* 59, 150-154.
- Pontes, L.A., Dias-Neto, E., Rabello, A., 2002. Detection by polymerase chain reaction of *Schistosoma mansoni* DNA in human serum and feces. *Am. J. Trop. Med. Hyg.* 66, 157-162.

- Pontes, L.A., Oliveira, M.C., Katz, N., Dias-Neto, E., Rabello, A., 2003. Comparison of a polymerase chain reaction and the Kato-Katz technique for diagnosing infection with *Schistosoma mansoni*. *Am. J. Trop. Med. Hyg.* 68, 652-656.
- Price, E.W., 1929. A synopsis of the trematode family Schistosomidae, with descriptions of new genera and species. *Proc. US. Nat. Mus.* 75, 1-39.
- Price, E.W., 1943. A redescription of *Heterobilharzia americana* Price (Trematoda: Schistosomatidae). *Proc. Helm. Soc. Wash.* 10, 85-87.
- Qian, Z.L., Deelder, A.M., 1983. *Schistosoma japonicum*: immunological characterization and detection of circulating polysaccharide antigens from adult worms. *Exp. Parasitol.* 55, 168-178.
- Qian, Z.L., Deelder, A.M., 1993. Dot immunoassay with biotinylated antigen for determination of antibodies against the circulating cathodic antigen (CCA) in schistosomiasis japonica. *Am. J. Trop. Med. Hyg.* 49, 777-782.
- Ravakhah, K., Gover, A., Mukunda, B.N., 1999. Humoral hypercalcemia associated with a uterine fibroid. *Ann. Intern. Med.* 130, 702.
- Ravindran, R., 2012. Nasal schistosomiasis among large ruminants in Wayanad, India. *Southeast Asian J. Trop. Med. Public Health* 43, 586-588.
- Ridley, D.S., Hawgood, B.C., 1956. The value of formol-ether concentration of faecal cysts and ova. *J. Clin. Pathol.* 9, 74-76.
- Ritchie, L.S., 1948. An ether sedimentation technique for routine stool examinations. *Bull. U. S. Army Med. Dep.* 8, 326.
- Rocha, H., Cruz, T., Brito, E., Susin, M., 1976. Renal involvement in patients with hepatosplenic schistosomiasis mansoni. *Am. J. Trop. Med. Hyg.* 25, 108-115.

- Rodrigues, V.L., Otoni, A., Voieta, I., Antunes, C.M.d.F., Lambertucci, J.R., 2010. Glomerulonephritis in schistosomiasis mansoni: a time to reappraise. *Rev. Soc. Bras. Med. Trop* 43, 638-642.
- Rodriguez, J.Y., Camp, J.W., Lenz, S.D., Kazacos, K.R., Snowden, K.F., 2016. Identification of *Heterobilharzia americana* infection in a dog residing in Indiana with no history of travel. *J. Am. Vet. Med. Assoc.* 248, 827-830.
- Rodriguez, J.Y., Lewis, B.C., Snowden, K.F., 2014. Distribution and characterization of *Heterobilharzia americana* in dogs in Texas. *Vet. Parasitol.* 203, 35-42.
- Rohrer, C.R., Phillips, L.A., Ford, S.L., Ginn, P.E., 2000. Hypercalcemia in a dog: a challenging case. *J. Am. Anim. Hosp. Assoc.* 36, 20-25.
- Rollinson, D., Southgate, V.R., Vercruyse, J., Moore, P.J., 1990. Observations on natural and experimental interactions between *Schistosoma bovis* and *S. curassoni* from West Africa. *Acta Trop.* 47, 101-114.
- Ronald, N.C., Craig, T.M., 1983. Fenbendazole for the treatment of *Heterobilharzia americana* infection in dogs. *J. Am. Vet. Med. Assoc.* 182, 172.
- Roset, R., Subirana, J.A., Messeguer, X., 2003. MREPATT: detection and analysis of exact consecutive repeats in genomic sequences. *Bioinformatics* 19, 2475-2476.
- Ross, A.G., McManus, D.P., Farrar, J., Hunstman, R.J., Gray, D.J., Li, Y.S., 2012. Neuroschistosomiasis. *J. Neurol.* 259, 22-32.
- Roux, A.L., Ryan, K., Hof, M.I., Lanaux, A., Gaschen, L., 2015. What is your diagnosis? *J. Am. Vet. Med. Assoc.* 246, 411-413.
- Ruth, J., 2010. *Heterobilharzia americana* infection and glomerulonephritis in a dog. *J. Am. Anim. Hosp. Assoc.* 46, 203-208.

- Schaffer, G.D., Davidson, W.R., Nettles, V.F., Rollor, E.A., 1981. Helminth parasites of translocated raccoons (*Procyon lotor*) in the southeastern United States. J. Wildl. Dis. 17, 217-227.
- Shane, H.L., Verani, J.R., Abudho, B., Montgomery, S.P., Blackstock, A.J., Mwinzi, P.N., Butler, S.E., Karanja, D.M., Secor, W.E., 2011. Evaluation of urine CCA assays for detection of *Schistosoma mansoni* infection in Western Kenya. PLoS Negl. Trop. Dis. 5, e951.
- Shidham, V.B., 1991. A rapid, economical, and simple method for concentration of *Schistosoma mansoni* ova in feces. Am. J. Clin. Pathol. 95, 91-95.
- Shoop, W.L., Corkum, K.C., 1982. Additional trematodes of mammals in Louisiana with a compilation of all trematodes reported from wild and domestic mammals in the state. Tulane Stud. Zoo. Bot. 23, 109-122.
- Silveira, A.M.S., Costa, E.G.D., Fraga, L.A.O., Ray, D., Suzuki, B.M., Caffrey, C.R., Hsieh, M.H., 2016. Evaluation of the CCA Immuno-chromatographic test to diagnose *Schistosoma mansoni* in Minas Gerais state, Brazil. PLoS Negl. Trop. Dis. 10, 0004357.
- Slaughter, J.B., Billups, L.H., Acor, G.K., 1988. Canine Heterobilharziasis. Comp. Contin. Educ. Pract. Vet. 10, 606-612.
- Sponenberg, P., 1973. Heterobilharziasis. Southwest. Vet. 29, 159-161.
- Stauffer, S.H., Birkenheuer, A.J., Levy, M.G., Marr, H., Gookin, J.L., 2008. Evaluation of four DNA extraction methods for the detection of *Trichostrongylus axei* in feline stool specimens by polymerase chain reaction. J. Vet. Diagn. Invest. 20, 639-641.

- Stone, R.H., Frontera-Acevedo, K., Saba, C.F., Ambrose, D., Moorhead, A.R., Brown, C.A., 2011. Lymphosarcoma associated with *Heterobilharzia americana* infection in a dog. J. Vet. Diagn. Invest. 23, 1065-1070.
- Stothard, J.R., Kabatereine, N.B., Tukahebwa, E.M., Kazibwe, F., Rollinson, D., Mathieson, W., Webster, J.P., Fenwick, A., 2006. Use of circulating cathodic antigen (CCA) dipsticks for detection of intestinal and urinary schistosomiasis. Acta Trop. 97, 219-228.
- Subirana, J.A., Messeguer, X., 2013. A satellite explosion in the genome of holocentric nematodes. PLoS. One 8, e62221.
- Symmers, W.S.C., 1904. Note on a new form of liver cirrhosis due to the presence of the ova of *Bilharzia haematobia*. J. Pathol. Bacteriol. 9, 237-239.
- Tchuem Tchuente, L.A., Kuete Fouodo, C.J., Kamwa Ngassam, R.I., Sumo, L., Dongmo Noumedem, C., Kenfack, C.M., Gipwe, N.F., Nana, E.D., Stothard, J.R., Rollinson, D., 2012. Evaluation of circulating cathodic antigen (CCA) urine-tests for diagnosis of *Schistosoma mansoni* infection in Cameroon. PLoS Negl. Trop. Dis. 6, e1758.
- Thrasher, J.P., 1964. Canine schistosomiasis. J. Am. Vet. Med. Assoc. 144, 1119-1126.
- Treangen, T.J., Salzberg, S.L., 2012. Repetitive DNA and next-generation sequencing: computational challenges and solutions. Nat. Rev. Genet. 13, 36-46.
- Troy, G.C., Forrester, D., Cockburn, C., Morton, L.D., Storts, R., Wilson, E., Craig, T., 1987. *Heterobilharzia americana* infection and hypercalcemia in a dog: a case report. J. Am. Anim. Hosp. Assoc. 23, 35-40.
- Urbani, C., Sinoun, M., Socheat, D., Pholsena, K., Strandgaard, H., Odermatt, P., Hatz, C., 2002. Epidemiology and control of mekongi schistosomiasis. Acta Trop. 82, 157-168.

- Utzinger, J., Booth, M., N'Goran, E.K., Muller, I., Tanner, M., Lengeler, C., 2001. Relative contribution of day-to-day and intra-specimen variation in faecal egg counts of *Schistosoma mansoni* before and after treatment with praziquantel. *Parasitology* 122, 537-544.
- Van 't Wout, A.B., De Jonge, N., Wood, S.M., Van Lieshout, L., Mitchell, G.F., Deelder, A.M., 1995. Serum levels of circulating anodic antigen and circulating cathodic antigen detected in mice infected with *Schistosoma japonicum* or *S. mansoni*. *Parasitol. Res.* 81, 434-437.
- Van Dam, G.J., Bergwerff, A.A., Thomas-Oates, J.E., Rotmans, J.P., Kamerling, J.P., Vliegthart, J.F., Deelder, A.M., 1994. The immunologically reactive O-linked polysaccharide chains derived from circulating cathodic antigen isolated from the human blood fluke *Schistosoma mansoni* have Lewis x as repeating unit. *Eur. J. Biochem.* 225, 467-482.
- van Dam, G.J., Bogitsh, B.J., van Zeyl, R.J., Rotmans, J.P., Deelder, A.M., 1996a. *Schistosoma mansoni*: in vitro and in vivo excretion of CAA and CCA by developing schistosomula and adult worms. *J. Parasitol.* 82, 557-564.
- van Dam, G.J., Claas, F.H., Yazdanbakhsh, M., Kruize, Y.C., van Keulen, A.C., Ferreira, S.T., Rotmans, J.P., Deelder, A.M., 1996b. *Schistosoma mansoni* excretory circulating cathodic antigen shares Lewis-x epitopes with a human granulocyte surface antigen and evokes host antibodies mediating complement-dependent lysis of granulocytes. *Blood* 88, 4246-4251.
- van Dam, G.J., de Dood, C.J., Lewis, M., Deelder, A.M., van Lieshout, L., Tanke, H.J., van Rooyen, L.H., Corstjens, P.L., 2013. A robust dry reagent lateral flow assay for

- diagnosis of active schistosomiasis by detection of *Schistosoma* circulating anodic antigen. *Exp. Parasitol.* 135, 274-282.
- van Dam, G.J., Odermatt, P., Acosta, L., Bergquist, R., de Dood, C.J., Kornelis, D., Muth, S., Utzinger, J., Corstjens, P.L., 2015. Evaluation of banked urine samples for the detection of circulating anodic and cathodic antigens in *Schistosoma mekongi* and *S. japonicum* infections: A proof-of-concept study. *Acta Trop.* 141, 198-203.
- van Dam, G.J., Wichers, J.H., Ferreira, T.M., Ghatai, D., van Amerongen, A., Deelder, A.M., 2004. Diagnosis of schistosomiasis by reagent strip test for detection of circulating cathodic antigen. *J. Clin. Microbiol.* 42, 5458-5461.
- van Dijk, K., Starink, M.V., Bart, A., Nijhuis, E.W.P., van der Wal, A.C., van Thiel, P.P.A.M., de Vries, H.J.C., van Gool, T., 2010. The potential of molecular diagnosis of cutaneous ectopic schistosomiasis. *Am. J. Trop. Med. Hyg.* 83, 958-959.
- Van Etten, L., Engels, D., Krijger, F.W., Nkulikyinka, L., Gryseels, B., Deelder, A.M., 1996. Fluctuation of schistosome circulating antigen levels in urine of individuals with *Schistosoma mansoni* infection in Burundi. *Am. J. Trop. Med. Hyg.* 54, 348-351.
- van Etten, L., Folman, C.C., Eggelte, T.A., Kremsner, P.G., Deelder, A.M., 1994. Rapid diagnosis of schistosomiasis by antigen detection in urine with a reagent strip. *J. Clin. Microbiol.* 32, 2404-2406.
- van Lieshout, L., de Jonge, N., el-Masry, N., Mansour, M.M., Bassily, S., Krijger, F.W., Deelder, A.M., 1994. Monitoring the efficacy of different doses of praziquantel by quantification of circulating antigens in serum and urine of schistosomiasis patients. *Parasitology* 108 (Pt 5), 519-526.

- Vermund, S.H., Bradley, D.J., Ruiz-Tiben, E., 1983. Survival of *Schistosoma mansoni* in the human host: estimates from a community-based prospective study in Puerto Rico. *Am. J. Trop. Med. Hyg.* 32, 1040-1048.
- Webster, B.L., Southgate, V.R., Littlewood, D.T.J., 2006. A revision of the interrelationships of *Schistosoma* including the recently described *Schistosoma guineensis*. *Int. J. Parasitol.* 36, 947-955.
- Weerakoon, K., Gobert, G.N., Cai, P.F., McManus, D.P., 2015. Advances in the diagnosis of human schistosomiasis. *Clin. Microbiol. Rev.* 28, 939-967.
- Wen, L.Y., Chen, J.H., Ding, J.Z., Zhang, J.F., Lu, S.H., Yu, L.L., Shen, L.Y., Wu, G.L., Zhou, X.N., Zheng, J., 2005. Evaluation on the applied value of the dot immunogold filtration assay (DIGFA) for rapid detection of anti-*Schistosoma japonicum* antibody. *Acta Trop.* 96, 142-147.
- Weyher, A.H., Phillips-Conroy, J.E., Fischer, K., Weil, G.J., Chansa, W., Fischer, P.U., 2010. Molecular identification of *Schistosoma mattheei* from feces of Kinda (*Papio cynocephalus kindae*) and grayfoot baboons (*Papio ursinus griseipes*) in Zambia. *J. Parasitol.* 96, 184-190.
- Wright, C.A., Southgate, V.R., Howard, G.W., 1979. Observations on the life-cycle of *Schistosoma margrebowiei* and its possible interactions with *S. leiperi* in Zambia. *J. Nat. Hist.* 13, 499-506.
- Wright, C.A., Southgate, V.R., Knowles, R.J., 1972. What is *Schistosoma intercalatum* Fisher, 1934? *Trans. R. Soc. Trop. Med. Hyg.* 66, 28-56.

- Xia, C.M., Rong, R., Lu, Z.X., Shi, C.J., Xu, J., Zhang, H.Q., Gong, W., Luo, W., 2009. *Schistosoma japonicum*: A PCR assay for the early detection and evaluation of treatment in a rabbit model. *Exp. Parasitol.* 121, 175-179.
- Xu, J., Feng, T., Lin, D.D., Wang, Q.-Z., Tang, L., Wu, X.-H., Guo, J.-G., Peeling, R.W., Zhou, X.-N., 2011. Performance of a dipstick dye immunoassay for rapid screening of *Schistosoma japonicum* infection in areas of low endemicity. *Parasit. Vectors* 4, 87.
- Xu, J., Rong, R., Zhang, H.Q., Shi, C.J., Zhu, X.Q., Xia, C.M., 2010. Sensitive and rapid detection of *Schistosoma japonicum* DNA by loop-mediated isothermal amplification (LAMP). *Int. J. Parasitol.* 40, 327-331.
- Yamini, B., Schillhorn van Veen, T.W., 1988. Schistosomiasis and nutritional myopathy in a Brazilian tapir (*Tapirus terrestris*). *J. Wildl. Dis.* 24, 703-707.
- Young, K.H., Bullock, S.L., Melvin, D.M., Spruill, C.L., 1979. Ethyl acetate as a substitute for diethyl ether in the formalin-ether sedimentation technique. *J. Clin. Microbiol.* 10, 852-853.
- Yu, J., De Vlas, S.J., Yuan, H.C., Gryseels, B., 1998. Variations in fecal *Schistosoma japonicum* egg counts. *Am. J. Trop. Med. Hyg.* 59, 370-375.
- Yu, J.M., de Vlas, S.J., Jiang, Q.W., Gryseels, B., 2007. Comparison of the Kato-Katz technique, hatching test and indirect hemagglutination assay (IHA) for the diagnosis of *Schistosoma japonicum* infection in China. *Parasitol. Int.* 56, 45-49.
- Zajac, A., Conboy, G., 2012. *Clinical Veterinary Parasitology*, 8th Edition. Wiley-Blackwell, New York, NY.

- Zhou, X.N., Wang, L.Y., Chen, M.G., Wu, X.H., Jiang, Q.W., Chen, X.Y., Jiang, Z., Utzinger, J., 2005. The public health significance and control of schistosomiasis in China - Then and now. *Acta Trop.* 96, 97-105.
- Zhu, Y.C., 2005. Immunodiagnosis and its role in schistosomiasis control in China: a review. *Acta Trop.* 96, 130-136.
- Zhu, Y.C., Socheat, D., Bounlu, K., Liang, Y.S., Sinuon, M., Insisiengmay, S., He, W., Xu, M., Shi, W.Z., Bergquist, R., 2005. Application of dipstick dye immunoassay (DDIA) kit for the diagnosis of schistosomiasis mekongi. *Acta Trop.* 96, 137-141.
- Zhu, Y., He, W., Liang, Y., Xu, M., Yu, C., Hua, W., Chao, G., 2002. Development of a rapid, simple dipstick dye immunoassay for schistosomiasis diagnosis. *J. Immunol. Methods* 266, 1-5.