

Enteric Infection with an Obligate Intracellular Parasite, *Encephalitozoon cuniculi*, in an Experimental Model

V. WICHER,^{1*} R. E. BAUGHN,² C. FUENTEALBA,³ J. A. SHADDUCK,³ F. ABBRUSCATO,¹ AND K. WICHER¹

Wadsworth Center for Laboratories and Research, New York State Department of Health, Albany, New York 12201-0509¹; Departments of Microbiology and Immunology and of Dermatology, Baylor College of Medicine, and Syphilis Research Laboratory, Veterans Administration Medical Center, Houston, Texas 77211²; and College of Veterinary Medicine, Texas A&M University, College Station, Texas 77843-4461³

Received 20 December 1990/Accepted 4 April 1991

Rabbits were intrarectally infected with 3 doses (5×10^3 , 5×10^5 , and 5×10^7) of an obligate intracellular parasite, *Encephalitozoon cuniculi*, with or without prior colonic lavages. Although chronic administration of enemas seems to interfere to some degree with the intestinal translocation of the parasite, systemic infection was observed in both manipulated and nonmanipulated animals. The animals responded with antibodies of immunoglobulin A (IgA) and IgG isotypes, reflecting the route of infection. They also produced significant amounts of circulating immune complexes composed of IgA and IgG antibodies and *E. cuniculi* antigens. Lesions compatible with encephalitozoonosis were seen in the liver, kidney, lung, and brain. In all instances, nonmanipulated animals had more severe lesions than manipulated rabbits given the same dose of parasites. Levels of serum antibodies, circulating immune complexes, and histopathologic changes were associated with the infection dose. The presented data suggest that human microsporidiosis may also be transmitted via the rectal route. It is, therefore, of clinical relevance in view of several reports of microsporidian infections in patients with acquired immunodeficiency.

Systemic infections with enteric microorganisms (protozoa, bacteria, and viruses) in homosexual and bisexual men were reported long before AIDS was recognized (10, 16, 20, 38). They are frequently associated with malabsorption, diarrhea, weight loss, and anemia (18). Infection with commonly recognized agents of sexually transmitted diseases and enteric pathogens are traditionally associated with the rectal-oral route of transmission. Moreover, findings regarding several pathological processes affecting the liver of homosexual men with or without AIDS (7, 13) have stressed the vulnerability of this organ as one of the major targets of enteric infections.

Although it is questionable whether deterioration of the immune system is the cause or consequence of infection with the human immunodeficiency virus, it is undisputable that homosexual men are the most affected by the disease (17, 29). Results of previous experimental studies suggested that long-term colonic lavages (43, 44) and intrarectal (i.r.) insemination (31, 44, 45) may selectively predispose the host to immunosuppression. Chronic colonic lavages promoted an increase in the humoral response to soluble (seminal fluid and bovine serum albumin) and particulate (spermatozoa and sonicated sheep erythrocytes) antigens and the production of immune complexes (43–45). The implication is that this kind of manipulation may increase the host susceptibility to sensitization with multiple enteric antigens and to infection with opportunistic and pathogenic microorganisms. Among other risk factors, enema/douche use before sex have been associated with human immunodeficiency virus infection in two cohort studies involving 2,507 (17) and approximately 5,000 (22) homosexual men.

To further delineate the contributory role of the enteric route to systemic infection, we have chosen as a marker the obligate intracellular parasite *Encephalitozoon cuniculi*. *E.*

cuniculi is a microsporidian parasite that has a wide range of hosts including rodents, lagomorphs, carnivores, and primates (6) and the potential to affect multiple organs including the brain, kidneys, liver, heart, and lungs (36). *E. cuniculi* infection has been extensively explored in rabbits (26), in which under normal immunological conditions it produces only chronic asymptomatic brain and kidney lesions (37). The choice of this parasite is not capricious. There is increasing evidence that members of the order Microsporida (genera *Nosema*, *Enterocytozoon*, *Pleistophora*, and *Encephalitozoon*) may become important pathogens for immunosuppressed individuals, including AIDS patients (for reviews, see references 5 and 35).

MATERIALS AND METHODS

Organisms. *E. cuniculi* was grown in primary rabbit embryo fibroblast cultures in minimal essential medium and 5% fetal calf serum as previously described (37). The organisms used for inoculation of rabbits were freshly collected from culture supernatants after centrifugation at $400 \times g$ for 30 min. After two washes in sterile phosphate-buffered saline (PBS), the organisms were resuspended in PBS, counted in a hemacytometer, and adjusted to the desired concentration.

Animal treatment and infection. Adult (5 to 6 months old) male New York State giant Flemish rabbits from a closed colony raised at our center since 1935 were used for these experiments. The animals were free of *Coccidia*, *Pasteurella*, and *E. cuniculi* infections. Three groups of eight rabbits each were submitted to five colonic enemas (30 ml of Fleet formula) per week for a period of 3 months as previously reported (43). Three groups containing a similar number of animals were not manipulated. After that period, manipulated (60 to 90 min after colonic lavage) and nonmanipulated animals were inoculated i.r. with 5×10^3 , 5×10^5 , or 5×10^7 *E. cuniculi*. The various doses of the parasite were given in a single 1-ml volume deposited in the rectum with a

* Corresponding author.

3 1/2 Fr. Tom Cat catheter (Sherwood Medical, St. Louis, Mo.) to a depth of approximately 5 cm. Colonic lavages were discontinued after infection. The rabbits were bled before and periodically after inoculation. Four animals in each experimental group and two age-matched uninfected controls were sacrificed by intravenous (i.v.) injection of 1 ml of sodium pentobarbital (Somlethol; J. A. Webster, Inc., North Billerica, Mass.) 2 months postinfection, and the remaining experimental animals and five noninfected controls were sacrificed approximately 4 months postinfection.

Animal procedures have been approved by the Institutional Animal Care and Use Committee of the Wadsworth Center for Laboratories and Research.

Histopathology. Tissue samples of the brain, liver, kidney, lung, and intestine were fixed in 10% neutral buffered formalin. Tissue blocks were embedded in paraffin, and sections were stained with hematoxylin and eosin. Lesions were evaluated microscopically according to the following grading system: \pm , very mild; +, mild; $+\pm$, mild to moderate; ++, moderate; $++\pm$, moderate to severe; and +++, severe. Gram stain was applied to tissue sections with lesions to search for organisms.

Immunologic techniques. (i) **Dot-ELISA.** Serum samples and positive and negative controls were serially diluted and examined in duplicate in an enzyme-linked immunosorbent assay (ELISA) (27), using dots of formalin-fixed *E. cuniculi*. The dots were developed with horseradish peroxidase-conjugated goat anti-rabbit immunoglobulin G (IgG) (Zymed Laboratories, San Francisco, Calif.) and H_2O_2 . The technique has been described elsewhere in detail (3). Serum dilutions causing the development of clearly defined dark blue dots were considered positive. The endpoint titer was the last dilution giving a positive reaction.

(ii) **Determination of immunoglobulin isotypes.** Immunoglobulin isotypes were measured in heat-inactivated serum samples by an indirect immunofluorescence test done on custom-made glass slides bearing acetone-fixed parasites in small wells (5×10^5 spores per well) as previously described (33). Optimal dilutions of fluorescein isothiocyanate-conjugated goat anti-rabbit IgA, IgG, or IgM (Nordic Immunological Laboratory, Capistrano Beach, Calif.) were used as the second antibody. The endpoint titer was defined as the highest dilution giving positive fluorescence for at least 50% of the organisms.

(iii) **Detection of circulating immune complexes (CIC).** The C1q solid-phase assay specific for each rabbit isotype was performed as previously described (2). The results of these assays were expressed as the standard deviations (SD) above the mean of 10 control sera from normal rabbits.

(iv) **Purification and dissociation of immune complexes.** Immune complexes were precipitated from selected sera as reported previously (34). Briefly, 100 μ l of 7% polyethylene glycol (PEG 6000) in 0.1 M borate buffer, pH 8.4, was added to 100 μ l of each specimen and the admixtures were incubated overnight at 4°C. After centrifugation at 3,000 rpm ($1,850 \times g$) for 15 min, supernatant fluids were discarded and pellets were washed twice with 3.5% PEG-borate buffer before their final resuspension in 100 μ l of 0.1 M sodium borate, pH 10.2, to yield dissociated immune complexes (DIC).

(v) **Analysis of immune complex components by Western blot (immunoblot): identification of antigen.** Alkaline-dissociated immune complexes were mixed with an equal volume of sample buffer boiled for 5 min, and a 25- μ l volume was subjected to discontinuous 10% sodium dodecyl sulfate-polyacrylamide gel electrophoresis (SDS-PAGE). Resolved

proteins were then electrophoretically transferred to nitrocellulose paper at 100 V and 220 mA for 1 h in 25 mM Tris-192 mM glycine-20% methanol by using a Mini-Trans-blot (Bio-Rad Laboratories, Richmond, Calif.). After a blocking step with 1% bovine serum albumin (BSA) in PBS containing 0.02% Tween 20 (PBS-T) for 1 h, the blots were reacted overnight (18 h) at room temperature with rabbit anti-*E. cuniculi* serum (dot-ELISA titer, 1:10,240) at a dilution of 1:100. After several washes with PBS-T, the blots were probed with the second antibody, horseradish peroxidase-conjugated goat anti-rabbit IgG, and finally developed with H_2O_2 and 4-chloro-1-naphthol (HRP-Color Developer; Bio-Rad) according to the recommendation of the manufacturer. Controls included PEG-precipitated material from preinfection samples and normal rabbits. Molecular weight standards (Bio-Rad) were run in parallel, and the M_r s of the polypeptides were calculated (42).

(vi) **Identification of antibodies.** Solubilized *E. cuniculi* polypeptides were obtained by a modification of the method reported by Irby et al. (15). Briefly, three-times-washed spores (10^8) in PBS were spun down and the pellet was resuspended in 0.1 ml of 1% Triton X-100 and boiled for 10 min, after which 0.4 ml of sample buffer containing 2% SDS and 5% β -mercaptoethanol in 0.06% M Tris-HCl buffer, pH 6.8, was added and the mixture was boiled again for another 10 min. A volume of 135 μ l of solubilized antigen (2.7×10^7 spores) was added to individual preparative 10% SDS-PAGE slab minigels. Following electrophoresis, proteins were transferred to nitrocellulose paper for identification of possible anti-*E. cuniculi* antibodies in DIC. Sheets were cut into separate strips, and duplicate strips were incubated overnight with the DIC obtained from infected and noninfected control animals (20 μ l diluted in 2 ml of PBS-T). As additional controls, duplicate strips were stained with amido black or incubated with rabbit anti-*E. cuniculi* antiserum at a 1:100 dilution. After a series of 10-min washes, each pair of strips was reacted with the second antibody, horseradish peroxidase-conjugated anti-rabbit IgA or IgG (Fc specific; Nordic), and developed as described above.

(vii) **Statistical analysis.** The Student *t* test was used to measure the significance of differences between sample means obtained by dot-ELISA.

RESULTS

Fecal cultures and histopathological examination of tissues obtained from animals taken at random from our colony indicated that they were free of *Coccidia* and *Pasteurella* infections. Repeated examination by indirect immunofluorescence testing of serum samples taken from all rabbits prior to their inclusion in the experiments indicated that the animals were also free of *E. cuniculi* infection (titers, $<1:10$).

Antibody response. The time of appearance and the level of antibodies were dose associated. Antibodies were detectable by dot-ELISA 15 days after infection with 5×10^7 and 5×10^5 organisms and 30 days after infection with 5×10^3 organisms (Fig. 1). Long-term treatment with colonic lavages prior to infection apparently has an adverse effect on the translocation of the pathogen in animals infected with the lowest dose of organisms. Thus, in the third month of infection at the peak of the humoral response, the mean antibody titer for manipulated animals was 1:320, and for the nonmanipulated group it was 1:5,121 ($P < 0.01$). In the former group infected with the lowest dose of parasite, production of IgA and IgG antibodies as detected by indirect immunofluorescence was delayed for approximately 3

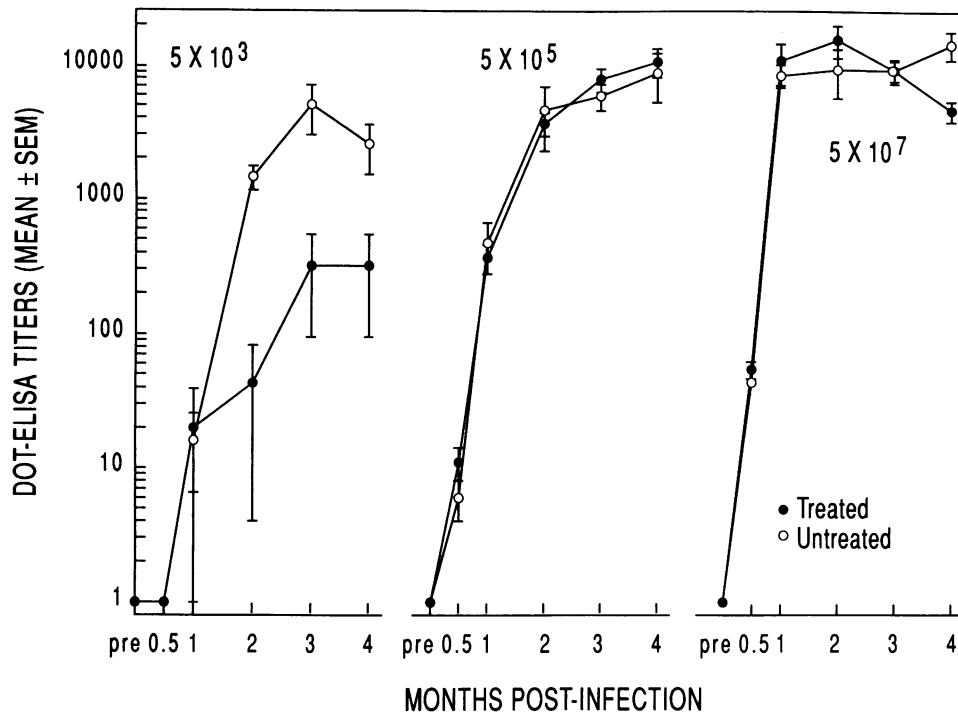


FIG. 1. Humoral response in *E. cuniculi*-infected rabbits with (●) and without (○) prior colonic lavages. Serum samples were screened at 1:10, 1:100, and 1:1,000 dilutions and then titrated in duplicate in twofold dilutions. The interference of enemas with the intestinal translocation of the parasite and consequently the humoral response is evident only in the animals injected with the lower dose (5×10^3).

months, whereas IgM antibodies were undetectable throughout the experimental period (data not shown). No substantial differences were observed between manipulated and nonmanipulated animals infected with the two higher doses.

In unmanipulated animals infected with the highest dose of *E. cuniculi*, levels of CIC were substantially higher and noted much earlier than CIC in the manipulated group (Table 1). Immune complexes, as detected by the C1q solid-phase assay, consisted of *E. cuniculi* antigens and antibodies of IgA (22 sera), IgG (9 sera), or IgM (1 serum) isotypes. Except for 1 pretreatment sample with a barely detectable level of CIC of the IgA and IgG isotypes (2.96 and 2.19 SD, respectively), the remaining 15 pretreatment samples were negative.

Identification of CIC components. Precipitated CIC and DIC obtained from sera of enema-treated animals 60 days postinfection and from nonmanipulated animals preinfection and 15 and 30 days postinfection were analyzed by Western blot. The reactivity of rabbit anti-*E. cuniculi* serum with antigens present in the purified CIC of individual samples varied with respect to the number of reactive peptides (data not shown). Precise determination of molecular masses of antigens in DIC was not attempted since there seem to be some changes in the peptides' electrophoretic charges possibly associated with the alkaline medium (pH 10.2) used for the dissociation of CIC. The antiserum used as a probe in the immunoblot was a pool of serum samples obtained in our laboratory from a 4-month i.r. infected rabbit with a dot-ELISA titer of 1:10,240 reacting with 14 to 15 *E. cuniculi* peptides with molecular masses of 16 to 97 kDa.

Antibodies present in the DIC reacted with blots of *E. cuniculi* (Fig. 2). The degree of reactivity depended on the time of infection as shown in the nonmanipulated group. Nine or 10 *E. cuniculi* peptides with molecular masses ranging from 15 to 47 kDa reacted with the antibodies.

Although the immunoglobulins in the CIC appeared to be predominantly of the IgA isotype, the immunoglobulin from the DIC that reacted with blots of *E. cuniculi* antigens was IgG rather than IgA. Material prepared by a similar procedure with serum samples obtained either from animals prior to infection or from uninfected normal controls were all negative for antigen and antibody (data not shown).

TABLE 1. CIC in rabbits infected with 5×10^7 *E. cuniculi*

Preinfection treatment and rabbit	CIC at days postinfection ^a :							
	15		30		60		90	
	IgA	IgG	IgA	IgG	IgA	IgG	IgA	IgG
Manipulated								
17	<2	<2	<2	<2	<2	4.5	<2	<2
18	<2	<2	<2	<2	4.3	<2	<2	<2
19	<2	<2	<2	<2	4.2	<2	<2	<2
20	<2	<2	<2	<2	3.4	3.6	3.1	<2
21	<2	6.6	<2	8.2	<2	2.1	<2	<2
22	<2	<2	<2	<2	<2	<2	<2	<2
23	<2	<2	<2	<2	3.3	<2	7.0	<2
24	<2	<2	<2	<2	<2	<2	3.2	<2
Nonmanipulated								
41	<2	<2	<2	<2	4.3	<2	<2	<2
42	<2	<2	<2	2.6	<2	<2	<2	<2
43	3.3	2.2	3.3	<2	<2	<2	<2	<2
44	2.5	<2	10.7	<2	<2	<2	<2	<2
45	3.6	<2	5.15	<2	<2	<2	<2	<2
46	<2	<2	11.0	<2	3.9	<2	3.7	<2
47	5.5	<2	7.6	2.2	12.8	2.6	<2	<2
49	<2	<2	6.0	<2	<2	<2	3.7	<2

^a CIC data are expressed as the number of SD above the mean of 10 normal sera.

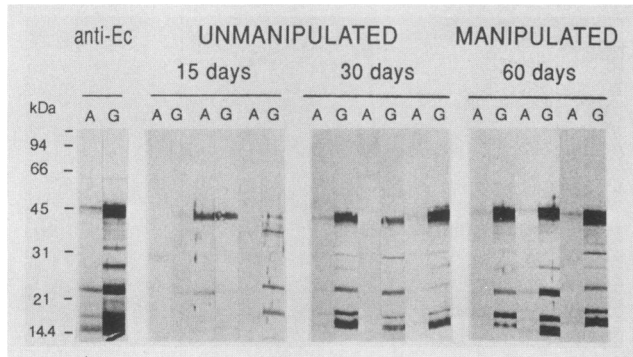


FIG. 2. Analysis of DIC by immunoblot in rabbits infected with 5×10^7 organisms. Blots of *E. cuniculi* were reacted with the dissociated material, washed, and probed with horseradish peroxidase-conjugated goat anti-rabbit IgA (lanes A) or goat anti-rabbit IgG (lanes G). Antibodies reacting with *E. cuniculi* peptides of molecular masses from 15 to 47 kDa appeared earlier in unmanipulated than in manipulated animals. Molecular mass standards and *E. cuniculi* reactions with control rabbit immune serum (anti-Ec) are shown on the left.

Histopathology. The frequencies of lesions in various organs from animals killed 2 and 4 months postinfection are presented in Tables 2 and 3.

At 60 days after inoculation, microscopic lesions compatible with encephalitozoonosis were seen in the livers, kidneys, and lungs from all four rabbits in each experimental group. There was a positive, dose-dependent increase in the severity of the lesions. In all instances, nonmanipulated rabbits had more severe lesions than manipulated rabbits given the same dose of parasites. Brain lesions occurred in three of four nonmanipulated rabbits in each dose group but in only one of four rabbits in each manipulated group. No dose-related increase in severity of brain lesions was noted.

At 120 days after infection, lesions were seen in the livers and kidneys from both rabbits in each group except that the liver of one nonmanipulated rabbit given 5×10^3 parasites was normal. Lungs from both manipulated rabbits given 5×10^3 parasites were normal, as were the lungs from one of the two manipulated rabbits given 5×10^5 parasites. Liver, kidney, and lung lesions were more severe in rabbits given larger loses of parasites. Again, nonmanipulated rabbits had more severe lesions than manipulated rabbits given the same dose. Brain lesions occurred in all nonmanipulated rabbits given 5×10^5 or 5×10^7 parasites, one of two nonmanipulated rabbits given 5×10^3 parasites, and one of two manipulated rabbits given 5×10^7 parasites. There was no relationship between dose or manipulation and severity of brain lesions.

Controls were free of lesions except for mild perivascular lymphoid infiltrates in the lungs of two rabbits.

Histological examination of affected livers revealed mild-to-moderate periportal mononuclear cell infiltration by lymphocytes, plasma cells, and epithelioid cells, with variable numbers of eosinophils. Individual cell necrosis and sinusoidal eosinophils were observed in moderate and severe lesions. Renal lesions were characterized by mild-to-moderate tubular degeneration and diffuse interstitial mononuclear infiltration by lymphocytes, plasma cells, and macrophages. Lesions in the brain consisted of mild nonsuppurative meningitis and perivascular cuffs of lymphocytes and plasma cells. Very mild focal gliosis and small foci of necrosis surrounded by epithelioid cells, with fewer numbers of

TABLE 2. Frequency of experimental encephalitozoonosis-compatible lesions in animals sacrificed 60 days postinfection

Preinfection treatment and rabbit	Infection dose (no. of organisms)	Lesion frequency in ^a :			
		Liver	Kidney	Lung	Brain
Manipulated					
1	5×10^3	±	±	±	—
2	5×10^3	+	±	±	—
3	5×10^3	+	±	±	—
4	5×10^3	+	±	±	±
Nonmanipulated					
25	5×10^3	++	++	±	—
26	5×10^3	±	++	+	±
27	5×10^3	++	++	+	±
28	5×10^3	±	++	+±	±
Manipulated					
9	5×10^5	++	+	±	—
10	5×10^5	+	+	±	—
11	5×10^5	++	+	±	—
12	5×10^5	+±	+	±	±
Nonmanipulated					
33	5×10^5	++	+±	+±	+
35	5×10^5	++	++	+±	±
36	5×10^5	++	++	+±	+
37	5×10^5	++	++	±	—
Manipulated					
17	5×10^7	++	++	±	—
18	5×10^7	++	++±	+	±
19	5×10^7	++	++	+±	—
20	5×10^7	++	++	+	—
Nonmanipulated					
41	5×10^7	++	+±	+	—
42	5×10^7	++	++	±	±
43	5×10^7	++	+	±	±
44	5×10^7	++	++	+	+
Control					
139		—	—	—	—
140		—	—	+	—

^a Lesions were evaluated microscopically as follows: ±, very mild; +, mild; +±, mild to moderate; ++, moderate; ++±, moderate to severe; and +++, severe.

lymphocytes and plasma cells, were seen in two rabbits infected 60 days earlier with the highest dose (5×10^7). Lung lesions consisted of very-mild-to-moderate perivascular mixed inflammatory infiltration by lymphocytes, plasma cells, and eosinophils, with occasional areas of focally extensive interstitial pneumonia. No lesions that could be attributed to *E. cuniculi* were seen in the intestine. A focal area of nonsuppurative perivascular inflammatory infiltration was observed in two nonmanipulated, noninfected controls.

DISCUSSION

The present studies indicated (i) that the anorectal mucosa is a suitable portal of entry for systemic infection with the microsporidium *E. cuniculi*; (ii) that rabbits infected i.r. had a relatively higher incidence of lesions of the liver, kidney, and lung compared with the brain; and (iii) that there was a significant production of CIC composed of specific antigens and antibodies.

TABLE 3. Frequency of experimental encephalitozoonosis-compatible lesions in animals sacrificed 120 days postinfection

Preinfection treatment and rabbit	Infection dose (no. of organisms)	Lesion frequency in ^a :			
		Liver	Kidney	Lung	Brain
Manipulated					
6	5×10^3	+	+	-	-
8	5×10^3	++	+±	-	-
Nonmanipulated					
30	5×10^3	-	+	±	-
32	5×10^3	±	+	±	±
Manipulated					
14	5×10^5	++	+	-	-
16	5×10^5	++	+	+	-
Nonmanipulated					
38	5×10^5	+++	+	±	+
40	5×10^5	++	++	+	±
Manipulated					
22	5×10^7	++	++	+	+
24	5×10^7	++	+	+	-
Nonmanipulated					
46	5×10^7	++	++	+±	±
49	5×10^7	++	+±	+±	±
Control					
145		-	-	-	-
146		-	-	-	-
147		-	-	±	-
148		-	-	-	-
149		-	-	-	-

^a See Table 2, footnote a.

The selection of three infective doses was rewarding. Signs of interference in the translocation of the parasite by colonic lavages was serologically and histopathologically evident in the animals infected with the lowest dose, although eventually both groups became infected. Apparently, doses of 5×10^5 and 5×10^7 organisms were sufficient to overcome such a discrimination, though the onset and levels of CIC for the latter group pointed to the same conclusion. Cox et al. (9) described successful intravenous (i.v.), intragastric (i.g.), and intratracheal (i.t.) infection of rabbits with 4×10^3 focus-forming units (each focus represented a single infectious unit when the parasite was assayed in CLS 300 cell culture) with antibodies developing 15 days postinfection. Other routes including intracerebral and intraperitoneal have been used for experimental infection with *E. cuniculi* (33, 37). To our knowledge, however, this is the first attempt in which the anorectal mucosa has been used as a site of infection with a microsporidium. It proved to be as effective as the i.g. route (9), even though one cannot be certain of the exact number of organisms effectively penetrating the host's enteric mucosa.

Natural transmission of *E. cuniculi* in animals is thought to occur either by horizontal (maternal) or vertical transmission by ingestion of infected excreta (8, 28). Reports of human infection with four different genera of microsporidia (5, 35) suggest that these microorganisms are a source of either latent or opportunistic infection in humans.

The present data differ from our previous results. In previous studies, prior colonic lavages significantly en-

hanced the rate of intestinal penetration of immunogenic noninfectious soluble (seminal fluid and BSA) or particulate (spermatozoa and intact or sonicated sheep erythrocytes [43, 44]) antigens. In those studies, enemas most likely affected or removed a protective mechanism(s) which normally prevents the passage of macromolecules through the colonic mucosa (23). Host-parasite interactions, however, pose special problems that are not encountered when studying responses to inert antigens.

We do not have direct evidence of the mechanism(s) delaying the translocation of the parasite *E. cuniculi* in enema-treated animals, though an explanation may be found in its life cycle and in factors influencing its infectivity and reproduction. *E. cuniculi* is a unicellular parasite that develops within a parasitophorous vacuole in endothelial cells and macrophages. Large numbers of small spores (2.5 μ m) are produced. The spores have thick walls composed of a chitinous endospore and a proteinaceous exospore enclosing a cytoplasm and the infective sporoplasm, which can be released from a spore by extrusion of a long polar filament. When infecting a new host, the polar filament everts and the sporoplasm is ejected (26). If the tip is successful in penetrating the plasma membrane of the host cell, inoculation of the sporoplasm into the cytoplasm ensues. In this way, *E. cuniculi* may infect phagocytic and nonphagocytic cells. For this to occur, however, a set of stimuli that are not known for *E. cuniculi*, but which might include alkaline pH, optimal concentration of various ions, or even digestive enzymes acting alone or in combination, are needed to provoke the intake of water by the spore to increase the intrasporal pressure, initiate the germination process, and release the infectious sporoplasm through the polar filament (40).

In our studies, colonic lavages with Fleet formula enema (19 g of NaH_2PO_4 and 7 g of Na_3PO_4 in 110 ml of water) containing a hypertonic solution of monobasic and neutral sodium phosphate, by increasing the local osmotic pressure of the intestinal environment, may have prevented water movement into the spores to complete the hatching process, thus interfering with the infection. Alternatively, in the unmanipulated animals, the trapping mechanisms provided by mucoid material and digestive enzymes with potential capability to accelerate the spore hatching (40) and subsequent infectivity may account for the relatively accelerated rate of infection.

Unlike other routes of experimental infection in rabbits, the i.r. route produced a relatively high frequency of lesions in the liver and kidney, although the brain also was affected. Lesions in the liver presumably due to *E. cuniculi* have been described previously in animals (25, 46), but the parasite was not demonstrated in the liver. Cox et al. (9), by using the i.v., i.g., and i.t. routes for infection, observed lesions in the liver but to a lesser extent than in the present study. Regardless of the route of infection, Cox et al. (9) found that the frequency of lesions was higher in the kidney and lung than in the liver and heart.

Human infection with *E. cuniculi* has been diagnosed in two children with neurological illnesses but not notably immunocompromised (4, 19). More recently, two fatal human cases have been reported in AIDS patients. Terada et al. (39) reported hepatic infection with *E. cuniculi* associated with granulomatous, suppurative, hepatocellular necrosis in a male homosexual, and Zender et al. (47) reported a case of *E. cuniculi* peritonitis in a 45-year-old man who denied drug addiction or being homosexual. In both cases, the parasites were identified by special stains and electron microscopy.

Significant levels of CIC composed of *E. cuniculi* polypep-

tides and predominantly IgA antibodies were detected in both manipulated and nonmanipulated groups. The latter finding was both surprising and unexpected, as C1q does not react with complexes containing non-complement-activating antibodies or those which activate complement preferentially via the alternative pathway such as IgA and IgE CIC. The most likely explanation for these findings is that the anti-IgA antibodies used in development of the assay were actually detecting complexes composed of IgA rheumatoid factors or IgA anti-idiotypic antibodies complexed with IgG. In this regard, interference by rheumatoid factors is the primary disadvantage associated with solid-phase C1q-binding assays. Alternatively, the assay may have detected IgA complexed with a multivalent parasite antigen and other immunoglobulin isotypes. If the assay was in fact detecting IgA rheumatoid factors complexed with IgG, this would explain the apparent discrepancy as to why IgG, rather than IgA, in DIC reacted preferentially with blots of *E. cuniculi* antigen.

In the nonmanipulated group, IgA CIC appeared as early as 15 days and were still present after 3 months of infection. Although the deposition of immune complexes has been implied as the cause of the perivascular inflammation in various organs in natural (24, 41) and experimental (21) encephalitozoonosis, to our knowledge this is the first time that direct evidence of CIC is provided.

It is reasonable to assume that soluble CIC containing antigen and endogenously produced antibodies might have biologic consequences leading to damage of the organs involved. Vasculitis and perivasculitis in many organs may lead to renal injury, central nervous system abnormalities, arthritis, and fever, as has been reported in microsporidian infection of animals (26) and humans (4, 32). Obviously, in the various situations, the complement-binding capability of the antibody isotype (IgM > IgG3 > IgG1 > IgG2 in humans [12]) by activation of the complement cascade and release of its by-products will determine the nature and severity of the lesions.

E. cuniculi antigenic polypeptides and antibodies against 9 or 10 homologous peptides were present in DIC. Immune complexes and antibodies were undetectable in normal animals or preinfection serum samples. Thus, the humoral response seems to be specifically triggered by the infection.

Because the microsporidia are so small and difficult or impossible to identify in routine hematoxylin-eosin-stained tissue sections, there is a great need for a readily available qualitative test capable of discriminating between specific and cross-reacting antibodies (14, 15). The above findings may be clinically relevant in humans, since there are several reports describing human enteric and hepatic infections with microsporidia (5, 32, 35, 39, 47). There are also high levels of CIC (11) in homosexual men with or without AIDS, which are, as yet, unexplained.

ACKNOWLEDGMENTS

The authors thank Murray King for helpful editorial comments and Kathy Ruth for secretarial help.

This study was supported by NIH AIDS grant AI-25703 from the National Institute of Allergy and Infectious Diseases, U.S. Public Health Service.

REFERENCES

- Archer, D. L., and W. H. Glinsmann. 1985. Enteric infections and other cofactors in AIDS. *Immunol. Today* 6:292-295.
- Baughn, R. E., C. M. McNeely, J. L. Jorizzo, and D. M. Musher. 1986. Characterization of the antigenic determinants and host components in immune complexes from patients with secondary syphilis. *J. Immunol.* 136:1406-1414.
- Beckwith, C., N. Peterson, J. J. Liu, and J. A. Shadduck. 1988. Dot enzyme-linked immunosorbent assay (Dot ELISA) for antibodies to *Encephalitozoon cuniculi*. *Lab. Anim. Sci.* 38:573-576.
- Bergquist, N. R., G. Stintzing, L. Smedman, T. Waller, and T. Andersson. 1984. Diagnosis of encephalitozoonosis in man by serological test. *Br. Med. J.* 288:902.
- Canning, E. U., and W. S. Hollister. 1987. Microsporidia of mammals—widespread pathogens or opportunistic curiosities? *Parasitol. Today* 3:267-273.
- Canning, E. U., and J. Lom. 1986. The microsporidia of vertebrates. Academic Press, Inc., New York.
- Coffey, R. J., T. B. Addison, J. T. Lie, and F. R. Cockerill. 1986. Acquired immune deficiency syndrome (AIDS): liver involvement with *Cryptococcus neoformans* as presenting manifestation of disseminated cryptococcosis, and a review of hepatic diseases in male homosexuals. *Intern. Med.* 7:53-66.
- Cox, J. C., H. A. Gallichio, D. Pye, and N. B. Walden. 1977. Application of immunofluorescence to the establishment of an *Encephalitozoon cuniculi*-free rabbit colony. *Lab. Anim. Sci.* 27:204-209.
- Cox, J. C., R. Hamilton, and A. D. Attwood. 1979. An investigation of the route and progression of *Encephalitozoon cuniculi* infection in adult rabbits. *J. Protozool.* 26:260-265.
- Dritz, S. K., and R. S. Goldsmith. 1980. Sexually transmissible protozoal, bacterial and viral enteric infections. *Compr. Ther.* 6:34-40.
- Euler, H. H., P. Kern, H. Löffler, and M. Dietrich. 1985. Precipitable immune complexes in healthy homosexual men, acquired immune deficiency and the related lymphadenopathy syndrome. *Clin. Exp. Immunol.* 59:267-275.
- Golub, E. S. 1987. Immunology: a synthesis, p. 60. Sinauer Associates, Inc., Sunderland, Mass.
- Gordon, S. C., K. R. Reddy, E. E. Gould, R. McFadden, C. O'Brien, M. de Medina, L. J. Jeffers, and E. R. Schiff. 1986. The spectrum of liver disease in the acquired immune deficiency syndrome. *J. Hepatol.* 2:475-484.
- Hollister, W. S., and E. U. Canning. 1987. An enzyme-linked immunosorbent assay (ELISA) for detection of antibodies to *Encephalitozoon cuniculi* and its use in determination of infection in man. *Parasitology* 94:209-219.
- Irby, W. S., Y. S. Huang, C. Y. Kawanishi, and W. M. Brooks. 1986. Immunoblot analysis of exospore polypeptides from some entomophilic microsporidia. *J. Protozool.* 33:14-20.
- Kazal, H. L., N. Sohn, J. I. Carrasco, J. G. Robilotti, Jr., and W. E. Delaney. 1976. The gay bowel syndrome: clinico-pathologic correlation in 260 cases. *Ann. Clin. Lab. Sci.* 6:184-192.
- Kingsley, L. A., R. Kaslow, C. R. Rinaldo, K. Detre, N. Odaka, M. VanRaden, R. Detels, B. F. Polk, J. Chmiel, S. F. Kelsey, D. Ostrow, and B. Visscher. 1987. Risk factors for seroconversion to human immunodeficiency virus among male homosexuals. *Lancet* i:345-348.
- Kotler, D. P., H. P. Gaetz, M. Lange, E. B. Klein, and P. R. Holt. 1984. Enteropathy associated with the acquired immunodeficiency syndrome. *Ann. Intern. Med.* 101:421-428.
- Matsubayashi, H., T. Koike, I. Mikata, H. Takei, and S. Hagiwara. 1959. A case of *Encephalitozoon*-like body infection in man. *Arch. Pathol.* 67:181-187.
- Mildvan, D., A. M. Gelb, and D. William. 1977. Venereal transmission of enteric pathogens in male homosexuals. *J. Am. Med. Assoc.* 238:1387-1390.
- Mohn, S. F. 1982. Experimental encephalitozoonosis in the blue fox. *Acta Vet. Scand.* 23:503-514.
- Multicenter AIDS Cohort Study (MACS). 1985. Prevalence and correlation of HTLV-III antibodies among 5,000 gay men in 4 cities. Program Abstr. 25th Intersci. Conf. Antimicrob. Agents Chemother., abstr. 740.
- Nicklin, S. 1987. Intestinal uptake of antigen. Immunological consequences, p. 87-108. In C. Miller and S. Nicklen (ed.), *Immunology of the gastrointestinal tract*, vol. I. CRC Press, Boca Raton, Fla.

24. Nordstoga, K., and K. R. Westbye. 1976. Polyarteritis nodosa associated with nosematosis in blue foxes. *Acta Pathol. Microbiol. Scand. Sect. A* **84**:291-296.
25. Ophuls, W. 1910. Occurrence of spontaneous lesions in kidneys and livers of rabbit and guinea pigs. *Proc. Soc. Exp. Biol. Med.* **8**:75-77.
26. Pakes, S. P. 1974. Protozoal diseases, p. 273-278 *In* S. H. Weisbroth, R. E. Flatt, and A. L. Kraus (ed.), *Biology of the laboratory rabbit*. Academic Press, Inc., New York.
27. Pappas, M. G., R. Hajkowski, and W. T. Hockmeyer. 1984. Standardization of the dot-enzyme-linked immunosorbent assay (dot-ELISA) for human visceral leishmaniasis. *Am. Soc. Trop. Med. Hyg.* **33**:1105-1111.
28. Pye, D., and J. C. Cox. 1977. Isolation of *Encephalitozoon cuniculi* from urine samples. *J. Protozool.* **11**:233-234.
29. Quinn, T. C., P. Plot, J. B. McCormick, F. M. Feinsod, H. Taelman, B. Kapita, W. Stevens, and A. S. Fauci. 1987. Serologic and immunologic studies in patients with AIDS in North America and Africa. The potential role of infectious agents as co-factors in human immunodeficiency virus infection. *J. Am. Med. Assoc.* **257**:2617-2621.
30. Quinn, T. C., W. E. Stamm, E. G. Steven, E. Mkrtychian, J. Benedetti, L. Corey, M. S. Schuffler, and K. K. Holmes. 1983. The polymicrobial origin of intestinal infections in homosexual men. *N. Engl. J. Med.* **309**:576-582.
31. Richards, T. M., J. M. Bedford, and S. S. Witkin. 1984. Rectal insemination modifies immune response in rabbits. *Science* **224**:390-392.
32. Rijpstra, A. C., E. U. Canning, R. J. van Ketel, J. K. M. Eeftimck Schattenkerk, and J. J. Laarman. 1988. Use of light microscopy to diagnose small-intestinal microsporidiosis in patients with AIDS. *J. Infect. Dis.* **157**:827-831.
33. Schmidt, E. C., and J. A. Shadduck. 1983. Murine encephalitozoonosis model for studying the host-parasite relationship of a chronic infection. *Infect. Immun.* **40**:936-942.
34. Schutzer, S. E., P. K. Coyle, A. L. Belman, M. G. Golightly, and J. Drulle. 1990. Sequestration of antibody to *Borrelia burgdorferi* in immune complexes in seronegative Lyme disease. *Lancet* **335**:312-315.
35. Shadduck, J. A. 1989. Human microsporidiosis and AIDS. *Rev. Infect. Dis.* **11**:203-207.
36. Shadduck, J. A., and S. P. Pakes. 1971. Spontaneous diseases of laboratory animals which interfere with biomedical research: encephalitozoonosis (nosematosis) and toxoplasmosis. *Am. J. Pathol.* **64**:657-674.
37. Shadduck, J. A., W. T. Watson, S. P. Pakes, and A. Cali. 1979. Animal infectivity of *Encephalitozoon cuniculi*. *J. Parasitol.* **65**:123-129.
38. Szmunes, W., M. I. Much, A. M. Prince, J. H. Hoofnagle, C. E. Cherubin, E. J. Harley, and G. H. Block. 1975. On the role of sexual behavior in the spread of hepatitis B infection. *Ann. Intern. Med.* **83**:489-495.
39. Terada, S., K. R. Reddy, L. J. Jeffers, A. Cali, and E. R. Schiff. 1987. Microsporidian hepatitis in the acquired immunodeficiency syndrome. *Ann. Intern. Med.* **107**:61-62.
40. Undeen, A. H. 1978. Spore-hatching processes in some Nosema species with particular reference to *N. algerae* Vavra and Undeen. *Misc. Publ. Entomol. Soc. Am.* **11**:29-49.
41. Van Dellen, A. F., W. S. Botha, J. Boomker, and W. E. J. Warnes. 1978. Light and electron microscopical studies on canine encephalitozoonosis: cerebral vasculitis. *Onderstepoort J. Vet. Res.* **45**:165-186.
42. Weber, K. M., and M. Osborn. 1969. The reliability of molecular weight determinations by dodecyl sulfate-polyacrylamide gel electrophoresis. *J. Biol. Chem.* **244**:4406-4412.
43. Wicher, V., and K. Wicher. 1986. Immune response of rabbits to intrarectal injections of particulate and soluble antigens with and without enemas. *Clin. Immunol. Immunopathol.* **41**:443-452.
44. Wicher, V., and K. Wicher. 1986. Immune dysfunction in rabbits associated with chronic administration of enemas and rectal insemination. *AIDS Res.* **2**:289-298.
45. Wicher, V., K. Wicher, and B. Albini. 1984. Alteration of immune response induced by chronic intrarectal insemination in rabbits. *AIDS Res.* **1**:309-326.
46. Wright, J. H., and E. Craighead. 1922. Infectious motor paralysis in young rabbits. *J. Exp. Med.* **36**:135-140.
47. Zender, H. O., E. Arrigoni, J. Eckert, and Y. Kapanci. 1989. A case of *Encephalitozoon cuniculi* peritonitis in a patient with AIDS. *Am. J. Clin. Pathol.* **92**:352-356.