

STUDIES ON THE MOLECULAR EPIDEMIOLOGY, PATHOGENESIS,  
DIAGNOSIS AND TREATMENT OF AVIAN MYCOBACTERIOSIS

A Dissertation

by

MIGUEL DANIEL SAGGESE

Submitted to the Office of Graduate Studies of  
Texas A&M University  
in partial fulfillment of the requirements for the degree of

DOCTOR OF PHILOSOPHY

December 2007

Major Subject: Veterinary Microbiology

STUDIES ON THE MOLECULAR EPIDEMIOLOGY, PATHOGENESIS,  
DIAGNOSIS AND TREATMENT OF AVIAN MYCOBACTERIOSIS

A Dissertation

by

MIGUEL DANIEL SAGGESE

Submitted to the Office of Graduate Studies of  
Texas A&M University  
in partial fulfillment of the requirements for the degree of

DOCTOR OF PHILOSOPHY

Approved by:

|                         |                 |
|-------------------------|-----------------|
| Co-Chairs of Committee, | Ian Tizard      |
|                         | David N. Phalen |
| Committee Members,      | David McMurray  |
|                         | Luc Berghman    |
| Head of Department,     | Gerald Bratton  |

December 2007

Major Subject: Veterinary Microbiology

## ABSTRACT

Studies on the Molecular Epidemiology, Pathogenesis, Diagnosis and Treatment of

Avian Mycobacteriosis.

(December 2007)

Miguel Daniel Saggese, B.S, University of Buenos Aires;

M.S., University of Minnesota

Co-Chairs of Advisory Committee: Dr. Ian Tizard

Dr. David Phalen

We investigated the molecular epidemiology, differential susceptibility to infection and disease, pathogenesis, diagnosis and treatment of avian mycobacteriosis in captive ring-neck doves (*Streptopelia risoria*) and in the endangered white-winged duck (*Cairina scutulata*), both naturally infected with *Mycobacterium a. avium*. Our studies in doves demonstrated lower susceptibility to infection and less severity of lesions in the white color morph compared with the non-white. Genetic mechanisms of immunity to mycobacteriosis may be contributing or determining these differences. Given that the genes that code for white coloration are sex linked in birds, it is very likely that the gene or genes modulating this different immune response to *M. a. avium* infection in these doves could be associated to these loci or at least located in the same sexual (Z) chromosome, as the association with white color suggest.

In the same birds, spleen biopsies followed by liver biopsies had the greatest potential for the diagnosis of mycobacteriosis by the demonstration of acid-fast organisms. Additional

culturing of spleen or liver biopsies significantly increased the diagnosis of mycobacteriosis. The use of polymerase chain reaction (PCR) was the less sensitive techniques. Uneven distribution and low number of organisms in the liver, spleen and bone marrow may have contributed with the low diagnostic value of PCR.

In a second group of sixteen doves with mycobacteriosis from the same flock, the combination of azithromycine, ethambutol and rifampin for 180 days was well tolerated but failed to cure them. Furthermore, this study demonstrated the inefficacy of liver biopsy to evaluate treatment as well the presence of antibiotic resistance in two isolates. These results highlight that eradication of mycobacteriosis in birds is not easy to achieve. Together with the possible emergence of antibiotic resistance in potentially zoonotic mycobacteria our results suggest that the treatment of mycobacteriosis in birds should not be recommended.

Finally, the last study shows that white-winged ducks are highly susceptible to at least two sequevars of *M. a. avium* and that mycobacteriosis is a major threat to the *ex situ* conservation program. The minimal heterozygosis previously shown in these ducks could be contributing to this apparently ineffective immune response.

*I want to dedicate this dissertation to my lovely and supporting wife Stella Maris Galarza, and to my son Renzo D'Amore, for having been the "force", spiritual and emotional support, source of happiness and daily encouragement that ultimately allowed me to conduct this program and graduate study. Without their support, love and sacrifice leaving all behind in Argentina to share together this adventure, nothing would have been possible.*

## ACKNOWLEDGEMENTS

My graduate's studies and this dissertation were completed thanks to the enduring support of many people and I want to fully acknowledge all of them.

First, I would like to thank my co-chairs and main advisors, Drs. Ian Tizard and David Phalen, for their generous support, intellectual challenge and trust during all these three years at The Schubot Exotic Bird Health Center. Having it finished depended in big part on their permanent disposition to help whatever situation demanded it. My genuine gratitude to Dr. Ian Tizard, Professor and Director of The Schubot Exotic Bird Health Center, for his permanent support of all my research, work and outreach activities with birds of prey and for his absolute and permanent dedication and kindness to all his graduate students. I want to thank Dr. Phalen for introducing me in the fascinating, enjoyable and complex field of mycobacteriology. I am also very thankful to him for coming from as far as Australia to my final defense.

To my co-advisors, Dr. David McMurray and Dr. Luc Berghman, I am extremely grateful for their support, expertise, dedication and patience. They were always ready to go "the extra mile" to assist me in all moments with my research and with my dissertation. They made numerous contributions every time we met to discuss this project that improved enormously my research and also the manuscript.

I want thank and acknowledge many people that helped in many different aspects of this research. Special thanks to Drs. Darrel Styles and Elizabeth Tomaszewsky for introducing me to the field of molecular genetics. I also want to thank Darrel for his kind friendship. Ms. Debra Turner was essential in all the logistic aspects of my research, especially with the management and care of the doves and other species of birds used in this study. She was always present and contributed in uncountable ways to my research. Dr. Patricia Gray assisted and contributed with many aspects of this study and we shared many interesting discussions about the pathogenesis of mycobacteriosis during these years. I sincerely appreciate all her contributions to this study. Special thanks to Ken Turner for everything he does at the department.

This research received generous economic support from The Schubot Exotic Bird Health Center, Sylvan Heights Waterfowl Center, Association of Avian Veterinarians and Smokey Mountain Bird Club. To all them I am deeply grateful.

I want to thank Dr. Gerald Bratton, head of the department of veterinary pathobiology, for his continuous support to my graduate studies. Work under his direction was a pleasure. Dr. G. Bratton, Dr. Robert Taylor, Dr. Bryan Brattin and Ms Deborah Dooley were essential for the investigation of heavy metals in the white-winged ducks and they kindly introduced me to the techniques applied for investigating heavy metals concentration in tissues.

Special thanks to Taffik Omran, Dr. Melissa Libal, Dr. Karen Russel, Dr. J. Edwards, Dr. B. Wigle, Dr. Prasad, Dr. G. Gomez, Dr. G. Stoica and Dr. S. Vanhooser for their collaboration with the reading and interpretation of pathology slides. Special thanks to Rosemary Vollman, Sarah Jones and Chatali Murkheiji for the preparation of the histopathology slides.

I want to thank all the staff at the Department of Veterinary Pathobiology (Betty Suehs, Marilyn Rubach, Dana Cornett, Letisha Haddix, Francis Hicks, Stevie Bundie, Cindy Wolker, Sheryl Quinlan, Diane McLeary, Marcia Zemanek, Brayla Leighton, Patty Vychopen and Emy Welch) for all their help, friendship and support during these years. Working with all them was a really pleasure and a lot of fun.

Students Kerry Bowen, Allison Bradley, Kate Montgomery, Cameron Armstrong, Erin Sziy, Amy Gordon. Ashley Holuveck, Ashley Maxey, Karla Turbyfill, Jennifer Nell and Shelly Lovell collaborated taking care of the birds, assisting with their treatment and laboratory work. They did an excellent job.

Dr. B. Dalhaussen, Dr. G. Riggs, and Dr. B. O'Shea provided me with different samples that were extremely useful for my investigation. Additional samples were also provided by Dr. M. Garner, Dr. A. Wunschmann, Dr. T. Vinner and the Dallas Zoo.



I want to recognize and thanks all the graduate students I met in different courses at the Graduate School. What started as sharing a class or a lab, it ended as a wonderful friendship that hopefully will last forever. Lina Covaleda, Gina Lungu, Megan Schroeder, Cecilia Williams, Angela Arenas, Heriberto Rodriguez, Dharani Ajithdos and Ita Villanueva: sharing all these years with all you was a wonderful experience, both in life as in science.

As life is a continuum and not single or isolated episodes, I want to express my sincere acknowledgement to the University of Buenos Aires, University of Minnesota, The Raptor Center and students and colleagues at these kind institutions for their important contribution during previous years to my personal and professional life that helped me to reach this point in my career.

I want to thank my parents, Miguel and Ana, and my sister Claudia, for their encouragement and support while studying at the University of Buenos Aires to become a Veterinarian. Everything started there.

Finally, I want to thank and recognize my wife Stella and my son Renzo for all their support, patience, dedication, understanding, sacrifice and love during these years. They were always there and they will be always there for me. This is the most precious gift I have received in this life. Everything I did and everything I am is because you were there for me.

## TABLE OF CONTENTS

|  | Page |
|--|------|
| ABSTRACT .....   | iii  |
| DEDICATION .....   | iv   |
| ACKNOWLEDGEMENTS .....   | v    |
| TABLE OF CONTENTS .....  | x    |
| LIST OF FIGURES.....   | xii  |
| LIST OF TABLES .....   | xiii |
| CHAPTER  |      |
| I    INTRODUCTION.....   | 1    |
| II   MYCOBACTERIOSIS IN NATURALLY INFECTED<br>RING-NECK DOVES ( <i>STREPTOPELIA RISORIA</i> ): ASSOCIATION<br>OF FEATHER COLOR WITH SUSCEPTIBILITY TO INFECTION<br>AND DISEASE AND LESIONS TYPE.....                 | 3    |
| Introduction.....  | 3    |
| Materials and Methods.....   | 9    |
| Results.....   | 13   |
| Discussion.....  | 21   |
| III  COMPARISON OF SAMPLING METHODS AND DIAGNOSTIC<br>TECHNIQUES FOR THE DIAGNOSIS OF MYCOBACTERIOSIS IN<br>RING-NECK DOVES ( <i>STREPTOPELIA RISORIA</i> ).....   | 27   |
| Introduction.....  | 27   |
| Materials and Methods.....   | 31   |
| Results.....   | 36   |
| Discussion.....  | 40   |
| IV  EVALUATION OF MULTI-DRUG THERAPY WITH AZITHROMY-<br>CIN, RIFAMPIN AND ETHAMBUTOL FOR THE TREATMENT OF<br>RING-NECK DOVES ( <i>STREPTOPELIA RISORIA</i> ) NATURALLY IN-<br>FECTED WITH AVIAN MYCOBACTERIOSIS..... | 47   |

|  |     |
|--|-----|
| Introduction.....  | 47  |
| Materials and Methods.....   | 51  |
| Results.....   | 57  |
| Discussion.....  | 67  |
| <br>   |     |
| V CONCLUSION: GROSS AND MICROSCOPIC FINDINGS AND<br>INVESTIGATION OF THE AETIOPATHOGENESIS OF<br>MYCOBACTERIOSIS IN A CAPTIVE POPULATION OF WHITE-<br>WINGED DUCKS ( <i>CAIRINA SCUTULATA</i> )..... | 72  |
| <br>   |     |
| Introduction.....  | 72  |
| Materials and Methods.....   | 74  |
| Results.....   | 77  |
| Discussion.....  | 85  |
| <br>   |     |
| REFERENCES .....   | 93  |
| <br>   |     |
| APPENDIX.....  | 118 |
| <br>   |     |
| VITA.....  | 119 |

## LIST OF FIGURES

| FIGURE   | Page |
|--|------|
| 2.1 Severe hepatomegaly and orange-tan discoloration in a non-white ring-neck dove with mycobacteriosis. ....  | 14   |
| 2.2 Moderate hepatomegaly and multifocal hepatic granulomas in a white ring-neck dove with avian mycobacteriosis. ....   | 15   |
| 2.3 Prevalence of microscopic lesions in white and non-white diseased ring-neck doves ( <i>Streptopelia risoria</i> ). ....  | 16   |
| 2.4 Multifocal hepatitis characterized by lymphocytic and histiocytic infiltrates in a white ring-neck dove. ....  | 17   |
| 2.5 Severe diffuse granulomatous hepatitis and infiltrates of amyloid in the parenchyma in a non-white ring-neck dove. ....  | 18   |
| 4.1 Survival rate of sixteen ringed-turtle doves ( <i>Streptopelia risoria</i> ) with spontaneous mycobacteriosis receiving azithromycin, ethambutol and rifampin for six months. .... | 58   |
| 4.2 Mild splenomegaly in a ring-neck doves ( <i>Streptopelia risoria</i> ) after six months of treatment. ....   | 62   |
| 4.3 Head and infra-orbital subcutaneous granulomatous lesions in a ring-neck dove ( <i>Streptopelia risoria</i> ) after six months of treatment. ....                                  | 63   |
| 4.4 Mild active-chronic granulomatous hepatitis. ....  | 65   |
| 5.1 Severe diffuse fibrinous air sacculitis and several multifocal to coalescing granulomatous pneumonia. ....   | 78   |
| 5.2 Severe diffuse fibrinous tracheitis. ....  | 79   |
| 5.3 Severe diffuse fibrinous tracheitis with complete effacement of the mucosal epithelium. ....   | 83   |

## LIST OF TABLES

| TABLE   | Page |
|---|------|
| 2.1 Prevalence of infection and diffuse and multifocal lesions in white and non-white ring-neck doves ( <i>Streptopelia risoria</i> ). .....  | 13   |
| 3.1 Comparison of sensitivity of different organ sampling and techniques for post-mortem confirmation of mycobacterial infection in 18 ring-neck doves ( <i>Streptopelia risoria</i> ). .....   | 37   |
| 3.2 Comparison of sensitivity of different organ sampling and techniques used for the diagnosis of mycobacteriosis in 18 ring-neck doves ( <i>Streptopelia risoria</i> ). .....   | 37   |
| 3.3 Sensitivity for duodenal aspirates samples for the diagnosis of mycobacteriosis in 18 ring-neck doves ( <i>Streptopelia risoria</i> ). .....  | 38   |
| 4.1 Comparison of sensitivity of different organ sampling and techniques used for the diagnosis of mycobacteriosis in 11 ring neck doves ( <i>Streptopelia risoria</i> ) with spontaneous mycobacteriosis and treated with azithromycin, ethambutol and rifampin for six months ..... | 60   |
| 5.1 Details results of examination of selected organs for macroscopic and microscopic lesions of avian mycobacteriosis in white-winged ducks ( <i>Cairina scutulata</i> ). .....  | 81   |
| 5.2 Microscopic findings in organs of white-winged ducks ( <i>Cairina scutulata</i> ) with multi-focal granulomatous inflammation. ....   | 82   |
| 5.3 Microscopic findings in organs of white-winged ducks ( <i>Cairina scutulata</i> ) with diffuse granulomatous inflammation. ....   | 83   |

## CHAPTER I

### INTRODUCTION

Avian mycobacteriosis is a common disease in pet, avicultural and zoo birds. In contrast to mycobacterial diseases of humans and livestock, little attention has been paid to the avian disease and there is little new information available on these infections. Recent developments in this field includes the finding that *Mycobacterium genavense* commonly causes diseases in birds and the application of the polymerase chain reaction (PCR) as a diagnostic and investigative tool. Areas of research that are in need of investigation include the molecular epidemiology, pathogenesis, clinical diagnosis and therapeutics of this disease of birds. For example, little is known about the role that the different mycobacteria and the host genetics play in the development of the disease. Also, studies on the predictive value of tissue sampling, the sensitivity and specificity of different diagnostic techniques and the efficacy of multi-drug therapy in naturally infected birds have not been conducted.

In this dissertation we present the results of an investigation about the molecular epidemiology, pathogenesis, diagnosis and treatment of avian mycobacteriosis in naturally infected ring-neck doves (*Streptopelia risoria*) and, in lesser extent, white-winged ducks (*Cairina scutulata*).

---

This dissertation follows the style of *Journal of Avian Pathology*.

The main hypotheses considered in this study were:

1) the lesion type, distribution and susceptibility to infection and disease of naturally infected ring-neck doves is genetically determined and associated to feather color (Chapter II)

2) the use of multiple-organ sampling and multi-modal diagnostic methodology, in naturally infected doves, will improve our ability to detect infected birds as compared with sampling of a single organ or the use of a single diagnostic technique (Chapter III)

3) a multi-drug treatment consisting of azithromycin, ethambutol and rifampicin in infected ring-neck doves will result in elimination of infection, as assessed by culture, PCR, histopathology and other ancillary tests (Chapter IV).

Finally, in chapter V we investigated the gross and microscopic findings and the etiopathogenesis of mycobacteriosis in a captive population of white-winged ducks (*Cairina scutulata*), a severely endangered Southeast Asian species severely affected by mycobacteriosis and the factors leading to the apparent high susceptibility of these ducks to infection.

## CHAPTER II

### MYCOBACTERIOSIS IN NATURALLY INFECTED RING-NECK DOVES (*STREPTOPELIA RISORIA*): ASSOCIATION OF FEATHER COLOR WITH SUSCEPTIBILITY TO INFECTION AND DISEASE AND LESIONS TYPE

#### **Introduction**

Mycobacteriosis is a relatively common cause of disease in pet, avicultural, zoo and free-ranging birds (Montali, 1976; Tell *et al.*, 2001; Pollock, 2006; Converse, 2007). Most cases of mycobacteriosis are caused by *Mycobacterium a. avium* and *M. genavense*, although other species of mycobacteria such as *M. tuberculosis*, *M. fortuitum*, *M. gordonae*, *M. nonchromogenicum* and *M. celatum* may also infect birds (Hoop *et al.*, 1996; Tell *et al.*, 2001; Bertelsen *et al.*, 2006; Steinmetz *et al.*, 2006). Birds usually acquire this infection through the oral route and less commonly through inhalation (Thoen, 1997; Cromie *et al.*, 2000; Tell *et al.*, 2001; Schmidt *et al.*, 2003; Pollock, 2006; Converse, 2007). The pathogenesis of natural avian mycobacteriosis has been minimally investigated (Francis, 1958, Hejlícek and Treml, 1995; Cromie *et al.*, 2000; Tell *et al.*, 2001; 2003a) and many aspects of the disease remain unclear.

Common gross lesions in birds with mycobacteriosis include hepatomegaly, splenomegaly and diffuse thickening of the intestines (Montali *et al.*, 1976; Schmidt *et al.*, 2003). Yellow caseous nodules of variable size embedded in the liver, spleen, lung, and kidney parenchyma or in the serosal surfaces of intestines are usually present.



Microscopic findings consist of focal to multifocal, sometimes coalescing, granulomatous inflammation characterized by a variable number of lymphocytes, histiocytes and multinucleated giant cells, with or without central necrosis. An intestinal form resembling the inflammatory pattern observed in Johne's disease and a diffuse granulomatous inflammation, with or without amyloid infiltrate, can also be found in some birds (Tell *et al.*, 2001).

Although reports of mycobacteriosis exist for most orders of birds, susceptibility, prevalence of infection and disease, degree of organ involvement and the nature of the lesions varies widely (Montali *et al.*, 1976; Hejlícek and Treml, 1995; Friend, 2001; Tell *et al.*, 2001; Cromie *et al.*, 2000; Schmidt *et al.* 2003; Pollock, 2006; Converse, 2007). Environmental factors have been proposed to explain different susceptibility (Montali *et al.*, 1976; Tell *et al.*, 2001; Pollock, 2006). Malnutrition, overcrowding, concurrent diseases, and poor hygiene alone or combined are potential stressors that may predispose birds to mycobacteriosis. Furthermore, mycobacteria are ubiquitous organisms that can survive and accumulate in the environment for prolonged periods (Falkinham, 2002). However, environmental factors do not explain completely the different susceptibility of birds to mycobacteriosis. Not all birds housed in the same facilities and under the same management practices become infected and develop this disease (Cromie *et al.*, 1991; 1992, Saggese *et al.*, unpublished data) and their response to these different stressors may vary.

Variations in the pathology of natural and experimental infection, the degree of organ involvement and the nature of the lesions of mycobacteriosis has been attributed either to characteristics of the agent, stage of the disease or to the bird's immune response (Montali *et al.*, 1976; Cromie *et al.*, 2000, Schmidt *et al.*, 2003). Limited studies suggest that host genetic factors play a major role in determining susceptibility to avian mycobacteriosis (Cromie *et al.*, 1991; 1992; Hejlícek and Treml, 1995). A differential susceptibility to mycobacteriosis, reflected by the number of affected birds and the nature of their lesions, has been demonstrated experimentally in two chicken lines challenged with *M. avium* (Gross *et al.*, 1989). Recently, genetic susceptibility has also been suggested as a predisposing cause of disease and for the different nature of lesions in captive white winged-ducks and two species of doves (Cromie *et al.* 1991; 1992; Saggese and Phalen, 2005; Saggese *et al.*, 2007) naturally exposed to mycobacteriosis. One of the most obvious differences is observed in different species of ducks, as has been reported at Slimbridge, United Kingdom, suggesting inherited susceptibility (Cromie *et al.*, 1992; 2000). This has been attributed to decreased heterozygosity and possible defects in cell-mediated immunity (Cromie *et al.*, 2000; Riggs, 2005; Saggese *et al.*, 2007).

The lack of information available about the role of genetics and susceptibility to tuberculosis in birds contrasts to what is known in humans and other mammals (Bellamy and Hill, 1998). Both environmental and genetic factors and their interaction influence susceptibility to tuberculosis in humans (Casanova and Abel, 2002; Schurr, 2007),

laboratory animals such as rabbits and mice and in domestic mammals (Barthel *et al.*, 2000; Phillips *et al.*, 2002; Di Pietrantonio and Schurr, 2005; Dannenberg, 2006). For example, in humans infected with *M. tuberculosis*, less than 10% of infections progress to clinical disease (Cole *et al.*, 2004). Resistance to clinical disease has been linked with ethnic background and race (Bellamy *et al.*, 2000, Lim, 2000, Casanova and Abel, 2002; van Helden *et al.*, 2006). Genes coding for Natural-Resistance-Associated-Macrophage-Protein 1 (NRAMP1), Vitamin D receptor, Interferon Gamma Receptor, interleukin-1, interleukin-10, interleukin-12, HLA Class II molecules, Toll-like Receptor 2 and tumor necrosis factor alpha, are all considered to influence immunity to mycobacterial infection. Their deficiency, functional defect or genetic polymorphism has been associated with altered susceptibility to mycobacteriosis (Taffik, 2001; Casanova and Abel, 2002; Phillips *et al.*, 2002; Bellamy, 2005; Acevedo-Whitehouse *et al.*, 2005; Naik, 2006; Hill, 2006). The chromosome location of some of these genes has been elucidated (Cervino *et al.*, 2002; Bellamy, 2003; Baghdadi *et al.*, 2006).

Among birds, pigeons and doves (Order Columbiformes) are considered susceptible to avian mycobacteriosis (Feldman, 1938; Francis, 1958; Van der Schaf *et al.*, 1976; Montali *et al.*, 1976; Pond and Rush, 1981; Bougiouklis *et al.*, 2005). Other authors, however, consider some species of pigeon and doves to be highly resistant to experimental and natural infection (Hejlícek and Treml, 1993; 1995). These contrasting opinions may be explained both by genetic factors as well as by local environmental and other risk factors. In one study (Hejlícek and Treml, 1993), differences in species

susceptibility to natural and experimental infection with *M. avium* were observed in collared doves (*Streptopelia decaocto*) and turtle doves (*Streptopelia turtur*). The former were found to be highly susceptible while the related turtle doves were resistant (Hejlícek and Treml, 1993; 1995).

Other evidence for a possible genetic component for this different susceptibility comes from a natural outbreak of mycobacteriosis in Texas in 1998. A flock containing diamond doves (*Geopelia cuneata*) and two different color morphs (white and wild-type) of ring-neck doves (*Streptopelia risoria*), showed significant differences in organ involvement, distribution and histopathologic lesions and serologic responses (Saggese and Phalen, 2005). While all three groups of doves presented with microscopic lesions in the liver and the spleen, lesions in the intestines, bone marrow and lungs were found only in wild-type ring-neck doves. Multifocal granulomatous hepatitis was observed in all the birds, but a diffuse granulomatous hepatitis was only observed in the wild-type doves (Saggese and Phalen, 2005). The finding, by PCR and sequencing of the *dnaJ* gene, of the same *Mycobacterium a. avium* in these doves and the shared environment in which these birds were housed suggested that these variations were not due to different organisms or to differences in exposure. Furthermore, the absence of antibodies (as detected by complement fixation) in the white ring-neck doves compared to seropositivity in wild type and diamond doves suggested that a different humoral immune response occurred in these birds. This also supports the suggestion that differences in the pathogenesis and immune response were associated with color.

Whereas the number of birds in this study was small, and several variables were not formally controlled precluding a statistical analysis, these data together with previous studies (Hejlíček and Trembl, 1993; 1995) suggested the possibility that differences in susceptibility and pathology of mycobacterial infections may occur in ring-neck doves with different color morphs, and points to a possible association between genes coding for feather color and susceptibility to infection.

Ring-neck doves present in several color morphs, obtained by natural or artificial selection. The genetics of these color mutations in this species have been analyzed (Miller, 2007). Identifying and understanding differences in pathogenesis and susceptibility to mycobacteriosis in closely related species or strains of birds could assist identification of the genes involved in differential susceptibility and pathogenesis. The occurrence in Texas of a captive population of ring-neck doves, including individuals of different color morphs, suffering from avian mycobacteriosis offered an opportunity to investigate the presentation of this disease in a large number of birds and to look for evidence of differential susceptibility. We hypothesized that lesion type and distribution and susceptibility to infection and disease of naturally infected ring-neck doves would be different in white doves compared to other color morphs. Therefore, the main goals of this study were to 1) investigate the prevalence of mycobacterial infection and disease in the different color morphs found in this flock, 2) describe and characterize the gross and microscopic lesions in affected birds, 3) identify the species and sequevar of mycobacteria involved, and 4) determine if an association exists between susceptibility

to this infection and disease, lesion characteristics and feather color morphs of ring-neck doves.

### **Materials and Methods**

**Specimens.** Seventy adult ring-neck doves were obtained from an aviary near Hillsboro, Texas, in July 2005. These birds came from a flock where more than 60 doves had died during the previous six months. Mycobacterial infection had been previously confirmed in these birds at the Texas Veterinary Medical Diagnostic Laboratory (College Station, TX, USA) and the condition of some of the surviving birds (decreased productivity, weight loss and depression) was consistent with mycobacteriosis. These birds were all housed in a small shed that was open to and surrounded on 2 sides by an outdoor flight. There was heavy fecal contamination of the floor and perching surfaces of the shed. Food and water were contaminated with feces. The surviving birds were donated and transferred to an isolation building at the College of Veterinary Medicine and Biomedical Sciences, Texas A&M University, College Station, TX, USA. During the following two weeks, twenty-nine birds (11 white, 8 blond, 6 pied, 1 orange, 2 wild-type and 1 white-silky colored, *sensu* Oliver (2005) and Miller (2007) were randomly selected, anesthetized by intramuscular injection of ketamine and xylazine and euthanized by exsanguination through cardiocentesis.

Doves were necropsied and samples collected within four hours of euthanasia. Tissues were collected for PCR using cleaned, autoclaved instruments that had been treated with

bleach and formalin. A different set of instruments was used to collect tissues from each bird and organ to prevent DNA carryover. Samples of liver, spleen, and bone marrow and of other organs with gross lesions were collected and frozen for PCR and culture. Liver, spleen, lung, trachea, heart, kidney, esophagus, crop, proventriculus, ventriculus, intestines, gonads, pancreas and skeletal muscle were examined for lesions consistent with mycobacteriosis. Specimens from these organs were formalin-fixed and paraffin-embedded and stained with hematoxylin and eosin and Ziehl-Neelsen.

**Pathology.** Microscopically, inflammatory lesions were scored semi-quantitatively as mild, moderate and severe based on the amount of inflammatory cells within the lesions and the area of tissue affected. Histopathological changes compatible with mycobacteriosis were described and classified as focal/multifocal granulomatous, consisting of well defined foci of inflammatory cells, sometimes surrounded by a ring of fibrous tissue and with (sometimes without) a variable amount of central caseous necrosis, or classified as diffuse granulomatous inflammation, with a variable degree of diffuse inflammatory cell infiltration without formation of discrete foci or nodules, absence of a fibrous capsule and little or no caseous necrosis. The numbers of acid-fast bacilli were subjectively graded as none, few, many or massive. Congo red staining was employed to investigate the presence of amyloid in liver and spleen.

**Detection of mycobacteria in tissues.** Swabs from macerated liver, spleen and bone marrow from all the doves were inoculated into 5 ml of Middlebrook 7H9 broth

(Beckton Dickinson, Franklin Lakes, New Jersey, USA) containing 0.5% (v/v) glycerol and 10% (v/v) oleic acid-albumin, and incubated at 39 °C following mycobacterial culture standards (Mahon *et al.*, 2007). Cultures were inspected weekly for microbial growth and examined for the presence of mycobacteria by Ziehl-Neelsen staining.

DNA was extracted from all affected livers, spleen and bone marrow using the Puregene® Genomic DNA Purification Kit (Gentra Systems, Minneapolis, Minnesota, USA) following the instructions of the manufacturer. PCR screening for mycobacterial DNA was performed using primers T1 [5'-GGGTGACGCG(G/A)CATGGCCCA-3'] and T2: [5'-CGGGTTTCGTCGTACTIONCCTT-3'] for amplification of the 236 bp *dnaJ* gene as described by Morita *et al.*, (2004). The PCR reaction parameters were as follows: one initial cycle of 94° for 5m; 40 cycles at 94° for 30s, 60° for 45s and 72° for 1m; and an additional elongation step at 72° for 5m. Positive (*M. a. avium*) and negative reaction control (DNA-RNA free sterile water) were utilized in each reaction. Amplified DNA was visualized after electrophoresis on a 1.5% ethidium bromide-stained agarose gel. PCR products were purified using QIAquick PCR Purification Kit (Qiagen Inc., Valencia, California, USA). Sequencing reactions were performed using an ABI Prism® Big Dye Terminator v3.0 Cycle Sequencing Kit (Applied Biosystems Inc., Foster City, California, USA). Nucleotide sequences were determined with an ABI3100 automated DNA sequencer (Applied Biosystems Inc., Foster City, California, USA). All sequences were aligned using Clustal X 1.81 (Thompson *et al.*, 1997) and were compared to sequences retrieved from GeneBank® ([www.ncbi.nlm.nih.gov/Genbank/index.html](http://www.ncbi.nlm.nih.gov/Genbank/index.html)).



**Infection and disease status.** Criteria for the classification of the infection and disease status of the birds was based upon the presence of gross and microscopic lesions and positive identification of mycobacteria by culture, PCR or the identification of acid-fast organisms in stained tissues or smears. Four categories were identified. Severely diseased: birds with moderate to severe inflammation in one or more organs and positive for mycobacteria; Mildly diseased: birds with mild lesions compatible with mycobacteriosis and negative for mycobacteria; Healthy uninfected: birds without lesions and negative for mycobacteria. Healthy infected: birds without lesions and negative for acid fast bacilli in tissues but positive PCR and/or culture results.

**Statistics.** The association between white and non-white colored (8 blond and 11 mixed colored) doves together with health and infection status, number of organs with lesions and type of inflammation in spleen and liver was analyzed using contingency tables and Fischer's exact test after demonstration of normality. Test statistics were considered significant at  $p < 0.05$ . All the statistical analysis was conducted using the formula package in Prism 5 for Windows® (GraphPad Software, Inc. Available on-line at [www.graphpad.com](http://www.graphpad.com)). This research was approved by the ULACC/IAACUC at Texas A&M University (Animal Use Protocol 2005-56).

## Results

**Macroscopic findings.** Twenty nine doves were examined by necropsy. Gender, color, health and infection status of white and non-white color morphs are presented in Table 2.1.

Table 2.1. Prevalence of infection and diffuse and multifocal lesions in white and non-white ring-neck doves (*Streptopelia risoria*). N=sample size; M=male; F=female.

| Color     | N  | Gender    | Mean number of organs affected | Infected      | Diseased      | Pattern of inflammation |        |                  |        |
|-----------|----|-----------|--------------------------------|---------------|---------------|-------------------------|--------|------------------|--------|
|           |    |           |                                |               |               | Diffuse liver           | spleen | Multifocal liver | spleen |
| White     | 11 | M 2; F 9  | 3.1                            | 4/11 (36.3%)  | 7/11 (63.6%)  | 1                       | 2      | 6                | 5      |
| Non-white | 18 | M 10; F 8 | 5.9                            | 14/18 (77.7%) | 14/18 (77.7%) | 12                      | 11     | 1                | 2      |

Twelve doves were males and seventeen were females. Nineteen birds (65.5%) presented with gross lesions compatible with mycobacteriosis. Spleen and liver were most commonly affected, followed by the intestines and the lungs. Heart, kidney, air sacs and trachea were rarely grossly affected. Most affected birds had multiple organ involvement. No significant gross lesions were observed in the esophagus, proventriculus, ventriculus, gonads, pancreas, central nervous system and skeletal muscle. Gross lesions in the liver of most birds consisted of severe, diffuse, pale orange-tan discoloration and enlargement (Figure 2.1).

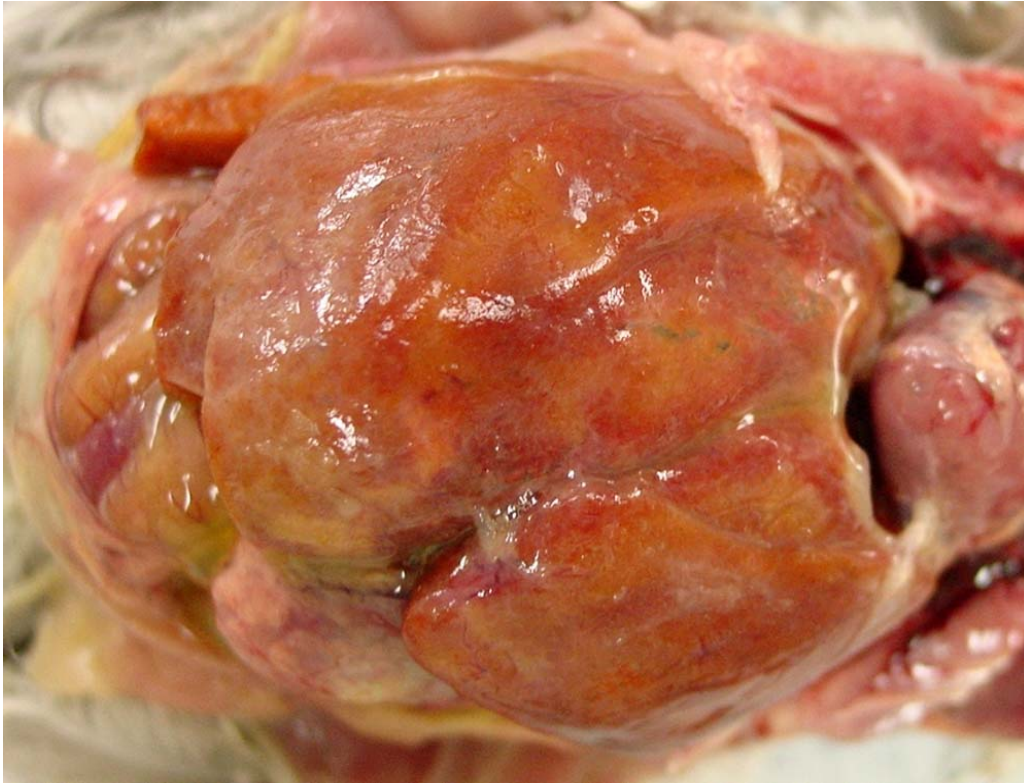


Figure 2.1. Severe hepatomegaly and orange-tan discoloration in a non-white ring-neck dove with mycobacteriosis.

In two birds, the liver was moderately enlarged and contained single or multiple white-yellow nodules of variable size (range 1 - 10 mm) embedded in the parenchyma (Figure 2.2).

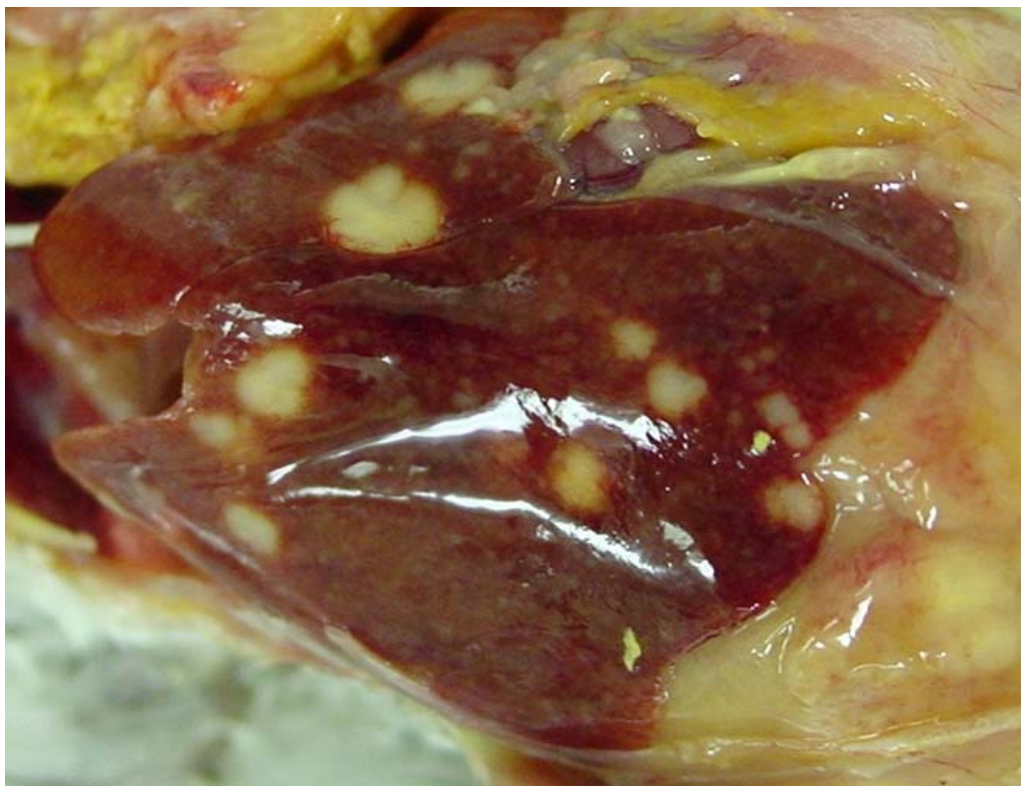


Figure 2.2. Moderate hepatomegaly and multifocal hepatic granulomas in a white ring-neck dove with avian mycobacteriosis.

Gross lesions in spleens consisted of one or more, caseous, firm yellowish foci, of variable size. The largest foci usually had a caseous central core of necrosis. Splenomegaly was observed in thirteen birds. Focal or multi-focal caseous nodules of variable size and numbers were found in the lungs and kidneys. Diffuse thickening of the duodenum and a variable number of yellow, round or oval shaped foci 2 to 5 mm in diameter were observed in the intestinal wall or protruding on the serosal surface in eleven birds. These foci were usually more numerous and evident in the duodenum but they were also observed along the jejunum, ileum and colon. Five birds presented with

ascites. Diffuse air sacculitis and pericarditis were additional findings in three birds. Gross lesions were not observed in the remaining organs.

**Microscopic findings.** Twenty one of twenty nine (72.4%) birds had microscopic lesions consistent of mycobacteriosis. Lesions were common in liver, spleen, lung, kidney, intestines, ovary and bone marrow (Figure 2.3).

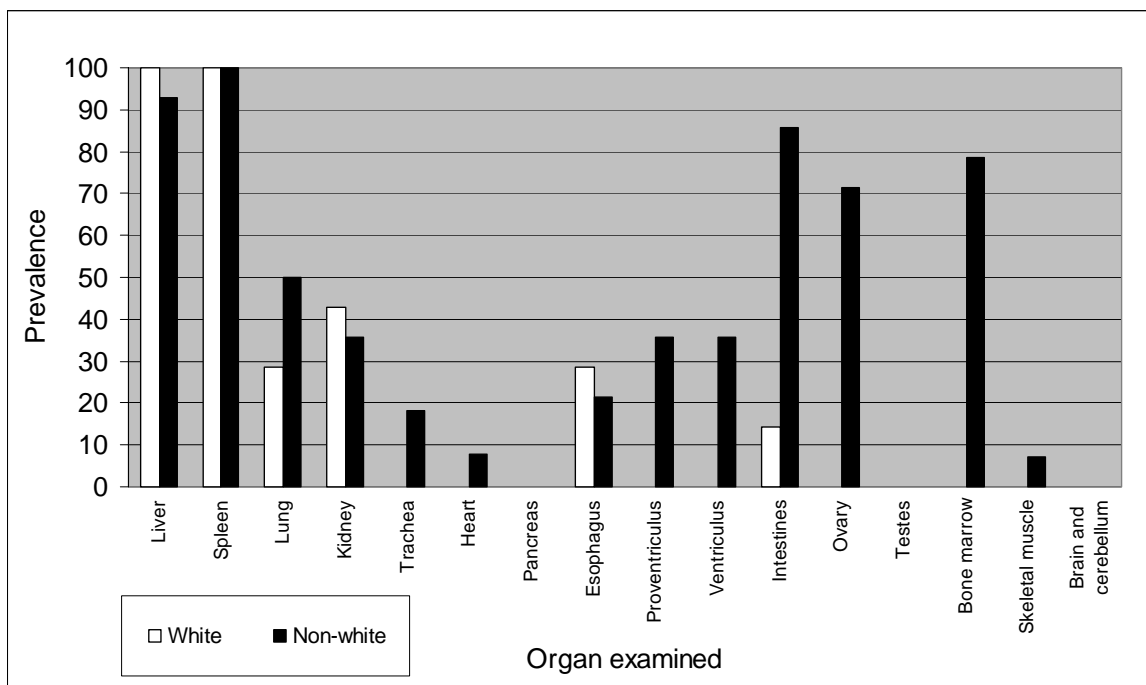


Figure 2.3. Prevalence of microscopic lesions in white and non-white diseased ring-neck doves (*Streptopelia risoria*).

Microscopic lesions of the liver could be divided into two forms that corresponded to the observed gross lesions. The first was a severe granulomatous inflammation characterized by nodules of variable size. They were composed mainly of histiocytes, lymphocytes



and multinucleated giant cells, sometimes with small numbers of plasmacytes (Figure 2.4).

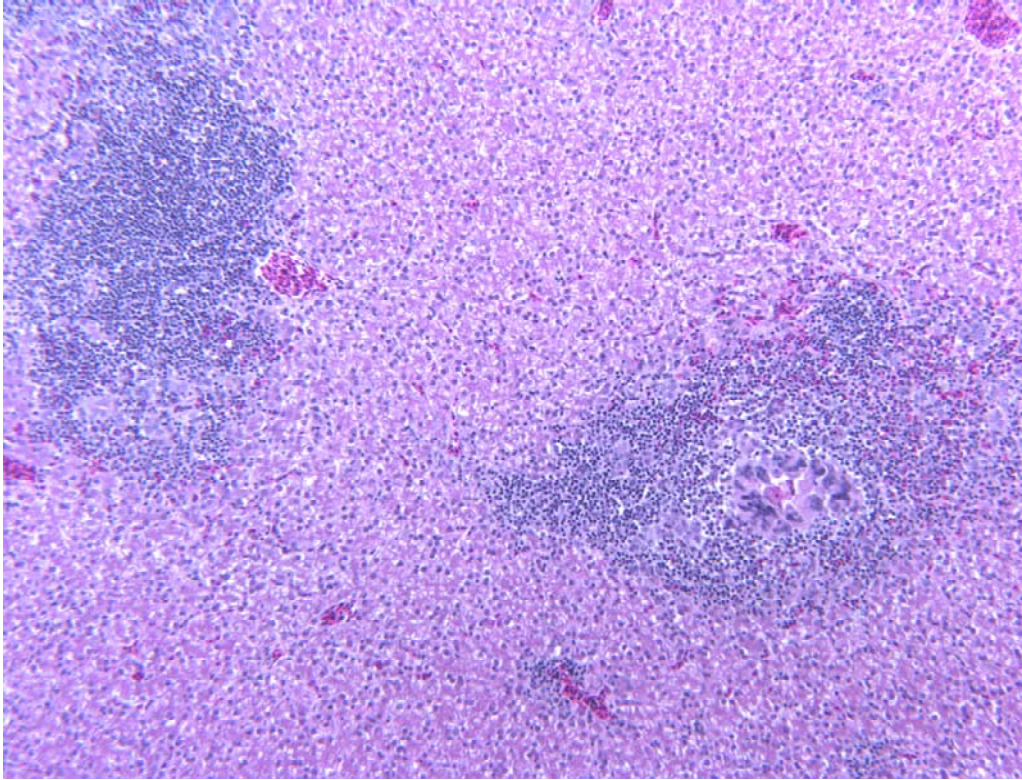


Figure 2.4. Multifocal hepatitis characterized by lymphocytic and histiocytic infiltrates in a white ring-neck dove. A central core of necrosis ringed by multinucleated giant cells can be observed in the right focus.

These granulomas rarely contained a central zone of necrosis, except for two birds and, in some cases, a thin fibrous capsule surrounded the largest nodules. These nodules tended to be periportal, but also widely scattered in some birds. Many to massive numbers of acid-fast organisms were observed restricted in the central necrotic core of the granulomas. The second form of microscopic inflammation pattern in the liver was characterized by a severe diffuse infiltration of the parenchyma with hystiocytes,

scattered multinucleated giant cells and, to a lesser degree, lymphocytes and plasmacytes (Figure 2.5).

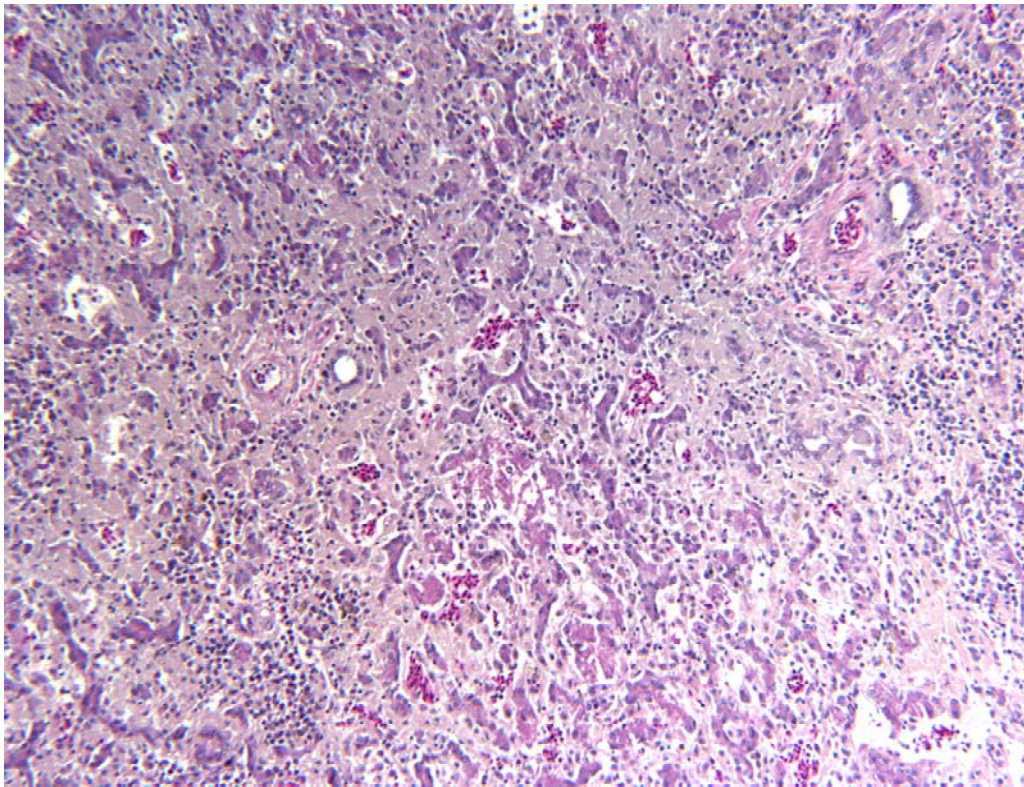


Figure 2.5. Severe diffuse granulomatous hepatitis and infiltrates of amyloid in the parenchyma in a non-white ring-neck dove.

Thick layers of amyloid were observed between the hepatocytes and the space of *disse*.

No or few acid-fast organisms were associated with this inflammation pattern.

Two similar patterns of inflammation were also observed in the spleen. The diffuse form was characterized by infiltration of this organ with large numbers of histiocytes and multinucleated giant cells, with lymphocyte and erythrocyte depletion. Caseous necrosis was observed in the more extensive areas of inflammation. Many to massive numbers of

acid-fast organisms were observed in these lesions. The second pattern consisted of mild focal or multifocal histiocytic nodules, in some cases accompanied of multinucleated giant cells. Central necrosis was not common in these birds. No or few acid fast organisms were observed in this form of inflammation.

Focal or multi-focal granulomatous pneumonia was observed in seven non-white and two white doves respectively. Two white and two non-white doves had mild multifocal, lymphocytic, nephritis but necrosis was not a component of the kidney lesions. A severe, diffuse, air sacculitis characterized by large amounts of necrotic debris, exudate and severe histiocytic infiltration with massive numbers of acid fast bacteria was observed in three non-white birds.

Moderate to severe multifocal serosal and mucosal granulomatous enteritis was observed in thirteen birds. Mild multi-focal to severe diffuse bone marrow inflammation was observed in eleven non-white doves, characterized by replacement of normal bone marrow by hystiocytes and multinucleated giant cells.

Very mild lesions in liver, spleen or lung, without detectable mycobacteria in acid-fast stained tissues, smears, cultures and PCR were observed in three white and one blond bird.



**Health and infection status.** Overall, 18 out of 29 (62%) birds were considered infected, based on positive results from cultures and PCR and/or by the detection of acid-fast bacilli in one or more tissues or smears (Table 1). An amplicon of expected molecular mass (236 bp) was amplified by PCR from liver or spleen from four white and six non-white doves. These sequences were identical and had 100% identities with the sequenced of *Mycobacterium a. avium* that contains serotypes 2, 3, 4 and 9 (Morita *et al.*, 2004).

Based on the presence of gross and microscopic lesions, 21 of 29 (72.4%) birds were considered diseased. Seventeen were considered severely diseased while the four birds that had microscopic lesions but negative for mycobacteria were considered mildly diseased. With the exception of one bird, all the eighteen infected birds showed microscopic lesions and were considered diseased. This negative dove was considered infected based on positive culture and PCR of liver and spleen samples, but classified as healthy infected in the absence of significant lesions.

**Differences between white and non-white doves.** The prevalence of infection in the white doves (36.4%) was significantly lower than in the non-white morphs (77.7%). White doves had on average fewer organs affected than the non-white. The pattern of inflammation was significantly different between the two groups. The association between a diffuse pattern in liver and spleen was significantly different between white and non-white doves. This diffuse pattern of inflammation was rare in the white doves.

No statistically significant differences in the prevalence of disease between white and non-white doves were observed.

## **Discussion**

This study investigates a natural presentation of mycobacteriosis in ring-neck doves. Important observations are the variability observed in susceptibility to infection, organ distribution and nature of lesions between white and non-white doves. In the presence of identical environmental conditions these differences can be explained by genetic differences associated with the phenotypic characteristic, color morph. While the age and time of infection for each individual dove was unknown, all were adults kept under identical food and housing conditions. The presentation of this disease, constant exposure and the chronic nature of the lesions of mycobacteriosis together with the sample size make it unlikely that age or time of infection influenced our results.

There are several reports of mycobacteriosis in pigeons and doves (Feldman, 1938; Pond and Rush, 1981; Hejlíček and Treml, 1993; 1995, Morita *et al.*, 1994; Bougiouklis *et al.*, 2005; Saggese and Phalen, 2005), but prevalence of infection and/or disease in captive populations of ring-neck doves have not been previously reported to the author's knowledge. Overall, the prevalence of mycobacteriosis in captive collections of birds is rarely higher than 15% (Montali., *et al.*, 1976; Van der Heyden 1997; Tell *et al.*, 2001). Nevertheless, while the prevalence of infection (62%) and disease (72.4%) was considered very high in this flock, the finding that not all the birds were infected

suggests that exposure alone under the conditions observed in this flock (overcrowding, poor hygiene) was apparently not sufficient to cause infection or disease in some birds.

The distribution of gross and microscopic lesions in these birds was similar to that previously reported in other birds with mycobacteriosis. Liver, spleen, lung, bone marrow are common sites of mycobacterial infection in birds (Feldman, 1938; Francis, 1958; Tell *et al.*, 2001; Fulton and Thoen, 2003; Converse, 2007). Focal or multi-focal granulomatous inflammation is the most common form observed in this disease (Montali *et al.*, 1976; Fulton and Thoen, 2003; Schmidt *et al.*, 2003). The diffuse pattern of granulomatous inflammation observed in this study is consistent with the non-tuberculoid form described by Tell *et al.*, (2001), in which diffuse infiltration of the organ with inflammatory cells occurs. The diffuse enlargement observed in twelve doves with diffuse histiocytic and multinucleated giant cells and severe amyloidosis is consistent with this description. A diffuse form of granulomatous inflammation similar to that observed in the non-white doves was previously observed in wild-type ring-neck doves but not in white birds (Saggese and Phalen, 2005). This pattern of inflammation resembles the lepromatous form of granulomatous inflammation observed in human leprosy (Connor *et al.*, 1997). The presence of this diffuse form contrast with reports in other species of doves, where the tuberculoid or nodular form of granulomatous inflammation has been reported (Feldman, 1938; Pond and Rush, 1981; Morita, 1994; Bougiouklis *et al.*, 2005). Alternatively, it has been stated that tubercles rarely develop in Columbiformes with mycobacteriosis, although specific details were not provided

(Ramis *et al.*, 1996). Nevertheless, the presence of both types of inflammation in the doves of our series may explain these conflicting opinions.

Twelve birds had amyloidosis of the liver. Massive amounts of amyloid were observed in doves with diffuse inflammation, but very little was observed in the birds with the multifocal pattern of inflammation. Amyloidosis is a pathological condition characterized by the deposition of insoluble fibrillar proteins in various tissues and organs of the body following prolonged inflammation or infection (Cotran *et al.*, 1999). Amyloid deposits have been reported previously in birds with chronic inflammatory diseases such as mycobacteriosis and aspergillosis. Several forms of amyloid have been described in mammals, but only amyloid AA has been found in birds (Landman *et al.*, 1998; Cotran *et al.*, 1999; Schmidt *et al.*, 2003). Amyloid A is a product of the proteolytic cleavage of serum amyloid A, an acute phase-protein produced by hepatocytes (Landman *et al.*, 1998). The concentration of serum amyloid A in the blood increases within several hours of the onset of injury, infection, or inflammation. Production of serum amyloid A is directly stimulated by the cytokines interleukin-1, interleukin-6 and tumor necrosis factor alpha produced in response to tissue injury and inflammation (Petersen *et al.*, 2004). The persistent inflammation caused by chronic mycobacteriosis is a likely cause of the deposition of amyloid in these organs. Amyloid was not a feature in the mildly diseased doves with focal or multifocal granulomatous inflammation, suggesting that an inflammatory process in these birds was insufficient or

of short duration to trigger amyloidosis, supporting the suggestion of an infection arrested at early stages.

There were significantly fewer organs with gross and microscopic lesions in the white doves compared to other birds. Lung and intestines were rarely affected in the white doves compared with the non-white. These findings suggest that lesion distribution, as well as the severity of the lesion and the type of the lesion, are influenced by factors linked to feather color.

Four doves had mild lesions consistent with a mycobacterial infection but were negative on all tests for the organisms. It is possible that these birds had low levels of mycobacteria in their tissues and that they were not detected. However, it is more likely that these birds had recently overcome a mycobacterial infection through a mild but adequate cell-mediated immune response. It is likely that the mild lesions observed in these four birds represented a controlled or at least an arrested infection, similar to that seen in other mycobacterial infections (Jubb *et al.*, 1992; Cotrans *et al.*, 2002; Dannenberg, 2006). It suggests that at least some birds may recover from natural infection. The fact that three out of these birds were white is consistent with other observations made between different color morphs.

A single dove with confirmed mycobacterial infection of the liver and spleen did not have lesions. The significance of this is unknown, but could represent the early stage of

infection that was prior to the onset of detectable lesions or that a lesion was present but not detected. This case shows, that in some circumstances, culture or PCR may be a necessary adjunct to histopathology to detect all infected birds.

This study represents the first attempt to examine the association between feather color and susceptibility to infection, disease and pathology in naturally infected ring-neck doves. The white doves had a lower prevalence of infection, fewer infected organs affected and a different pattern of inflammation as compared to the colored doves. These data are consistent with epidemiological and genetic studies showing immune response polymorphism to mycobacterial infections in humans and other mammals (Bellamy, 2003; Dorman *et al.*, 2004; Barthel *et al.*, 2005; Pan *et al.*, 2005; Di Pietrantonio and Schurr, 2005) and in different strains of chickens (Cotter *et al.*, 1992; Bumstead *et al.*, 1995; Hu *et al.*, 1997; Bacon *et al.*, 2000). Specific genes that have been associated with differing immune responses to mycobacterial infections include those that code for the major histocompatibility receptors, cytokines, T-cell receptors, immunoglobulins and NRAMP1 (Zekarias *et al.*, 2002).

Ring-neck doves have been selected for different phenotypic traits, mainly color, for more than 2000 years and more than 45 color morphs are currently recognized by pigeon fanciers (Oliver, 2005). The genetics that govern the coloration of ring-neck doves have been partially deduced by Miller (2007). There are three basic color morphs in ring-neck doves: dark or wild type, blond and white. Dark is dominant both over blond and white, and blond is dominant over white. The alleles coding for color are sex-linked, and are

located on the sex chromosome. Females are  $ZW$  or  $Z^-$  and males are  $ZZ$ . Females' single white gene and homozygous males will be white. It is very likely that the gene or genes involved in immunity to *M. a. avium* infection in these doves could be associated to these loci or at least located in the same ( $Z$ ) chromosome.

CHAPTER III  
COMPARISON OF SAMPLING METHODS AND DIAGNOSTIC TECHNIQUES FOR  
THE DIAGNOSIS OF MYCOBACTERIOSIS IN RING-NECK DOVES  
(*STREPTOPELIA RISORIA*)

**Introduction**

Mycobacterial infections are a relatively common cause of disease in pet and aviary birds (Tell *et al.*, 2001; Pollock, 2006). Given that they are difficult or impossible to treat successfully, can spread to other birds before signs of infection are present, and pose a potential zoonotic risk, a sensitive and specific means of diagnosing mycobacteriosis in birds is needed. Mycobacteriosis is usually suspected in a bird based on a combination of historical, physical, hematological, and biochemical findings and the results of imaging (Dorrenstein *et al.*, 1996; Tell *et al.*, 2001; Converse, 2007). However, even when different diagnostic modalities are available, mycobacteriosis is difficult to diagnose in the live bird.

As most mycobacterial infections result in a chronic disease, a history of a chronic progressive illness is suggestive of mycobacteriosis. Clinical signs in birds with mycobacteriosis include depression, weight loss, anorexia, diarrhea, and death (Tell *et al.*, 2001; Pollock, 2006). Less commonly birds will exhibit dyspnea, vomiting, abdominal distension, and seizures (Tell *et al.*, 2001; Pollock, 2006; Converse, 2007). All these signs, however, can be caused by other infectious and non infectious diseases.



Anemia, leucocytosis, heterophilia and monocytosis are also common findings, but are not specific to this disease (Campbell and Ellis, 2007) and plasma biochemical changes have been reported to be unrewarding (Van der Heyden, 1997). However hematological and biochemical parameters may assist in evaluating general condition of infected birds, determining the severity of disease, establishing a prognosis and monitoring treatment response and recovery.

The utility of serum or plasma protein electrophoresis for diagnosis of mycobacteriosis in birds has been discussed (Werner and Reavill, 1999; Tatum et al., 2000; Cray *et al.*, 2001; 2004; 2007). Hyperproteinemia accompanied by an increase in either beta or gamma globulins and a decrease in albumin has been described in mycobacterial infections (Werner and Reavill, 1999; Cray *et al.*, 2001; 2004; 2007). Limitations of this technique include species, gender, and even age differences in blood protein values (Werner and Reavill, 1999). The usefulness of these ancillary diagnostic methods would be improved if changes in these values were known from large number of birds of the same species during a natural outbreak of avian mycobacteriosis.

Imaging techniques, such as radiology and ultrasonography, have the same limitations as the above diagnostic methods. They can demonstrate changes in organ size, shape, and in the case of ultrasound, consistency, or identify abnormal soft tissue structures, but they cannot conclusively differentiate mycobacterial lesions from similar lesions caused by other diseases (Fulton and Thoen, 2003). Imaging, however, can be used to assist biopsy

sampling and in a bird with confirmed mycobacteriosis, evaluate disease progression or the response to treatment (Hellmer, 2006).

Serological assays such as ELISA, hemagglutination inhibition and complement fixation tests have been employed for the diagnosis of mycobacteriosis in birds. (Cromie *et al.*, 1993; Clark *et al.*, 1995; Phalen 1995; Zsivanovits *et al.*, 2004). The value of these assays is largely unknown, as few controlled studies have been done, these assays have limited availability, and most require species-specific reagents. Moreover, birds diagnosed with mycobacteriosis do not always mount a humoral immune response and antibody may only become detectable in late stages of infection (Cromie *et al.*, 2000; Zsivanovits *et al.*, 2004). Intradermal skin testing, using avian purified protein derivative tuberculin, has been employed in poultry with positive results but has otherwise proven unreliable in other species of birds (Pollock, 2006).

Intestinal lesions, consisting of mycobacterial laden macrophages within the lamina propria, are seen in some birds with mycobacteriosis and some of these birds will have significant numbers of mycobacteria in their feces. However, acid-fast staining of feces has very low sensitivity because a large number ( $>5 \times 10^4$ /ml) of bacteria must be present in order to be seen (Tell *et al.*, 2003; Pollock, 2006). Fecal acid fast staining was not found to be diagnostic in Guam rails (*Gallirallus owstoni*) and Micronesian kingfishers (*Halcyon cinnamomina cinnamomina*) with mycobacteriosis (Fontenot *et al.*, 2006; Travis *et al.*, 2007). It has also been suggested that ingested non-pathogenic acid-fast

organisms may also be found in the feces (Dorrenstein 1996, Tell *et al.*, 2001, Pollock 2006, Fontenot *et al.*, 2006; Travis *et al.*, 2007).

Currently, the only definitive way to diagnosis mycobateriosis in a bird is to demonstrate organisms in organ biopsies or aspirates with acid-fast stains, by culture or by molecular methods. Of these, acid-fast staining is the most commonly used because it is widely available and relatively inexpensive (Dorrenstein *et al.*, 1996, Pollock, 2006). Unfortunately, stained bacilli are not always detectable in samples because of variable lesion distribution, low numbers of organisms or the presence of nonstainable dead organisms (Saggese and Phalen, 2005; Pollock, 2006).

Culture has been considered the definitive method for the diagnosis of mycobacteriosis (Thoen, 1998; Tell *et al.*, 2001, 2003a; Fulton and Thoen, 2003; Converse, 2007). Culture of mycobacteria however have several diagnostic limitations as they are often difficult organisms to grow and usually require prolonged incubation periods and various enriched media that depends on the species and strain investigated (Aranaz *et al.*, 1997). Additionally, in many cases, even though acid-fast organisms are present in the tissues, they cannot be grown. Improved culture techniques may make culture a better diagnostic method in the future (Aranaz *et al.*, 1997).

Molecular diagnostic methods, such as the polymerase chain reaction (PCR) have been used alone or in combination with culture to speed up and facilitate the diagnosis of

mycobacteriosis in humans and domestic animals, but have not been widely used in birds (Bartos *et al.*, 2006; Dvorska *et al.*, 2007; Tell *et al.*, 2003; Saggese and Phalen, 2005; Turenne *et al.*, 2006; Johansen *et al.*, 2007). These techniques, not only have the ability of detecting mycobacteria, they can also be used to identify the organism is causing the disease. (Hoop *et al.*, 1993; Portaels *et al.*, 1996; Tortolli 2003; Bougliouklis *et al.*, 2005).

In the end, much has been written about the diagnosis of mycobacteriosis in birds, but there have been very few studies comparing the sensitivity and specificity of the multiple available diagnostic assays used individually or in combination in birds with known infection status. The purpose of this study is to investigate the sensitivity and specificity of these multiple different diagnostic modalities in a large number of ringed-turtle doves (*Streptopelia risoria*) naturally infected with *M. a. avium*.

## **Materials and Methods**

**Specimens.** Seventy adult ring-neck doves were obtained from an aviary near Hillsboro, Texas, in July 2005. These birds came from a flock where more than 60 doves had died during the previous six months. Mycobacterial infection had been previously confirmed in these birds at the Texas Veterinary Medical Diagnostic Laboratory (College Station, TX, USA) and the condition of some of the surviving birds (decreased productivity, weight loss, and depression) was consistent with mycobacteriosis. These birds were all housed in a small shed that was open to and surrounded on two sides by an outdoor

flight. There was heavy fecal contamination of the floor and perching surfaces of the shed. Food and water were contaminated with feces. The surviving birds were donated and transferred to an isolation building at the College of Veterinary Medicine and Biomedical Sciences, Texas A&M University, College Station, TX, USA. During the following two weeks, twenty-nine birds (11 white, 8 blond, 6 pied, 1 orange, 2 wild-type and 1 white-silky colored, *sensu* Oliver (2005) and Miller (2007) were randomly selected, anesthetized by intramuscular injection of ketamine and xylazine and euthanized by exsanguination through cardiocentesis. Blood was chilled and processed within two hours after collection. Blood smears and packed cell volume were made and the remaining blood centrifuged at 12000 G for five minutes to separate the cellular fraction from the plasma. Plasma and the remaining cells with the buffy coat on the top were saved in DNA-free, 1.5 ml Eppendorf PCR tubes at -80° for further studies.

Doves were necropsied and samples collected within four hours of euthanasia. Tissues were collected for PCR using cleaned, autoclaved instruments that had been treated with bleach and formalin. A different set of instruments was used to collect tissues from each bird and organ to prevent DNA carryover. Samples of liver, spleen, and of other organs with gross lesions were collected during necropsy for PCR and culture and frozen. Liver, spleen, lung, trachea, heart, kidney, esophagus, crop, proventriculus, ventriculus, intestines, gonads, pancreas and skeletal muscle were examined for lesions consistent with mycobacteriosis. Specimens from these organs were formalin-fixed and paraffin-embedded.

**Sample collection.** Immediately after the birds were euthanized, tissue samples were collected using the biopsy techniques employed in live birds. Bone marrow aspirates, using a 20 G needle and 6 ml syringe, were obtained from the distal ulna. A bone marrow smear was made, heat-fixed and the remaining sample saved at  $-80^{\circ}\text{C}$ . The celomic cavity was opened aseptically through a midline ventral approach and a piece of liver approximately (4 x 4 x 4 mm) was excised from the caudal border of the right lobe. This is the location and size of tissue that would be collected from a live bird of this size during a routine liver biopsy. A small portion was saved for PCR and culture, and the remaining tissue formalin-fixed for histological examination. The duodenum was identified and aspirated with a 25 gauge needle and 1 ml syringe. A portion of the aspirated material was smeared onto a glass slide, heat-fixed and Ziehl-Neelsen stained. Bone marrow aspirates and “biopsied” liver were stained with Ziehl-Neelsen, cultured and tested by PCR. Samples from selected sections of the spleen and liver were also collected as part of the post mortem investigation of these birds. Total protein, albumin, globulin, aspartate aminotransferase, creatinine kinase, uric acid and plasma protein electrophoresis were also determined. Packed cell volume and estimated white blood cell count were performed as described (Fudge, 2000; Campbell and Ellis, 2007). Clinical biochemistry was performed at the Clinical Pathology Laboratory, Department of Pathobiology, College of Veterinary Medicine, Texas A&M University. Plasma protein electrophoresis was performed using the Titan Gel electrophoresis kit (Helena Laboratory, Beaumont, Texas) following manufacturer’s instructions.

**Identification of mycobacteria in tissues.** Swabs from macerated liver, spleen and bone marrow from all the doves investigated were inoculated into 5 ml of Middlebrook 7H9 broth (Beckton Dickinson, Franklin Lakes, New Jersey, USA) containing 0.5% (v/v) glycerol and 10% (v/v) oleic acid-albumin, and incubated at 39 °C (Mahon *et al.*, 2007). Cultures were inspected weekly for microbial growth and examined for the presence of mycobacteria by Ziehl-Neelsen staining.

DNA was extracted from all affected livers, spleen and bone marrow using the Puregene® Genomic DNA Purification Kit (Gentra Systems, Minneapolis, Minnesota, USA) following the instructions of the manufacturer. The duodenal aspirates were carefully washed in PBS and centrifuged twice at 12500 G for five minutes and DNA obtained as described previously. PCR screening for mycobacterial DNA was performed using primers T1 [5'-GGGTGACGCG(G/A)CATGGCCCA-3'] and T2: [5'-CGGGTTTCGTCGTACTCCTT-3'] for amplification of the 236 bp *dnaJ* gene as described by Morita *et al.*, (2004). The PCR reaction parameters were as follows: one initial cycle of 94° for 5m; 40 cycles at 94° for 30s, 60° for 45s and 72° for 1m; and an additional elongation step at 72° for 5m. Positive (*M. avium*) and negative reaction control (DNA-RNA free sterile water) were utilized. Amplified DNA was visualized after electrophoresis on a 1.5% ethidium bromide-stained agarose gel. PCR products were purified using QIAquick PCR Purification Kit (Qiagen Inc., Valencia, California, USA). Sequencing reactions were performed using an ABI Prism® Big Dye Terminator v3.0 Cycle Sequencing Kit (Applied Biosystems Inc., Foster City, California, USA).

Nucleotide sequences were determined with an ABI3100 automated DNA sequencer (Applied Biosystems Inc., Foster City, California, USA). All sequences were aligned using Clustal X 1.81 (Thompson *et al.*, 1997) and were compared to sequences retrieved from GeneBank® ([www.ncbi.nlm.nih.gov/Genbank/index.html](http://www.ncbi.nlm.nih.gov/Genbank/index.html)). Limit of detection for the PCR was determined semiquantitatively by making 1:10 dilutions of the original tissue extraction solution used to obtain DNA from one of the infected doves that yielded positive result and expressed as the reciprocal of the original concentration.

**Infection status.** Criteria for the classification of the birds based on their infection status were based upon the positive identification of mycobacteria by culture, PCR or identification of acid-fast organisms combining stained tissues or smears. Some birds had lesions suggestive of a mycobacteria infection but mycobacteria could not be detected in the lesions; these birds were not included in this study. All doves with one or more positive tests were considered infected.

**Statistics.** Results from liver biopsy, duodenal aspirate, and bone marrow aspirate together with results of liver and spleen samples collected during necropsy are presented individually and combined in tables. In the absence of standardized and published reference values for ringed-turtle doves, hematology, clinical biochemistry and plasma protein electrophoresis values were compared between both groups (infected vs. uninfected doves) and analyzed using two tailed t-student test for parametric data and Mann-Whitney test for non parametric data. Contingency tables and Fisher's exact-test or



Chi-square were used to investigate association between body weight and physical condition with infection status. Test statistics were considered significant at  $p < 0.05$ . All the statistical analysis was conducted using the formula package in Prism 5 for Windows® (GraphPad Software, Inc., available on-line at ([www.graphpad.com](http://www.graphpad.com))).

## **Results**

The character and distribution of lesions in these doves has been previously reported (Saggese et al., 2007a). The prevalence of *M. a. avium* infection in this group of doves was 62% (18/29 doves). Three additional doves were found with lesions compatible with mycobacteriosis although no organisms were detected by any means and were considered currently uninfected.

The infection status of these doves was confirmed by analysis of liver and spleen samples obtained through necropsy and using Ziehl-Neelsen staining, PCR and culture. Although other organs tested positive for acid-fast bacilli in Ziehl-Neelsen stained sections, they were not necessary to determine the infection status of these birds. Ziehl-Neelsen, PCR and culture of liver sections identified the infection status in 17/18 birds (Table 3.1). An additional infected bird was identified by examination of its spleen (Table 3.1). Polymerase chain reaction had the lowest sensitivity in testing liver samples but was higher for spleen samples, although not comparable to the sensitivity of Ziehl-Neelsen staining nor culture (Table 3.1).

Table 3.1. Comparison of sensitivity of different organ sampling and techniques for post-mortem confirmation of mycobacterial infection in 18 ring-neck doves (*Streptopelia risoria*).

| <b>Sample</b>       | Liver    | Spleen            | Combined          |
|---------------------|----------|-------------------|-------------------|
| <b>Technique</b>    | <b>%</b> | <b>%</b>          | <b>%</b>          |
| Ziehl-Neelsen       | 72.2     | 94.4              | 94.4              |
| PCR                 | 27.8     | 76.9 <sup>a</sup> | 84.6 <sup>d</sup> |
| Culture             | 88.8     | 100 <sup>b</sup>  | 100 <sup>e</sup>  |
| Ziehl-Neelsen & PCR | 72.2     | 92.3 <sup>c</sup> | 100 <sup>e</sup>  |
| All combined        | 94.4     | 100 <sup>f</sup>  | 100 <sup>f</sup>  |

a) 10/13 spleens tested by PCR; b) 15/15 spleens cultured; c) 12/13 spleens with results available for both techniques; d) 11/13 investigated by PCR; e) 15/15 livers and spleen combined; f) 13/13 spleens investigated by all techniques.

The sensitivity of different diagnostic techniques on liver biopsy samples and bone marrow aspirates is presented in Table 3.2.

Table 3.2. Comparison of sensitivity of different organ sampling and techniques used for the diagnosis of mycobacteriosis in 18 ring-neck doves (*Streptopelia risoria*).

| <b>Sample</b>       | Liver biopsy | B.M aspirate | Combined |
|---------------------|--------------|--------------|----------|
| <b>Technique</b>    | <b>%</b>     | <b>%</b>     | <b>%</b> |
| Ziehl-Neelsen       | 38.9         | 16.6         | 38.9     |
| PCR                 | 27.8         | 22.2         | 33.3     |
| Culture             | 83.3         | 72.2         | 83.3     |
| Ziehl-Neelsen & PCR | 38.9         | 22.2         | 44.4     |
| All combined        | 83.3         | 72.2         | 83.3     |

No false positive results were obtained and specificity was considered 100% for all the techniques investigated. Overall, the use of one single technique did not allow identification of all infected birds. Furthermore, a combination of techniques did not increase the overall sensitivity dramatically. The most sensitive technique was culture, both for liver biopsy samples and bone marrow aspirates. Sensitivity was low for PCR and Ziehl-Neelsen in both samples and their combination was less sensitive than cultures alone. Three infected birds would have not been identified if liver (one dove) and spleen (two doves) samples had not been investigated for mycobacteria in necropsy samples.

The sensitivity of acid-fast staining and PCR from duodenal aspirates was very low (Table 3.3). No additional infected doves were identified in addition to those already detected by liver biopsy and bone marrow aspiration by investigating the duodenal aspirates.

Table 3.3. Sensitivity for duodenal aspirates samples for the diagnosis of mycobacteriosis in 18 ring-neck doves (*Streptopelia risoria*).

| <b>Sample</b>          | Duodenal Aspirate |
|------------------------|-------------------|
| <b>Technique</b>       |                   |
| Ziehl-Neelsen (smears) | 5.8               |
| PCR                    | 35.3              |
| All combined           | 35.3              |

Physical condition was determined by examination and scoring the pectoral body mass. All uninfected birds were in good physical condition. Twelve of eighteen infected doves were classified as being in poor or fair condition and the rest were scored as being in good condition. Poor condition score was significantly associated with infection.

The mean  $\pm$  SD body weight of all doves was  $153.46 \pm 21.11$  g. The mean  $\pm$  SD weight of infected birds ( $156.3 \pm 6.325$  g) was higher but not significantly different than the average  $\pm$  SD weight of uninfected doves ( $149.8 \pm 4.038$  g). The peritoneal and perihepatic spaces of many doves contained a significant volume of liquid exudate and although these doves had pectoral muscle atrophy, this fluid accumulation brought their weight back into the range of the normal doves.

Hematological and biochemical values were available for some but not all the birds investigated due to variation in the amount of blood obtained and quality of blood smears. Analysis of the packed cell volume of thirteen infected doves revealed a mean  $\pm$  SD value of  $32.38 \pm 3.7$  % (range: 11 – 49%). This was significantly lower than the value observed in eleven uninfected doves ( $41.9 \pm 1.7$  %; range: 30-49%). Additional hematological data was available for ten infected and eight uninfected doves. The white blood cell count was significantly higher in infected birds ( $23320 \pm 4234$  wbc/ $\mu$ l; range: 8746-42,466 wbc/ $\mu$ l) than in uninfected doves ( $10720 \pm 1033$  wbc/ $\mu$ l; range 7200-15600 wbc/ $\mu$ l).

The mean  $\pm$  SD absolute count of heterophils in infected doves was  $11,380 \pm 1,722$  heterophils/ $\mu$ l (range: 3,410-20,400), this was significantly higher than the mean  $\pm$  SD count in uninfected doves ( $4,875 \pm 694.6$  heterophils/ $\mu$ l; range: 1,913-7,494 heterophils/ $\mu$ l). No statistically significant differences were observed in the number of lymphocytes between infected ( $6,312 \pm 1661$  lymphocytes/ $\mu$ l; range: 1,688-17,411 lymphocytes/ $\mu$ l) and uninfected doves ( $5,212 \pm 690.8$  lymphocytes/ $\mu$ l; range: 2,780-8,268 lymphocytes/ $\mu$ l). A significantly larger monocyte count was observed in infected doves ( $5604 \pm 1561$  monocytes/ $\mu$ l; range: 1592-13,504 monocytes/ $\mu$ l) compared with the uninfected ( $662 \pm 179.8$  wbc/ $\mu$ l; range: 270-1813 monocytes/ $\mu$ l).

Mean values of aspartate aminotransferase, creatinine kinase and uric acid values for the infected and uninfected birds were not statistically different (Appendix A). The mean total protein and mean globulin concentrations were significantly higher and mean albumin concentration was significantly lower in the infected doves compared with the uninfected (Appendix A). Results of plasma protein electrophoresis showed a significantly higher average plasma concentration of the alpha, beta and gamma globulins in the infected doves compared with the uninfected (Appendix A).

## **Discussion**

Most of the reports on the value of physical findings and various diagnostic assays for the diagnosis of mycobacteriosis in birds have been based on a case report or a series of case reports that often involve multiple species of birds. Rarely has the lesion

distribution of the cases or mycobacterial species infecting the birds been known in these reports. Additionally, with the exception of an infection trial in Japanese quail (*Coturnix c. japonica*) (Tell *et al.*, 2001), there have been no studies on the comparative value of different diagnostic assays, either individually or in combination in a group of birds whose infection status was clearly defined. In this study we were able to determine the usefulness of commonly used diagnostic techniques for mycobacteriosis in ring-neck doves naturally infected with a single genotype of *Mycobacterium a. avium*.

Birds with mycobacteriosis are reported to show a number of signs. The most common sign seen in these doves was pectoral muscle wasting, which is consistent with the observations of others and the fact that mycobacterial infections cause chronic disease. Despite the loss of muscle mass, weight loss by itself was not a useful indicator of disease because many infected birds had a substantial volume of intraperitoneal fluid increasing their weight. Abdominal effusion is an uncommonly reported sign in the literature, but was seen frequently in these doves and in ring-neck doves from a previous report.

Diagnostic imaging is another technique that would be useful in identifying infected birds. These techniques could not be used in this study as the infected birds could not be taken out of the isolation building in which they were housed.

There are few published reports describing the normal hematological parameters in ring-necked doves. Based on the values obtained from the normal doves in this experiment, the low end of the normal range for PCVs is maximally 30% and the maximum total wbc, heterophil, lymphocyte, and monocyte counts are 16,000 cells/ $\mu$ l, 7,200 cells/ $\mu$ l, 8,300 cells/ $\mu$ l and 1,900 cells/ $\mu$ l respectively.

Anemia, a moderate to marked leucocytosis with a heterophilia, and monocytosis are common findings in avian mycobacteriosis (Bush *et al.*, 1978; Hawkey *et al.*, 1990; Dorrenstein *et al.*, 1996; Van der Heyden 1997; Tell *et al.*, 2001; Pollock 2006; Travis *et al.*, 2007). Anemia, heterophila and monocytosis, however, are not specific, and these types of changes could also be caused by other chronic diseases (Campbell and Ellis, 2007).

Aspartate aminotransferase, creatinine phosphokinase and uric acid were not useful indicators of infection in these doves. These findings are in agreement with others reports where these values were not consistently elevated in birds with mycobacteriosis either (Dorrenstein 1996; Van der Heyden, 1997, Tell *et al.*, 2001). The absence of aspartate aminotransferase elevation in the face of significant liver disease may reflect the fact that the liver lesions were chronic and in many cases necrosis of hepatocytes was not ongoing. Indicators of chronic liver disease, like elevations in bile acids or the gamma glutamyl transferase, may prove to be more useful in detecting liver disease caused by mycobacterial infections.

The serum electrophoresis proved to be a sensitive indicator of infection. Infected birds usually had elevations in alpha, beta, or gamma globulins or a combination of one or more of these. These changes are consistent with finding in other species of birds with mycobacteriosis. Increased plasma total protein and globulins accompanied by reduced plasma concentration of albumin was found in many infected doves and this is consistent with what has been reported in other species of birds (Werner and Reavill 1999; Cray *et al.*, 2001; 2004). Although a nonspecific finding, electrophoretic changes were consistently present in the infected doves.

Ziehl-Neelsen staining of bone marrow aspirates is an easy, economic and relatively noninvasive technique that could be used in birds with mycobacteria. However, it does not appear to be a very sensitive assay, as only 7 of 15 birds in this study had mycobacteria in their bone marrow.

Other noninvasive techniques available to practitioners include Ziehl-Neelsen staining of fecal smears and PCR of DNA extracted from feces. Previous experiments in Japanese quail with *M. avium*, showed that the sensitivity for Ziehl-Neelsen staining of feces was only 7.2% and the sensitivity of PCR of feces was only 20.3% (Tell *et al.*, 2003b). Because of the low sensitivity of these techniques and the possibility of false positive results from Ziehl-Neelsen staining of feces, we did not include these assays in our study.



Two invasive diagnostic assays were examined in this study, liver biopsy and intestinal aspirate. Liver biopsy and intestinal aspirates are readily done through a single abdominal incision. Histological examination of the liver biopsy and acid fast staining of the intestinal aspirates, even when combined, failed to detect the majority of the infected birds. This is in no doubt do to uneven distribution of the lesions seen in these doves and to variations in the numbers of mycobacterias observed in the livers of these birds. Biopsy techniques for the spleen have been described. Given that more doves had splenic lesions than liver lesions, splenic biopsy should be considered as an alternative diagnostic assay for birds with mycobacteriosis.

PCR and culture are two techniques that have the potential to increase the sensitivity of a liver biopsy and bone marrow or intestinal aspirate. In our hands, PCR was consistently less sensitive than Ziehl-Neelsen staining and only detected Ziehl-Neelsen positive samples. Therefore, PCR would not add additional diagnostic value in liver and bone marrow of these doves. Why PCR lacked the sensitivity that might have been expected is not known. Only small samples of material were used in comparison with samples used for culturing and it may have been that the number of organisms in these small samples was very small, or absent in some cases altogether. Different results may have been obtained if an even distribution of organisms or larger numbers of them would have been present in these organs.

In contrast, culture proved to be a valuable addition to Ziehl-Neelsen staining markedly increasing the number of infected doves that could be detected by liver biopsy to 83.3% and bone marrow aspiration to 72.2% of the infected birds. A significant limitation of culture is the prolonged time required for mycobacteria to grow to detectable levels (Tell *et al.*, 2001; Mahon *et al.*, 2007; Converse, 2007). In this case, however, we could confirm infection in as little as 3 weeks. This would suggest that in cases where mycobacteriosis is suspected a liver or splenic biopsy or bone marrow aspirate could be done with part of the collected sample Ziehl-Neelsen stained and the remaining tissue frozen. If the sample was found to be Ziehl-Neelsen negative, then the frozen tissue could be cultured. Not all species mycobacteria grow as readily as the one isolated from these doves. Species like *M. genavense* have been increasingly reported in birds with mycobacteriosis (Hoop *et al.*, 1996; Pollock, 2006). This organism may take up to three to six months to grow and only in very specific medium (Reallini *et al.*, 1999), therefore variation in the ability to culture other organisms from tissue are to be expected. The use of polymerase chain reaction in these cases may accelerate the diagnosis of mycobacteriosis in the case it turns positive. However, it is necessary to keep in mind that false negative results can occur with all these techniques.

Three birds had mycobacterial infection that required the examination of a large number of liver and spleen sections obtained by necropsy before a diagnosis could be made. In two of these three doves mycobacteria were identified by examining Ziehl-Neelsen stained sections or by culture of liver and spleen. The third bird was negative in all the

liver sections examined but was positive in the spleen. These results demonstrate that definitive diagnosis was not possible in 100% of the birds even when organs usually affected by mycobacteriosis are sampled.

In conclusion, many ring-neck doves with mycobacteriosis will show pectoral muscle atrophy and a significant number of birds will also have abdominal distention as the result of an abdominal effusion. The large majority of doves will also have significant changes in the PCV and white blood cell counts, as well as changes in their serum electrophoresis. Spleen biopsies followed by liver biopsies have the greatest potential for demonstrating the organisms with Ziehl-Neelsen staining. Culturing spleen or liver biopsies or bone marrow aspirates significantly increased the chance that a diagnosis of mycobacteriosis can be made.

CHAPTER IV  
EVALUATION OF MULTI-DRUG THERAPY WITH AZITHROMYCIN, RIFAMPIN  
AND ETHAMBUTOL FOR THE TREATMENT OF RING-NECK DOVES  
(*STREPTOPELIA RISORIA*) NATURALLY INFECTED WITH AVIAN  
MYCOBACTERIOSIS

**Introduction**

Debate about the management of confirmed cases of avian mycobacteriosis exists among avian practitioners (Rupley, 1997; Pollock, 2006). Euthanasia is usually recommended (Dorrenstein et al., 1996; Forbes, 1996; Gerlach, 1997; Tell *et al.*, 2001; Pollock, 2006) based in the zoonotic risk of mycobacterial infections for the immunocompromised, children and the elderly as well as the expensive and prolonged course of multi-drug therapy that most mycobacterial infections require. Additional problems include the difficulty of drug administration to avian patients, antimicrobial drug resistance in many isolates and poor owner compliance (Gerlach, 1997; Tell *et al.*, 2001; Pollock, 2006). Conversely, treatment has been administered based on owner's requests and the importance of the bird or collection with respect to its economic value or conservation status (Roskopf *et al.*, 1989; Van der Heyden, 1997; Lennox, 2002). Nevertheless, no consensus exists among avian clinicians regarding the decision to treat this disease. The potential or real zoonotic risk of mycobacterial infections is one important factor at the time to take a decision, although sometimes not fully understood. The subspecies of *Mycobacterium avium* that infects humans (*M. avium hominissuis*) seems to be different

to the subspecies affecting birds (*M. a. avium*) (Mijs *et al.*, 2002; Mobius *et al.*, 2006; Johansen *et al.*, 2007), but other mycobacterias such as *M. genavense*, *M. tuberculosis*, *M. simiae*, and *M. celatum* have been increasingly identified as cause of disease in birds and in humans (Hoops *et al.*, 1996; Katoch, 2004; Steinmetz *et al.*, 2006, Bertelsen *et al.*, 2006, Travis *et al.*, 2007). There are no molecular studies that have investigated genetic or phenotypic differences between these organisms affecting birds and humans, with the exception of *M. avium* (Mijs *et al.*, 2002; Johansen *et al.*, 2007). In this species, isolates from humans and pigs differ from avian isolates, suggesting that the zoonotic risk may be very low, although concurrent infection with *M. a. avium* and *M. a. hominissuis* has been identified in aquatic birds with mycobacteriosis (Dvorska *et al.*, 2007). Then, the phenotypic and molecular identification of the mycobacteria involved in an outbreak may be important when considering treatment of a bird in order to prevent emergence and selection of resistant strains that may affect also humans.

There are very few published reports of attempts to treat affected birds. Such reports usually involve only a limited number of birds and consist mainly of clinical cases (Roskopf *et al.*, 1989; Ven der Heyden, 1997; Lennox, 2002). A wide range of antibiotics, doses and length of therapy have been recommended (Van der Heyden, 1997; Lennox, 2002; Carpenter *et al.*, 2005; Pollock, 2006). Most of these regimens have been extrapolated from the human pediatric literature, calculated by metabolic allometrical scaling, or based on anecdotal reports (Roskopf *et al.*, 1989; Beynon, 1996; Van der Heyden, 1997; Carpenter, 2005; Pollock, 2006). More than fifteen anti-

mycobacterial drugs and combinations have been recommended to treat avian mycobacteriosis (Roskopf *et al.*, 1989; Van der Heyden, 1997; Carpenter *et al.*, 2005; Pollock, 2006), although their efficacy is unknown.

Non-tuberculous mycobacterial infection in humans is a common problem in AIDS patients (Bieth *et al.*, 2005). Treatment regimens using one of the new macrolide antibiotics, azithromycin or clarithromycin, in combination with ethambutol and rifampicines (rifampin or rifabutine) appears to be more effective in the treatment of *M. avium* infection in AIDS patients than older combinations of drugs (Katoch, 2004, Griffith, 2007). If true, this combination of drugs may also be more effective in birds. A similar protocol has therefore been recommended for birds (Van der Heyden, 1997; Phalen, 2000; Carpenter *et al.*, 2005).

Successful treatment in birds may depend on the organism's susceptibility to the antibiotics, extent and localization of infection and the immune response of the patient. Measures of treatment success have been judged by the improvement or resolution of clinical signs, the absence of acid fast organisms, and negative cultures and/or PCR results in liver biopsies obtained at the end of treatment (Roskopf *et al.*, 1989; Beynon, 1996; Van der Heyden, 1997; Lennox, 2002). Nevertheless, the sensitivity of liver biopsy and clinical improvement as a measure of treatment efficacy has not been investigated.

Mycobacteriosis caused by *M. a. avium* and *M. genavense* is a multi-systemic disease in birds. Liver, spleen, bone marrow, intestines are typically the main organs affected. While liver samples can be obtained by surgical or laparoscopic biopsy, they provide no information about the presence of lesions or mycobacteria in other organs. Our finding of mycobacteria-free liver sections in naturally infected ring-neck doves that were positive in spleen and other organs (Saggese and Phalen, 2005; Saggese *et al.*, 2007b) raises concern about the sensitivity of using a single organ like the liver (Lennox, 2002) to evaluate treatment.

An important issue regarding treatment of avian mycobacteriosis is the absence of studies to assess the adverse effects of multiple-drug treatment protocols. Most anti-mycobacterial drugs have adverse effects. Rifampicins may induce hepatic microsomal enzymes, ethambutol has been associated with the development of optic neuritis and macrolides may cause diarrhea (Hershfield, 1999; Griffith, 2007).

Another important and uninvestigated area in birds receiving treatment includes the development of drug resistance. It is a common complication of treatment of humans with mycobacterial infections (Cole *et al.*, 2004). Multiple drug treatment is necessary to prevent the selection of drug-resistant mutants during therapy (Tomioka, 2004). Most isolates of *M. avium* have natural and acquired resistant to many antimycobacterial drugs (Tomioka, 2004). Development of antibiotic resistance has not yet been investigated in birds with mycobacteriosis after therapy. Development of drug resistance in human

mycobacteriosis usually occurs due to lack of compliance (Cole *et al.*, 2004 ), so the same commitment and compliance of the owner regarding treatment of avian pets is essential for a successful outcome (Tell *et al.*, 2001). In humans, multi-drug resistance is an increasing and emerging problem (Cole *et al.*, 2004) and given the zoonotic risk of mycobacterial infections it is essential to investigate the possible presence of natural and/or acquired drug-resistance in avian clinical isolates.

This study was undertaken to determine if a multi-drug treatment regimen consisting of azithromycin, ethambutol and rifampin will cure ring-neck doves naturally infected with *Mycobacterium a. avium*. We also sought to determine if this treatment protocol would be free of adverse effects, if the mycobacteria would develop antibiotic resistance and if a liver biopsy at the end of treatment could be used to assess the treatments success.

## **Materials and Methods**

**Specimens.** Seventy adult ring-neck dove doves were obtained from an aviary near Hillsboro, Texas, in July 2005. These birds came from a flock where more than 60 doves had died during the previous six months. Mycobacterial infection had been previously confirmed in these birds at the Texas Veterinary Medical Diagnostic Laboratory (College Station, TX, USA) and the condition of some of the surviving birds (decreased productivity, weight loss, depression) was consistent with a chronic infectious disease such as mycobacteriosis. These birds were all housed in a small shed that was open to and surrounded on 2 sides by an outdoor flight. There was heavy fecal contamination of



the floor and perching surfaces of the shed. Food and water were contaminated with feces. The surviving birds were donated and transferred to an isolation building at the College of Veterinary Medicine and Biomedical Sciences, Texas A&M University, College Station, TX, USA. The pathology, etiology, differential susceptibility to disease and efficacy of different diagnostic methods was investigated in 29 of these birds and was reported elsewhere (Saggese *et al.*, 2007a; 2007b).

Twenty one ring-neck doves were included in this study. Infectious status was based on the prevalence of mycobacterial infection (62%) in the previously euthanized group of 29 doves (Saggese *et al.*, 2007a), results from a Western blot test (Gray *et al.*, unpublished) and results of hematology and plasma protein electrophoresis (Saggese *et al.*, 2007b). Criteria for their inclusion in the study and presumptive classification as infected included the combination of three or more of the following results: positive Western blot, anemia, leucocytosis, heterophilia, monocytosis, hyperglobulinemia and hypoalbuminemia. These were all consistent findings in the previously investigated infected group (Saggese *et al.*, 2007a; 2007b).

**Treatment protocol.** The birds were housed in wire cages in groups of 5 to 8 in a biological level 3 isolation building. Birds were identified by a numbered band placed around the tarsus-metatarsus. Water and mixed seeds were offered *ad libitum*. Birds were administered a combination of rifampin USP (45 mg/kg; Gallipot Inc, St. Paul, Minnesota), azithromycin (43 mg/kg; Zithromax® oral suspension 1 g, Pfizer Inc, New

York, NY) and ethambutol (30mg/kg; Ethambutol Hydrochloride tablets, USP 100 mg, Versapharm Inc, Marietta, GA) *per os* once a day for 180 days following recommended dosage (Van der Heyden, 1997; Pollock, 2006). The three medications were prepared and mixed in 1 ml of syrup immediately before administration and given by direct administration into the crop using a 1 ml syringe. Each bird was examined daily when they were handled for treatment and weighed every four weeks. Birds that developed a debilitating condition or showed signs of depression, stupor or coma, severe dyspnea, pain or prolonged anorexia during the treatment period were euthanized.

**Treatment evaluation.** At the end of the treatment all surviving doves were anesthetized with an intramuscular injection of ketamine/xylazine and euthanized by exsanguinations by cardiocentesis. Birds were necropsied within four hours of euthanasia. Representative sections of liver, spleen, lung, and bone marrow were collected for PCR and culture. Representative sections of liver, spleen, heart, lung, air sacs, kidney, intestines, gonads, adrenal gland, thyroid gland, trachea, esophagus, ventricle, proventriculus, crop, skeletal muscle and bone marrow were fixed in 10% buffered formalin and stained with hematoxylin/eosin and Ziehl-Neelsen stain. Birds were considered cured if there were no macroscopic and microscopic lesions consistent with active mycobacteriosis in any organ, the liver, spleen and bone marrow were culture and PCR negative, and acid-fast organisms were not seen in Ziehl-Neelsen stained sections.

Immediately after the birds were euthanized, tissue samples were collected using the biopsy techniques used in live birds. Bone marrow aspirates, using a 20 G needle and 6 ml syringe, were obtained from the distal ulna and saved at  $-80^{\circ}\text{C}$ . The celomic cavity was opened aseptically through a midline ventral approach and a piece of liver approximately 4 x 4 x 4 mm was excised from the caudal border of the right lobe. This is the location and size of tissue that would be collected from a live bird of this size during a routine liver biopsy. A small portion was saved for PCR and culture, and the remaining tissue formalin-fixed for histological examination. Bone marrow aspirates and “biopsied” liver were cultured and tested by PCR. Liver biopsies were additionally investigated by Ziehl-Neelsen staining.

**Microscopic lesions.** Microscopically, inflammatory lesions were scored semiquantitatively as mild, moderate and severe based on the amount of inflammatory cells within the lesions and the area of tissue affected. Histopathological changes compatible with mycobacteriosis were either classified as focal/multifocal granulomatous, consisting of a well defined foci of inflammatory cells, sometimes surrounded by a ring of fibrous tissue and with or without variable amounts of central caseous necrosis, or classified as diffuse granulomatous inflammation, with a variable degree of diffuse inflammatory cell infiltration without formation of discrete foci or nodules, absence of a fibrous capsule and little or no caseous necrosis. The numbers of acid-fast bacilli were subjectively graded as none, few, many or massive. Congo red staining was used to investigate the presence of amyloid in liver and spleen.

**Identification of mycobacteria in tissues.** Swabs from macerated liver, spleen, lung and bone marrow from all the doves investigated were inoculated into 5 ml of Middlebrock 7H9 broth (Beckton Dickinson, Franklin Lakes, New Jersey, USA) containing 0.5% (v/v) glycerol and 10% (v/v) oleic acid-albumin, and incubated at 39 °C (Mahon *et al.*, 2007). Cultures were inspected weekly for microbial growth and examined for the presence of mycobacteria by Ziehl-Neelsen staining.

DNA was extracted from all affected tissues and isolates using the Puregene® Genomic DNA Purification Kit (Gentra Systems, Minneapolis, Minnesota, USA) following the instructions of the manufacturer. PCR screening for mycobacterial DNA was performed using primers T1 [5'-GGGTGACGCG(G/A)CATGGCCCA-3'] and T2: [5'-CGGGTTTCGTCGTACTIONCCTT-3'] for amplification of the 236 bp *dnaJ* gene as described by Morita *et al.*, (2004). The PCR reaction parameters were as follows: one initial cycle of 94° for 5m; 40 cycles at 94° for 30s, 60° for 45s and 72° for 1m; and an additional elongation step at 72° for 5m. Positive (*M. avium*) and negative reaction control (DNA-RNA free sterile water) were utilized in each reaction. Amplified DNA was visualized after electrophoresis on a 1.5% ethidium bromide-stained agarose gel. PCR products were purified using QIAquick PCR Purification Kit (Qiagen Inc., Valencia, California, USA). Sequencing reactions were performed using an ABI Prism® Big Dye Terminator v3.0 Cycle Sequencing Kit (Applied Biosystems Inc., Foster City, California, USA). Nucleotide sequences were determined with an ABI3100 automated DNA sequencer (Applied Biosystems Inc., Foster City, California, USA). All sequences

were aligned using Clustal X 1.81 (Thompson *et al.*, 1997) and were compared to sequences retrieved from GeneBank® ([www.ncbi.nlm.nih.gov/Genbank/index.html](http://www.ncbi.nlm.nih.gov/Genbank/index.html)).

**Investigation of adverse effects.** An additional group of six, outwardly healthy, doves that had been housed at the Schubot aviary for the previous 6 years were used to investigate changes in PCV, white blood cells count, plasma protein, body mass and ethambutol-induced optic neuritis associated with this treatment. They were considered free of mycobacterial infection by Western blot analysis (Gray *et al.*, unpublished), lack of clinical signs, normal hematology and clinical biochemistry and by the absence of mycobacteriosis in the aviary where they were housed during these previous years. These birds were treated and monitored in the same way as the naturally infected birds. Blood was sampled at day 0, 60, 120 and 180. Blood was collected from the basilic vein. Blood smears were made immediately, the remaining blood refrigerated and the packed cell volume was measured within two hours of collection. Packed cell volume and estimated white blood cell count were performed as described (Campbell and Ellis, 2007). Aspartate aminotransferase, creatinine kinase, uric acid, albumin and total protein analysis were performed at the Clinical Pathology Laboratory, Department of Pathobiology, College of Veterinary Medicine, Texas A&M University. Plasma protein electrophoresis was performed using the Titan Gel electrophoresis kit (Helena Laboratory, Beaumont, Texas,) following manufacture's instructions. The birds' response to therapy was monitored by comparing changes in packed cell volume, white blood cell counts, total protein, albumin, globulin, albumin/globulin ratio, uric acid,

aspartate aminotransferase, creatinine kinase, plasma protein electrophoresis and monthly weight. Increases in aspartate aminotransferase, creatinine kinase and uric acid plasma concentrations, changes in plasma protein values, presence of optic neuritis or the onset of gastrointestinal signs (diarrhea, anorexia, vomiting and weight loss) were considered signs of adverse effects and/or drug toxicity. After 180 days treatment control birds were euthanized and samples collected and analyzed as previously described for the sick birds to further investigate them for mycobacteria and gross mortem changes.

Selected liver and spleen tissues samples from four untreated and four treated doves positive for culture were additionally submitted to the laboratory of mycobacteriosis at the National Jewish Medical and Research Center, Colorado, for the investigation of antibiotic susceptibility for the three drugs investigated.

This research was approved by the ULACC/IAACUC at Texas A&M University (animal use protocol 2005-56).

## **Results**

**Infection status before the treatment.** Sixteen birds were considered infected at the beginning of the treatment, based on positive Western blot results, leucocytosis, heterophilia and monocytosis, anemia, and increased plasma protein concentrations (data not shown). Four birds with negative Western blots and white blood cell counts within normal limits ( $< 15000$  wbc/ $\mu$ l) were considered uninfected (Saggese *et al.*, 2007b). One

additional bird was considered suspect due to the presence of anemia, leucocytosis, heterophilia and monocytosis but negative Western blot. These five birds were not included with the group that was considered infected although they received the same treatment for a similar time. Information on these birds is presented apart from the information for these sixteen infected doves.

**Survival.** Eleven (68.75%) of the sixteen infected birds that initiated multi-drug therapy survived until the last day of treatment (Figure 4.1).

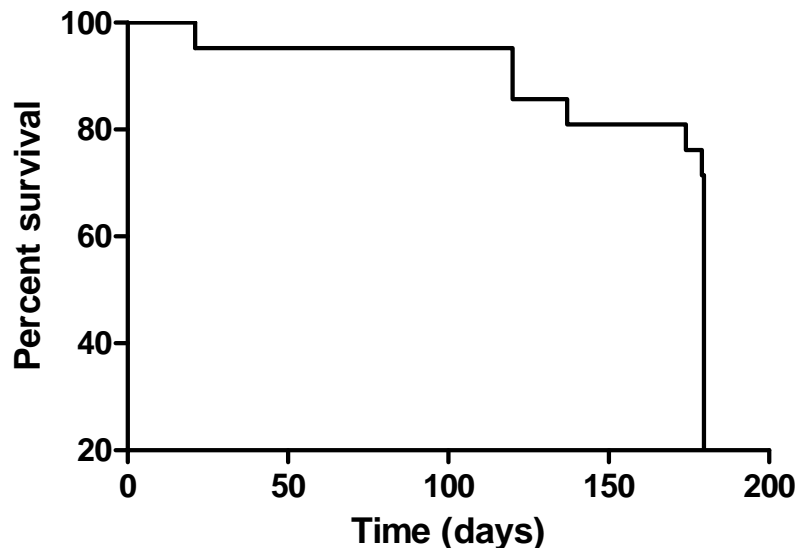


Figure 4.1. Survival rate of sixteen ringed-turtle doves (*Streptopelia risoria*) with spontaneous mycobacteriosis receiving azithromycin, ethambutol and rifampin for six months.

One bird died early in the course of treatment. It was in a poor condition, was severely underweight and anemic when treatment started. On post-mortem investigation its infected status was confirmed by the presence of granulomatous hepatitis, splenitis, enteritis and pneumonia. Massive numbers of acid fast organisms were observed in these lesions.

One moribund bird that was found lying on its breast with severe dyspnea at day 120 was euthanized. An additional bird died after the same duration of treatment. In both cases, death was attributed to mycobacteriosis due the presence of granulomatous inflammatory lesions in liver, spleen and lung and the identification of acid-fast organisms.

The last two birds died shortly before the end of the treatment. One was a sexually active male (testes 10 mm x 5 mm) in good physical condition, including abundant abdominal and coronary groove fat. It died seven days before the end of the study. The other bird was found dead one day before the end of the study. The ventral surface of the livers of both birds was surrounded by a gelatinous, serosanguineous exudate. Microscopic examination confirmed mycobacteriosis in both birds based on the presence of granulomatous inflammation and moderate to massive numbers of acid fast organisms, positive culture and PCR. The four birds that were not thought to be infected and the bird that was suspected to be infected but did not meet the initial criteria survived the six months of treatment.

**Infection status in surviving birds.** Mycobacteria were identified on post mortem examination in nine of the eleven birds that received the complete treatment for 180 days. A combination of multiple organ examination with Ziehl-Neelsen staining, culture and PCR of liver, spleen, bone marrow and lung was necessary to detect the mycobacteria. Ziehl-Neelsen staining of large section of tissues was the most sensitive



technique used to determine their post-mortem infection status. Nine infected birds were identified with this technique. Sensitivity of each technique for those birds with confirmed mycobacterial infection at the end of treatment is shown in Table 4.1. No single organ or technique consistently yielded positive identification of mycobacteria.

Table 4.1. Comparison of sensitivity of different organ sampling and techniques used for the diagnosis of mycobacteriosis in 11 ring neck doves (*Streptopelia risoria*) with spontaneous mycobacteriosis and treated with azithromycin, ethambutol and rifampin for six months.

| Technique     | Liver | Spleen | Lung  | Bone marrow | Liver biopsy | Combined |
|---------------|-------|--------|-------|-------------|--------------|----------|
| Ziehl-Neelsen | 9%    | 45.5%  | 27.3% | 0%          | 9%           | 90.1%    |
| Culture       | 18.2% | 45.5%  | 0%    | 9%          | 18.2%        | 54.5%    |
| PCR           | 9%    | 27.3%  | ----  | 0%          | 0%           | 36.4%    |
| Combined      | 27.3% | 61.5%  | 27.3% | 9%          | 27.3%        | 100%     |

The sequences of the amplified *dnaJ* gene for 4 isolates obtained after treatment were identical to the sequences of previously identified isolates in confirmed infected doves (Saggese *et al.*, 2007a) and had 100% identity with the sequovar of *Mycobacterium a. avium* that contains serotypes 2, 3, 4 and 9 (Morita *et al.*, 2004).

Only two birds were considered free of infection at the end of treatment based on Ziehl-Neelsen staining, culture and PCR. However, mild multifocal inflammation was observed in the liver and spleen of these birds. Three of four birds considered uninfected at the beginning of treatment were considered negative after post mortem examination and testing. However, one of the previously considered uninfected birds was positive upon examination and culture of its spleen (but negative for all other tissues examined).

Those birds that remained infected had a limited distribution of microorganisms. The spleen was most commonly infected. Eight birds were identified by lesions in the spleen only, while the lung, liver and ovary were needed to confirm infection in two, two and one birds respectively. Furthermore, the single suspect bird at the beginning of treatment was found positive for mycobacteria by bone marrow culture only and multifocal granulomatous splenitis inflammation was observed in all but one.

**Gross and microscopic lesions.** Of the eleven birds that survived treatment, five were females and six were males. All had active gonads. All but two had good pectoral muscle condition and were alert, eating well and responsive to handling and oral administration of the drugs during all the treatment period.

Minor and mild gross lesions characteristic of mycobacteriosis was observed in nine of the eleven birds (81.8%). The most common organ affected was the spleen. Two birds had a severely enlarged spleen with multiple coalescing yellow nodules. Otherwise, the size of the spleen in the remaining birds was only two to three times the size of this organ in a normal bird with very small yellow miliary foci embedded in the parenchyma (Figure 4.2).

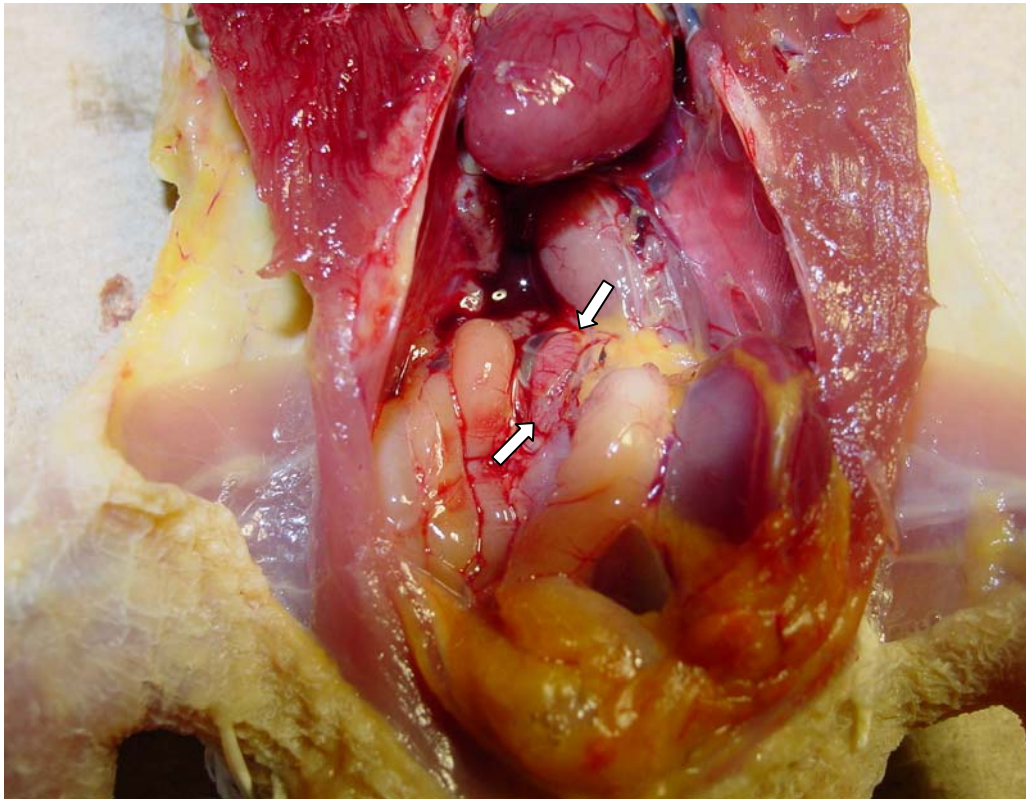


Figure 4.2. Mild splenomegaly (arrows) in a ring-neck doves (*Streptopelia risoria*) after six months of treatment.

Hepatomegaly (three birds), discoloration (five birds) and small yellow foci (one bird) were observed. Two birds had liver of normal appearance. A single yellow caseous nodule was observed in the lung of one bird while another one had small yellow nodules in an air sac. Kidneys were pale in three birds and enlarged and edematous in two. Other isolated lesions included a small yellow nodule in the serosal surface of the ventricle, a neck granuloma and a subcutaneous granuloma in the head. One of the head lesions caused skin ulceration. Another mass was located in the infraorbital sinus space. These lesions in the head did not regress during treatment (Figure 4.3), although another mass

located dorsolaterally to the uropygium was observed at the beginning of the treatment but disappear after six months.

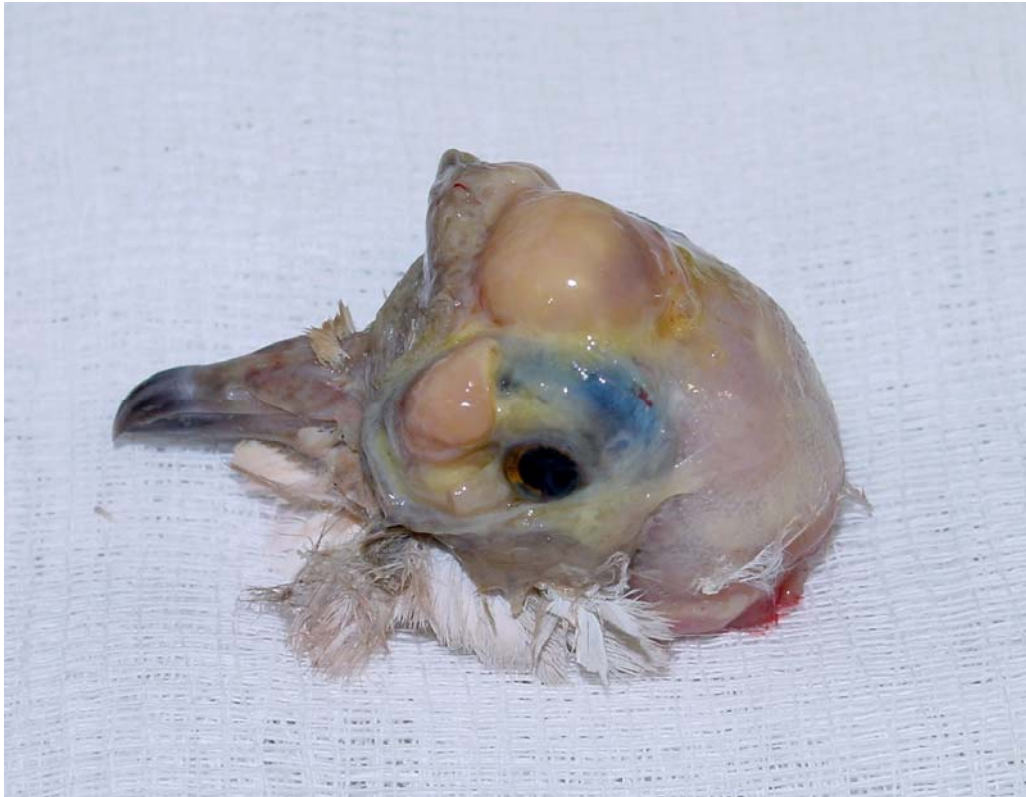

Figure 4.3. Head and infra-orbital subcutaneous granulomatous lesions in a ring-neck dove (*Streptopelia risoria*) after six months of treatment.

Lesions attributable to mycobacteria were not observed in the pancreas, intestines, brain, cerebellum, gonads, trachea, esophagus, proventriculus or bone marrow.

One of the birds considered uninfected at the beginning of the treatment had a small yellow foci of 0.5 x 0.5 x 1.5 mm of diameter embedded in the otherwise relatively normal sized spleen. The other three birds did not present significant lesions suggestive of mycobacteriosis at the end of treatment.

Microscopic lesions were observed principally in the liver, spleen and lung and sporadically in the bone marrow and ovary. Liver lesions were observed in all the birds. Both diffuse and multifocal hepatitis and splenitis were observed. Focal or multifocal lesions were considered mild to moderate while those birds with a diffuse pattern moderate or severe inflammation predominated. A combined pattern of diffuse and multifocal granulomatous inflammation was observed in one liver. Amyloid deposits were identified in the livers in four birds with diffuse inflammation. Classic tuberculous granulomas with histiocytes or multinucleated giant cells and fibrosis, surrounding a central core of necrosis, were prominent in four spleens, two livers, three lungs and one ovary. A mild or moderate chronic and/or active-chronic form of multi-focal granulomatous hepatitis was observed in all the birds, including those considered uninfected (Figure 4.4).

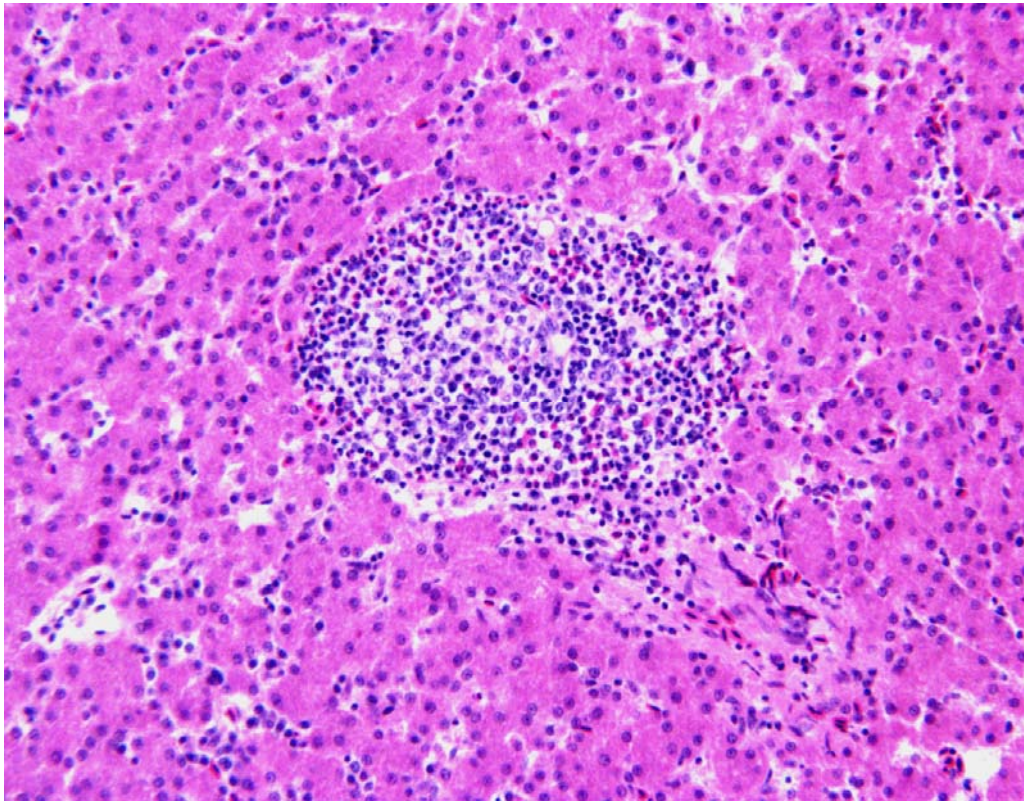


Figure 4.4. Mild active-chronic granulomatous hepatitis.

Few to massive acid-fast organisms were almost completely restricted to the central core of necrosis observed in the granulomatous foci of the spleen, liver, lung and ovary. Other sections of these tissues, including those foci without caseous central core or with diffuse inflammation, usually lacked organisms.

**Efficacy of liver biopsy.** Acid-fast organisms were only identified in one bird in liver biopsies. The liver biopsy of two additional birds was cultural positive. The liver biopsies for all of the other birds were negative for mycobacteria for all the techniques.

**Optic nerve examination.** Ten doves that received treatment were investigated for the presence of inflammation and/or demyelination of the optic nerve. No significant pathological changes were detected in any of them.

**Antibiotics susceptibility.** Two samples submitted to the National Jewish Medical and Research Center were cultured, identified as *M. avium* by high performance liquid chromatography and their sensitivity investigated. One sample was obtained from a dove that did not receive treatment and the other sample obtained from a treated dove. Both yielded organisms susceptible to azithromycin, resistant to ethambutol and showed intermediate resistance to rifampin. The remaining six samples failed to grow microorganisms.

**Healthy doves and adverse effects.** All six healthy doves survived the duration of the treatment. On necropsy, their physical condition was considered excellent. Gross necropsy and microscopic findings were unremarkable except for a localized air-sacculitis in one bird, associated with the presence of a small metallic foreign body probably inhaled. No acid-fast organisms were observed in Ziehl-Neelsen stained sections. Mycobacteria were not cultured nor detected by PCR from liver and spleen. No lesions were observed in the optic nerve of these birds.

The mean weight of these six healthy birds increased slightly from the beginning of treatment to the end, although differences in monthly mean were not statistically



significant. No significant changes were observed in packed cell volume and total plasma proteins concentrations along the course of treatment (data not shown). Changes in aspartate aminotransferase, creatinine kinase and uric acid mean plasma levels were also not significant (data not shown).

## **Discussion**

This study investigated the efficacy of drug treatment over six months in a group of ring-neck doves with spontaneous mycobacteriosis caused by *M. a. avium*. The goal of any therapy against mycobacteriosis should be the eradication of the infection status and recovery of normal function of affected organs. Treatment should also avoid development of resistance in the organisms and be free of adverse or toxic effects for the birds. A protocol that combined the administration of three antimycobacterial drugs was only effective in curing 2 of 16 (12.5%) birds included in this study. Mycobacteria still remained identifiable in several tissues, usually within the center of the granulomas. Furthermore, five out of sixteen birds died before finishing therapy and mycobacteriosis was diagnosed in all on post mortem investigation. Then, the drugs and protocol used in this study was ineffective to treat these doves. Mycobacteriosis was still affecting these birds, did not prevent dead of many of them and did not eradicate the infection status.

Reasons for this failure may be multiple. Failure of multiple-drug treatment in human tuberculosis is usually associated to poor patient compliance and/or the presence of drug resistance (Cole *et al.*, 2004). The first was not the case in this study. All the birds were



individually handled every day at the same time by especially trained personal and drugs administered by gavages directly into the crop. The presence of *in vitro* resistance to two of the three antimycobacterial drugs used in this study may be a more likely cause of treatment failure. Nevertheless, *in vitro* resistance is not always clearly linked to clinical resistance *in vivo*. The two mycobacterial isolates had *in vitro* resistance for these two drugs and suggest that resistance was natural rather than acquired. These two resistances combined could have been cause of treatment failure and anyway, highlights the need to perform an antibiotic susceptibility test before starting treatment. However, in practice, this could be difficult to achieve in a timely manner due the prolonged incubation times slow-growing mycobacterias such as *M. a. avium* needs. Against this cause of failure is the lack of mycobacteria in tissues except inside the central core of necrosis. This restricted localization of mycobacteria to the necrotic center of the tubercles suggests that these organisms could have avoided the effects of these antibiotics within this location. The presence of large numbers of bacilli within the tuberculous granulomas and the absence of mycobacteria in other locations suggests active multiplication rather than latency. Within this protected environment mycobacteria could have effectively overcome the effect of antimycobacterial drug. Extracellular or intracellular location of mycobacteria within macrophages and multinucleated giant cells was a common features in previously investigated ring-neck doves (Saggese and Phalen, 2005; Saggese *et al.*, 2007a) and a similar distribution would have been expected if mycobacterial resistance alone was the cause of failure.

Another possible explanation is that this treatment may have worked but was completed before the complete eradication of the infection. Treatments of up to one year have been advocated for tuberculosis in humans (Cole *et al.*, 2004) Evidence supporting the effectiveness of this treatment is the reduced size of the lesions observed in the birds euthanized at the end of therapy compared with those untreated birds investigated previously (Saggese *et al.*, 2007a). Lesions in the liver, spleen, bone marrow and lungs were usually mild and intestinal lesions were also absent.

Considering the main hypothesis tested in this study, that a combination of multiple-drug therapy administered for 180 days will cure these birds, it must be concluded that the treatment was a failure.

Liver biopsy and lack of identifiable mycobacteria within has been advocated as sample of choice to determine efficacy of treatment and recovery from infection in birds (Van der Heyden, 1997; Lennox, 2002; Pollock, 2006). Results of this study and from a previous one (Saggese *et al.*, 2007b) does not support this claim. Mycobacteriosis diagnosis in birds currently relay on the identification of the etiological agent in affected tissues. Given the variable distribution of lesions and mycobacteria even in the same species of birds and the different sensitivity of available diagnostic technique, a multi-organ approach and combination of different diagnostic technique is recommended (Saggese *et al.*, 2007b). Based on results of this previous study and this one, liver biopsy does not seem to reflect completely the mycobacterial status of the affected bird and

should not be used alone or as single method to confirm diagnosis or efficacy of therapy for mycobacteriosis.

The combination of azithromycine, ethambutol and rifampin at the doses used in this study appear to be well tolerated by the doves. No weight loss, optic nerve lesions, neither significant increases in the levels of aspartate aminotransferase, uric acid and creatinine kinase were observed. A steady increase observed in aspartate aminotransferase may be consistent with increased microsomal hepatic activity reported for rifampin (Tomioka, 2004). Rifampin is a semisynthetic bactericidal drug and together with ethambutol and macrolides like clarythromycine or azithromycine is a first choice for treatment of *M. avium* infections in humans (Cole *et al.*, 2004). Its mechanism of action is through inhibition of the DNA-dependant RNA polymerase and preventing transcription of mRNA and protein synthesis. Hepatotoxicity is a common adverse effect under prolonged used of this drug and microsomal cytochrome P450 enzymes induction occurs affecting the metabolism of different drugs. Monitoring of liver function is recommended in humans receiving this medication. Aspartate aminotransferase together with bile acids plasma concentration are usually evaluated to determine hepatic damage and function, respectively, in birds (Fudge, 2000). However, despite significant liver disease a significant elevation in this enzyme alone was not observed in this study.

This is the first comprehensive prospective study on the efficacy of a treatment protocol for avian mycobacteriosis caused by *M. a. avium* in a large group of birds. The

ineffectiveness of this treatment, as demonstrated by the presence of mycobacteria at least in nine out of the eleven birds and death of five of the infected birds before completion of treatment indicates that eradication of the infection status is not easy to achieve. Furthermore, this study demonstrated that liver biopsy alone is not useful to evaluate treatment efficacy. In the frame of the permanent emergence of antibiotic resistant to drugs and sometimes changes in the virulence of organisms as result of drug selection, our results highlights the importance of investigating the presence of drug resistance before starting therapy for mycobacteriosis in birds and at the end of treatment.

## CHAPTER V

CONCLUSION: GROSS AND MICROSCOPIC FINDINGS AND INVESTIGATION  
OF THE AETIOPATHOGENESIS OF MYCOBACTERIOSIS IN A CAPTIVE  
POPULATION OF WHITE-WINGED DUCKS (*CAIRINA SCUTULATA*)\***Introduction**

The white-winged duck (*Cairina scutulata*) is a severely endangered Southeast Asian species (del Hoyo *et al.*, 1992; Birdlife International, 2001, 2006). The main threats to these birds are loss of suitable habitat (wetlands and lowland tropical forest) and locally intense hunting pressure (del Hoyo *et al.*, 1992; Birdlife International, 2001, 2006). Estimates of the global population range from less than 400 to as high as a “few thousand” individuals (Evans *et al.*, 1997; Rose & Scott, 1997). Captive populations have been established at The Wildfowl and Wetlands Trust, Slimbridge, England, and at the Sylvan Heights Waterfowl Center, North Carolina, USA, in an effort to prevent the extinction of this species. The US breeding program represents the only Anseriforme Species Survival Plan of the American Zoo and Aquarium Association (AZAA). Currently, there are fewer than 100 white-winged ducks in North America and 39 in England (R. Cromie, personal communication, 2006).

---

\*This chapter has been previously published in Journal of Avian Pathology, Taylor & Francis © Houghton Trust Ltd. Reproduced here with permission of the editors. Saggese, M.D., Riggs, G., Tizard, I., G. Bratton, Taylor, R. & Phalen, D.N. (2007). Gross and microscopic findings and investigation of the aethiopathogenesis of mycobacteriosis in a captive population of white-winged ducks (*Cairina scutulata*). *Avian Pathology*, 36, 415-422.

The survival of both captive populations has been jeopardized by the high susceptibility of this species to mycobacteriosis (Cromie *et al.*, 2000; Riggs, 2005). Reports from the Wildfowl and Wetlands Trust show that during a period of 16 years up to 84% of captive white-winged duck deaths were the result of infection with *Mycobacterium avium avium* serotype 1 (Cromie *et al.*, 1991, 1992). Mycobacteriosis has also been reported in captive birds in India (Birdlife International, 2006), and recently has been recognized in white-winged ducks in the Sylvan Heights Waterfowl Center collection (Riggs, 2005). Until now, the percentage of ducks dying with mycobacteriosis at the Sylvan Height Waterfowl Center, the nature and distribution of the lesions in these birds and the mycobacterial species causing this disease have not been reported.

The reasons for this apparently high susceptibility of white-winged ducks to avian mycobacteriosis are not known, but it has been speculated that low genetic diversity, management-related problems and environmental factors may all be predisposing factors (Cromie *et al.*, 2000; Riggs, 2005). Additionally, it is possible that white-winged ducks may be more susceptible to mycobacterial infection because of immunosuppressive effects of environmental contaminants such as heavy metals (Stout *et al.*, 2002; Fairbrother *et al.*, 2004; Kalisinska *et al.*, 2004; Braune & Malone, 2006).

A successful captive breeding program for any severely endangered species depends on the development of effective disease control measures. Critical to the management of captive populations is a better understanding of the nature and severity of the disease

caused by the infection, and an understanding of the factors that lead to the apparent susceptibility of these ducks to infection. Therefore, the main goals of this study were to: 1) determine the incidence of mycobacteriosis in white-winged ducks that died at the Sylvan Heights Waterfowl Center during a 21-month period, 2) identify, by DNA sequence analysis, the species and sequevar of *Mycobacterium* infecting the ducks, 3) describe the gross lesions and histopathological changes induced by mycobacteria in these ducks, 4) evaluate liver concentrations of several heavy metals in these birds, and 5) compare the results of this study with data reported elsewhere.

## **Materials and Methods**

**Specimens.** All the white-winged ducks that died at Sylvan Heights Waterfowl Center from August 2004 to May 2006 (n = 21) were submitted for necropsy. They were submitted frozen and had been refrigerated before freezing for variable times. Those birds that were received without having been soaked or wetted previously were weighed. The liver, spleen, lung, air sac, heart, kidney, pancreas, intestine, oesophagus, ventriculus, proventriculus, trachea and skeletal muscle were consistently examined during gross necropsy. The adrenal glands, gonads, bone marrow and thyroid glands were also examined in 7, 18, 13, and 15 birds, respectively (Table 1). The brain and cerebellum were not investigated in these birds due to severe post-mortem autolysis and freezing changes. Specimens from these organs were formalin-fixed and paraffin-embedded. Sections were cut at 4  $\mu$ m and stained with hematoxylin and eosin. A second section was stained with the Ziehl-Neelsen stain. Inflammatory lesions were subjectively

graded as mild, moderate and severe based on the amount of inflammatory cells within the lesions and the area of tissue affected. The numbers of acid fast bacteria were subjectively graded as none, few, moderate, many or massive. Congo Red staining and green birefringence was employed to investigate the presence of amyloid in liver and spleen. Table 5.1 presents the organs examined histologically for each duck.

**Detection of mycobacteria in tissues.** Swabs from macerated tissues sections, either the liver or the lung, from all the ducks examined were inoculated into 5 ml of Middlebrock 7H9 broth (Beckton Dickinson, Franklin Lakes, New Jersey, USA) containing 0.5% (v/v) glycerol and 10% (v/v) oleic acid-albumin, and incubated at 39 °C for up to 4 weeks. Cultures were inspected weekly for microbial growth and examined for the presence of mycobacteria by Ziehl-Neelsen staining.

Tissues were collected for polymerase chain reaction (PCR) using cleaned, autoclaved instruments that had been treated with bleach and formalin. A different set of instruments was used to collect tissues from each bird and organ to prevent DNA carryover. Tissues were either processed immediately or stored at -80 °C until processing. Mycobacterial DNA was extracted from affected livers using the Puregene® Genomic DNA Purification Kit (Gentra Systems, Minneapolis, Minnesota, USA) following the instructions of the manufacturer. PCR screening for mycobacterial DNA was performed using primers T1 [5'-GGGTGACGCG(G/A)CATGGCCCA-3'] and T2: [5'-CGGGTTTCGTCGTACTCCTT-3'] for amplification of the 236-bp *dnaJ* gene



(Morita *et al.*, 2004). The PCR reaction parameters were as follows: one initial cycle of 94° for 5m; 40 cycles at 94° for 30s, 60° for 45s and 72° for 1m; and an additional elongation step at 72° for 5m. Positive (*M. avium*) and negative reaction control (DNA-RNA free sterile water) were utilized. Amplified DNA was visualized after electrophoresis on a 1.5% ethidium bromide-stained agarose gel. PCR products were purified using QIAquick PCR Purification Kit (Qiagen Inc., Valencia, California, USA). Sequencing reactions were performed using an ABI Prism® Big Dye Terminator v3.0 Cycle Sequencing Kit (Applied Biosystems Inc., Foster City, California, USA). Nucleotide sequences were determined with an ABI3100 automated DNA sequencer (Applied Biosystems Inc.). All sequences were aligned using Clustal X 1.81 (Thompson *et al.*, 1997) and were compared to sequences retrieved from GeneBank® ([www.ncbi.nlm.nih.gov/Genbank/index.html](http://www.ncbi.nlm.nih.gov/Genbank/index.html)).

**Determination of liver heavy metal content.** Heavy metal concentrations in liver samples for the first six white-winged ducks examined were determined by the technique described by Dehn *et al.*, (2006). Briefly, samples were chopped and homogenized. Approximately 0.1 grams of wet sample homogenate was weighed into tared, acid washed 50 ml centrifuge tubes. Three millilitres of trace-metal grade 69-71% nitric acid (Fisher Scientific Waltham, Maryland, USA) was added to each tube and the samples were allowed to stand overnight at room temperature. The next day samples were vortexed and heated in a microwave. Two ml of 30% ultrapure H<sub>2</sub>O<sub>2</sub> (JT Baker UltrexII, Phillipsburgh, New Jersey, USA) and 1 ml of 37% to 38% trace metal grade HCl (EMD

Chemicals Inc., Gibbstown, New Jersey, USA) were added and samples were again microwaved. Samples were then diluted with 18 MegOhm/cm deionized water, and analyzed with a blank, a laboratory control sample, a sample duplicate, a spiked sample, and certified reference material (Bovine Liver 1577b; National Institute of Standards and Technology, Boulder, Colorado, USA). Metal concentrations were measured using a Spectro Ciros (Spectro Analytical Instruments Inc., Marlborough, Maryland, USA) inductively coupled plasma – optical emission spectrometer and by mass spectrometry. Values are expressed as micrograms per gram of wet tissue.

## **Results**

**Macroscopic findings.** All 21 birds in the study were adults. Of the 20 birds with mycobacteriosis, 11 were females, 7 were males and the sex of two birds was not determined. One bird was severely autolyzed, complicating gross interpretation of changes. Twenty out of 21 (95.23%) ducks examined had extensive lesions consistent with mycobacteriosis (Table 5.1). All affected birds had multiple organ involvement. Avian mycobacteriosis was assumed to be the cause of death in 19 of the ducks because of the extent and severity of the lesions and the number of organs involved. One duck presented a craneocephalic trauma in absence of other lesions. Another duck had fractured neck and characteristic gross lesions of avian mycobacteriosis; both ducks were assumed to have died as a result of trauma. All but one duck had marked atrophy of the pectoral muscles and loss of body fat. The mean body weight recorded for 11 ducks

was 1315 g (SD,  $\pm$  262, range: 1,110 to 2,003 g) which was substantially below the weight range (2,150 to 3,855 g) reported previously for these ducks (Dunning, 1992).

Hepatomegaly and splenomegaly, of up two to three times the normal size, was common in these ducks. Gross lesions characteristic of mycobacteriosis in birds were found in the lung, liver, spleen, kidney and intestinal serosa of most ducks (Table 5.1). They consisted of random superficial and deep caseous, firm, irregular, grey or yellow nodules of variable size. Respiratory tract involvement was common. Multifocal coalescing granulomas were seen in the lungs of all ducks and were so extensively as to replace most of the lung in 18 ducks (Figure 5.1).

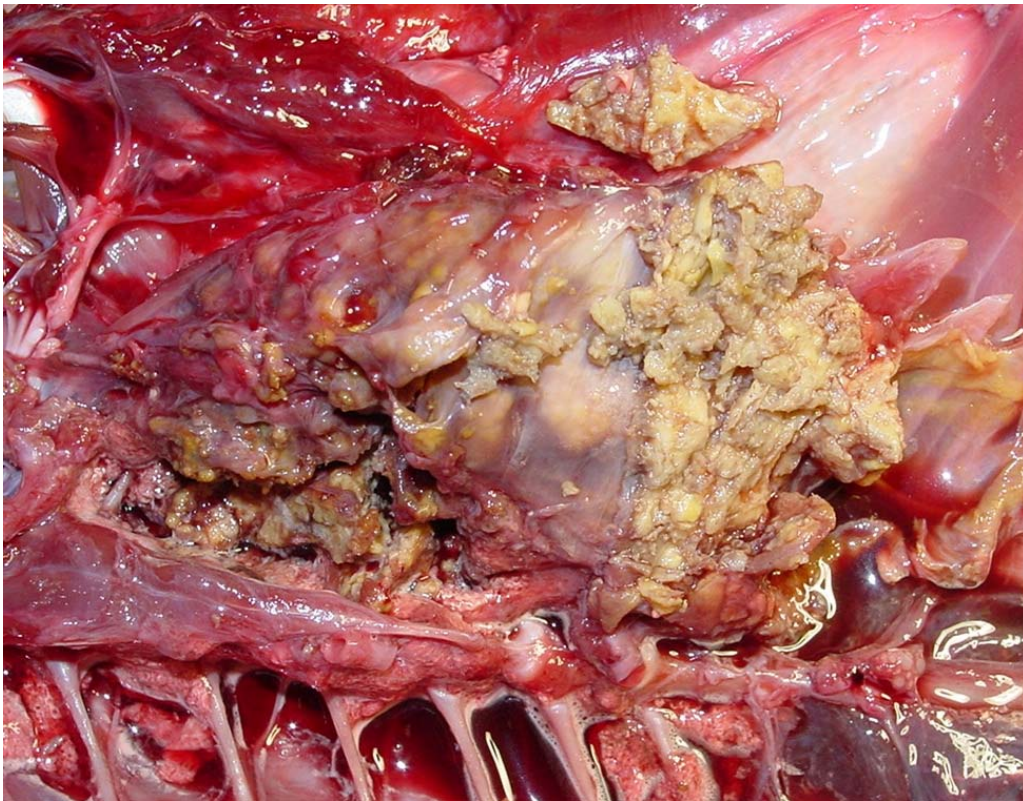


Figure 5.1. Severe diffuse fibrinous air sacculitis and several multifocal to coalescing granulomatous pneumonia.

Ten of 20 ducks had an extensive fibrinous air sacculitis of all air sacs. The lesions were so severe in five ducks that exudate filled most of the air sac. A severe diffuse fibrinous tracheitis was present in seven out of 18 birds (Figure 5.2).

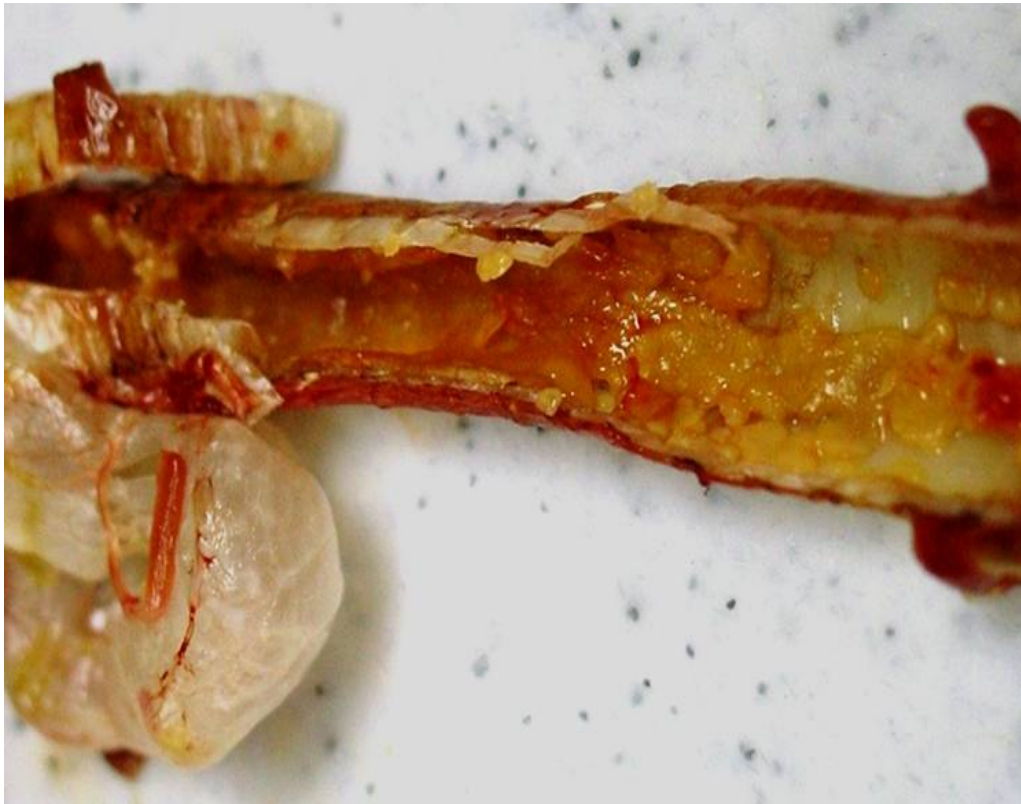

Figure 5.2. Severe diffuse fibrinous tracheitis.

Two ducks had granulomatous lesions in the subcutaneous cervical tissues. It is possible that these originated in the cervicocephalic air sacs; however, the extent of the lesion made its tissue of origin impossible to determine. Diffuse fibrinous to fibrous granulomatous inflammation of the serosa of the duodenum (five ducks), the pericardium (five ducks), and the ovary (three ducks) was also seen. Five ducks had diffusely enlarged livers without focal lesions. A yellow, caseous exudate distended the

oviduct of one bird. One duck presented with a unilateral conjunctivitis with a thick fibrinous exudate covering the palpebral conjunctiva of the upper eyelid.

**Microscopic findings.** Lesions consistent with mycobacteriosis were not observed in one of the two ducks that died from trauma. Severe post-mortem changes and freezing artefacts precluded a detailed analysis of some organs in some of the ducks. However, even in the birds with the most severe artefacts, acid-fast organisms and lesions consistent with mycobacterial infection could be found in most organs. The number and percentage of organs with microscopic lesions are presented (Table 5.1).

Table 5.1. Detail results of examination of selected organs for macroscopic and microscopic lesions of avian mycobacteriosis in white-winged ducks (*Cairina scutulata*). Data presented as macroscopic, microscopic. +: present; -: absent; n: not examined; N: total number examined; na: not applicable. a: includes pericarditis, myocarditis or both.

| Organ                    | Duck |    |    |    |    |    |     |    |    |    |     |     |     |     |     |     |     |     |    |     |     | Percentage of organs with lesions (N) |           |
|--------------------------|------|----|----|----|----|----|-----|----|----|----|-----|-----|-----|-----|-----|-----|-----|-----|----|-----|-----|---------------------------------------|-----------|
|                          |      | 01 | 02 | 03 | 04 | 05 | 06  | 07 | 08 | 09 | 010 | 011 | 012 | 013 | 014 | 015 | 016 | 017 | 18 | 019 | 020 |                                       |           |
| <i>Liver</i>             |      | -  | ++ | ++ | ++ | ++ | -n  | ++ | +n | ++ | ++  | -n  | +n  | +n  | ++  | ++  | ++  | ++  | ++ | ++  | ++  | 85 (20)                               | 93.3(15)  |
| <i>Spleen</i>            |      | ++ | n+ | -+ | ++ | ++ | -n  | ++ | +n | ++ | -+  | n+  | nn  | +n  | ++  | nn  | ++  | ++  | ++ | ++  | ++  | 81.3 (16)                             | 100 (15)  |
| <i>Lung</i>              |      | ++ | ++ | ++ | ++ | ++ | -+  | -+ | ++ | ++ | ++  | ++  | ++  | ++  | ++  | ++  | ++  | ++  | ++ | ++  | ++  | 90 (20)                               | 100 (20)  |
| <i>Trachea</i>           |      | -  | ++ | ++ | ++ | -+ | -+  | -  | -+ | -  | ++  | -   | -+  | -n  | ++  | nn  | -   | -   | ++ | ++  | nn  | 38.9 (18)                             | 64.7 (17) |
| <i>Heart<sup>a</sup></i> |      | -  | ++ | -+ | -  | -  | -   | -+ | -  | ++ | -+  | -   | -   | ++  | -   | n-  | -   | ++  | ++ | ++  | -   | 31.6 (19)                             | 45 (20)   |
| <i>Kidney</i>            |      | -  | ++ | -  | -+ | -  | -   | ++ | -  | -  | -   | -   | ++  | ++  | ++  | -   | ++  | ++  | ++ | ++  | -   | 40 (20)                               | 45 (20)   |
| <i>Esophagus</i>         |      | -  | -+ | -+ | -  | -  | -   | -  | -  | -  | -   | -   | -+  | -   | n+  | -+  | -+  | -+  | -+ | -   | -   | 0 (19)                                | 40 (20)   |
| <i>Proventriculus</i>    |      | -  | -  | -+ | -  | -n | -   | -  | -  | -  | -   | -   | -   | -   | n-  | -+  | -   | -   | -  | -   | -   | 0 (19)                                | 16.7 (18) |
| <i>Ventriculus</i>       |      | -  | -  | -  | -  | -n | -   | -  | -+ | -  | -   | -   | -   | -n  | n-  | -   | -   | -   | -  | -   | -   | 0 (19)                                | 5.6 (18)  |
| <i>Intestines</i>        |      | -  | -  | -+ | ++ | ++ | -   | ++ | ++ | ++ | -+  | ++  | -   | ++  | ++  | n+  | -   | ++  | -+ | ++  | -   | 52.6 (19)                             | 70 (20)   |
| <i>Ovary</i>             |      | na | na | -+ | na | nn | -   | -  | -  | na | ++  | Na  | na  | -   | ++  | n+  | Na  | -   | -  | ++  | nn  | 30 (10)                               | 45.5 (11) |
| <i>Testes</i>            |      | -  | -  | na | -  | na | na- | na | na | -  | Na  | -   | -   | na  | na  | na  | -   | na  | Na | na  | nn  | 0 (7)                                 | 0 (7)     |
| <i>Thyroid</i>           |      | -  | -  | -  | -  | nn | -n  | -  | -  | -n | -   | -   | -n  | -n  | -   | nn  | nn  | -   | nn | nn  | -   | 0 (15)                                | 0 (11)    |
| <i>Adrenal</i>           |      | nn | nn | nn | nn | nn | -n  | n- | nn | -n | -   | -   | -n  | nn  | nn  | nn  | nn  | -   | -  | nn  | nn  | 0 (7)                                 | 0 (5)     |
| <i>Bone Marrow</i>       |      | -n | -n | -n | -n | -n | -n  | -n | -n | -n | -n  | -n  | -n  | n+  | n-  | n+  | nn  | n-  | n- | ++  | nn  | 7.7 (13)                              | 50 (6)    |
| <i>Pancreas</i>          |      | -  | -  | -  | -  | -n | -n  | -  | -  | -  | -   | -   | -   | -   | -   | -   | -   | -   | -  | -   | -   | 0 (20)                                | 0 (18)    |
| <i>Muscle</i>            |      | -  | -  | -  | -  | -n | -   | -  | -  | ++ | -   | -n  | -   | -   | -   | -   | -   | ++  | -  | -   | -   | 10 (20)                               | 11.1 (18) |

Microscopic lesions could be divided into two basic types, sometimes overlapping. The first type was discrete granulomas of variable size, with different degrees of central caseation necrosis and with a layer of surrounding histiocytes and lymphocytes and a fibrous capsule of varying thickness. These lesions were observed in the liver, spleen, kidney, lung, heart and on the intestinal serosa (Table 5.2).

Table 5.2. Microscopic findings in organs of white-winged ducks (*Cairina scutulata*) with multi-focal granulomatous inflammation.

| Organ             | Degree of inflammation |          |        | Number of acid-fast organisms |     |          |      |         |
|-------------------|------------------------|----------|--------|-------------------------------|-----|----------|------|---------|
|                   | Mild                   | Moderate | Severe | None                          | Few | Moderate | Many | Massive |
| Liver             | 2                      | 2        | 7      |                               | 1   | 6        |      | 4       |
| Spleen            |                        | 1        | 14     |                               | 2   | 2        | 4    | 7       |
| Lung              | 2                      |          | 18     | 1                             |     |          |      | 19      |
| Kidney            |                        |          | 9      |                               |     |          |      | 9       |
| Heart             |                        |          | 1      |                               |     |          |      | 1       |
| Intestinal serosa | 3                      |          | 11     |                               |     |          |      | 12      |
| Skeletal muscle   |                        |          | 2      |                               | 1   |          |      | 1       |
|                   |                        |          |        |                               |     |          |      |         |

Spleens contained less defined granulomas compared with the other organs and had a diffuse histiocytic splenitis in the regions between the granulomas. Variable amounts of amyloid were observed around central veins and vessels and in the space of Disse in the liver as well in the spleen of nine ducks.

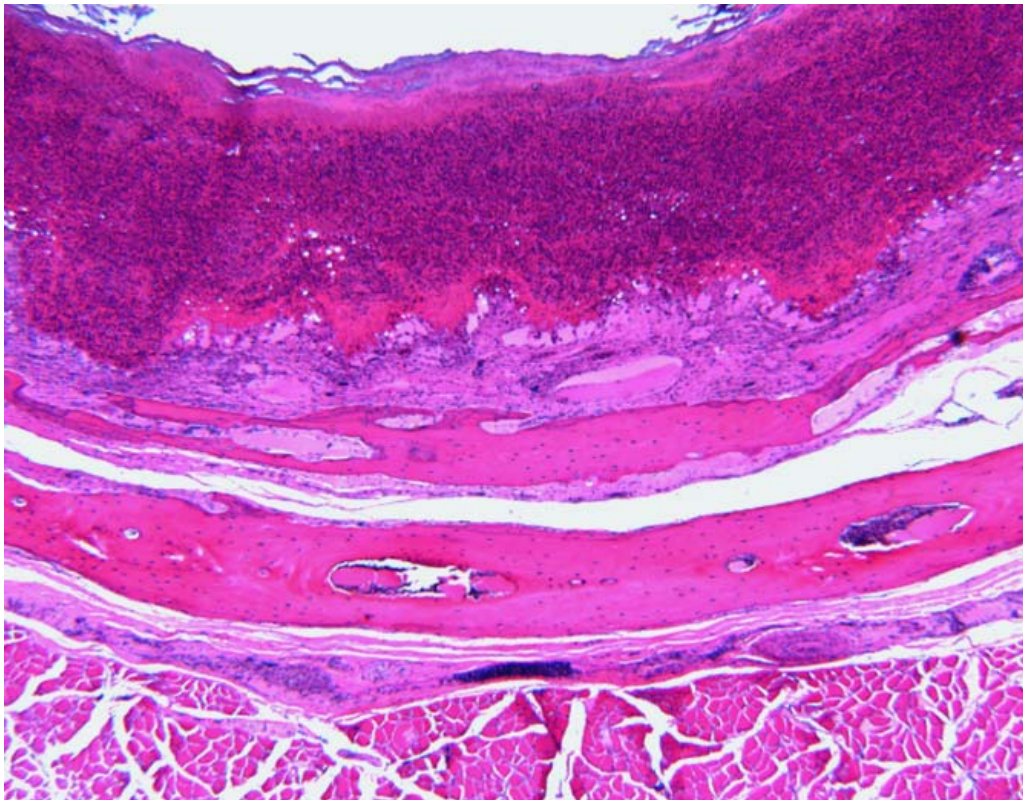
The second type of lesion was characterized by a more diffuse granulomatous inflammation, without the formation of discrete granulomas. The predominant cell types in these lesions were histiocytes and to a lesser degree lymphocytes and plasmacytes. These lesions were observed predominately in the trachea (Figure 5.3), oesophagus, proventriculus, bone marrow, air sacs, ovary, oviduct and on serosal surfaces (Table 5.3). Intestinal mucosal lesions were rare.



Table 5.3. Microscopic findings in organs of white-winged ducks (*Cairina scutulata*) with diffuse granulomatous inflammation.

| Organ             | Degree of inflammation |          |        | Number of acid fast organisms |     |          |      |         |
|-------------------|------------------------|----------|--------|-------------------------------|-----|----------|------|---------|
|                   | Mild                   | Moderate | Severe | None                          | Few | Moderate | Many | Massive |
| Liver             |                        |          | 3      |                               | 1   |          | 1    | 1       |
| Trachea           |                        |          | 11     |                               | 4   | 3        |      | 4       |
| Pericardium       | 5                      | 1        | 2      | 1                             |     | 2        | 5    |         |
| Heart             | 1                      |          |        |                               |     |          | 1    |         |
| Esophagus         | 1                      | 5        | 2      |                               |     | 4        | 4    |         |
| Proventriculus    |                        | 3        |        | 1                             |     | 2        |      |         |
| Intestinal mucosa | 1                      |          | 1      |                               | 2   |          |      |         |
| Bone marrow       |                        | 3        |        |                               |     | 3        |      |         |
| Air sacs          |                        |          | 10     |                               |     |          |      | 10      |
| Ovary (stroma)    | 2                      | 3        |        |                               |     | 5        |      |         |

Figure 5.3. Severe diffuse fibrinous tracheitis with complete effacement of the mucosal epithelium.





Multinucleated giant cells were absent from the lesions of all but one duck where they were present in granulomas of the liver, spleen, kidney and lung. In a second duck, some cells appeared agglomerated but without a clear syncytial pattern.

**Results of culture and PCR.** All cultures from the liver and/or the lung yielded mycobacteria after 3 to 4 weeks of incubation. An amplicon of expected molecular mass was amplified by PCR from the liver or the lung from 19 birds histologically confirmed to have mycobacteriosis. The remaining bird with mycobacteriosis was not tested by PCR. The sequences of the amplified *dnaJ* gene for 6 isolates were identical and had 100% identity with the sequevar of *Mycobacterium a. avium* that contains serotypes 2, 3, 4 and 9 (Morita *et al.*, 2004).

**Liver heavy metal concentrations.** Liver concentrations of silver, aluminum, antimony, arsenic, boron, beryllium, lithium, nickel, lead, mercury, selenium, thorium, uranium, and vanadium were below detectable concentrations by either mass spectrometry or optical emission spectrometer (data not shown). Liver concentrations of barium, cadmium, cobalt, chromium, molybdenum, strontium and thallium were below detection limits for optical emission spectrometer but detectable with mass spectrometer. However, all concentrations were very low, being just equal or less than three times the detection limit concentration (data not shown). One of the ducks had a barium liver concentration of 0.215 µg/g, almost four times the detection limit concentration (0.0542 µg/g). Another duck had a cadmium concentration of 0.131 µg/g, six times the minimal

detectable concentrations (0.0216 µg/g), and a thallium concentration of 0.035 µg/g, 3.24 times the minimum detectable concentration (0.0108 µg/g).

## **Discussion**

This report describes an investigation of the aetiopathogenesis of avian mycobacteriosis in white-winged ducks that died during a 21-month period from 2004 to 2006 at the Sylvan Heights Waterfowl Center in the USA. Mycobacteriosis was found in 20 of 21 ducks examined and was the confirmed cause of death of 19 of 21 ducks. The incidence of this disease in this population (95.23%) was higher than but similar in scale to the incidence reported in England (Cromie *et al.*, 1991, 1992), indicating that mycobacteriosis is a significant impediment facing *ex situ* efforts to save this species.

*Mycobacterium a. avium* serotype 1 was the only mycobacteria isolated from white-winged ducks kept at the Wildfowl and Wetlands Trust, Slimbridge, England. These findings led investigators to suggest that *M. a. avium* serotype 1 may be particularly pathogenic to white-winged ducks. Serotyping of *M. a. avium* isolates is no longer routinely done and has been largely replaced by genotyping of the isolates. Genotypes can be used to predict serotype in some, but not all, circumstances (Morita *et al.*, 2004). The *M. a. avium* isolates from the white-winged ducks in this study were not serotype 1. Instead, comparative sequence analysis demonstrated that all the isolates were of a genotype that contained the serotypes 2, 3, 4 and 9. Thus, white-winged ducks are susceptible to infection with at least two genetic variants of *M. a. avium*. The high

percentage of both captive populations of ducks dying of mycobacteriosis, caused by two different genetic strains of *M. a. avium*, suggests that both organisms are particularly virulent for them. Nevertheless, susceptibility of both populations to different organisms may also point to a host factor predisposing to this increased susceptibility. High levels of contamination of the captive populations environment by mycobacteria was also considered. However, this possibility is not supported by the fact that different species of ducks at the Slimbridge collection in the United Kingdom also had different incidences of infection for avian mycobacteriosis (Cromie et al., 1991). Mycobacteriosis accounts for one-third of adult deaths in all the species of ducks (33%) in that facility, while in white-winged ducks, during a 16-year period, it averaged 84%. A much lower rate of mortality also occurs in other species of ducks in the Sylvan Heights collection (G. Riggs, unpublished data). A higher mortality in other species of ducks should be expected if environmental contamination is really the major cause of avian mycobacteriosis in these birds.

It has been suggested that the high incidence of mycobacteriosis in captive white-winged ducks could be explained by evolutionary and genetic characteristics of this species (Hillgarth & Kear, 1981, Cromie *et al.*, 1991). In the wild, these ducks spend a considerable amount of time perching in trees, with little natural exposure to soil mycobacteria. As a result, they may show reduced natural immunity to these organisms (Hillgarth & Kear, 1981, Cromie *et al.*, 1991). In captive birds, as result of pinioning and lack of perching a higher exposure to soil or water mycobacteria may occur (Hillgarth &

Kear, 1981, Cromie *et al.*, 1991). However, there are few reports of mycobacteriosis in Muscovy's ducks (Sabočanec *et al.*, 2006), with similar habits and closely related to the white-winged duck (*Cairininae* tribe), despite its extensive use in agriculture and its common presence at zoos and waterfowl collections.

The current genetic diversity of captive white-winged ducks has been estimated as less than 63.5% (Riggs, 2005) and could be a more probable explanation for the susceptibility of captive white-winged ducks to mycobacteriosis. Increased susceptibility to infectious diseases caused by decreased genetic diversity has been recognized previously in wild animals (O'Brien *et al.*, 1996; Keller & Waller, 2002; Acevedo-Whitehouse *et al.*, 2003). Low heterozygosity at the level of the major histocompatibility complex has been recently demonstrated as a factor leading to higher susceptibility to diseases in wild mammals (Acevedo-Whitehouse *et al.*, 2003) and wild birds (Miller & Lambert, 2004; Bonneaud *et al.*, 2006).

The absence of multinucleated giant cells from the lesions of all but one white-winged duck in our series may provide a clue to the high susceptibility of the population in the United States. Multinucleated giant cells have been reported in other ducks with mycobacteriosis (Mallick *et al.*, 1970; Thoen & Himes, 1976; Roffe, 1989). The granulomatous lesions seen in the white-winged ducks resemble the hyporeactive and poorly developed granulomas seen in humans with human immunodeficiency virus/acquired immune deficiency syndrome and tuberculosis (Smith *et al.*, 2000). These

poorly developed granulomas do not have multinucleated giant cells, have abundant acid-fast organisms and present areas of necrosis surrounded by histiocytes. In many cases they do not completely encircle the granuloma (Smith *et al.*, 2000). In humans, the ability to form multinucleated giant cells is considered one indicator of an effective immune response to tuberculosis (Byrd, 1998, Smith *et al.*, 2000). Multinucleated giant cells may limit the growth as well as the cell to cell spread of *Mycobacterium tuberculosis* (Byrd, 1998; North and Young, 2004; Dannenberg, 2006). The similarities to our findings in white-winged ducks are striking and suggest that a similar defect in the immune system may occur in these ducks.

Little is known about the mechanism of multinucleated giant cell formation in mammals or birds (Anderson, 2000; Smith *et al.*, 2000, Okamoto *et al.*, 2003). However, in humans, cytokines such as interleukin-3 and interferon gamma secreted by CD4 Th1 lymphocytes (Okamoto *et al.*, 2003) are needed for cell fusion and to confine mycobacteria within these cells (Kunkel *et al.*, 1998; Okamoto *et al.*, 2003). Additionally, in humans, depletion of CD4 T cells results in reactivation of latent *M. tuberculosis* infections, impaired granuloma formation and macrophage activation and a diminished CD8 cytotoxic T-cell response (Smith *et al.*, 2000). The abundance of organisms and the absence of multinucleated giant cells in the lesions of these ducks may suggest a defect in the duck's ability to kill intracellular mycobacteria. It is possible that a defect in cell fusion and multinucleated giant cell formation may explain why white-winged ducks are so susceptible to mycobacterial infections. Nevertheless,

immunology of mycobacterial infections is a little studied phenomenon in birds (Cromie *et al.*, 2000; Tell *et al.*, 2001), compared to humans, cattle and other animal models (Chacon *et al.*, 2004; North and Young 2004; Dannenberg 2006; Flynn 2006), and we are far from having a complete understanding of the immune response to this infection in most species of birds. The recent discovery of markers that can be used to identify CD4 and CD8 cells in mallard ducks (Kothlow *et al.*, 2005) may help studies on immunity in other species of ducks.

Amyloidosis is a pathological condition characterized by the deposition of insoluble fibrillar proteins in various tissues and organs of the body following prolonged inflammation or infection (Cotran *et al.*, 1999). Amyloid deposits have been reported previously in birds with chronic inflammatory diseases such as mycobacteriosis and aspergillosis. This lesion is particularly common in waterfowl (Montali *et al.*, 1976; Schmidt *et al.*, 2003; Meyerholz *et al.*, 2005). Several forms of amyloid have been described in mammals, but only amyloid AA has been found in birds (Landman *et al.*, 1998; Cotran *et al.*, 1999; Schmidt *et al.*, 2003). Amyloid AA is a product of the proteolytic cleavage of serum amyloid A, an acute phase-protein produced by hepatocytes (Landman *et al.*, 1998). The concentration of serum amyloid A in the blood increases within a several hours of the onset of injury, infection, or inflammation. Production of serum amyloid A is directly stimulated by the cytokines interleukin-1, interleukin-6 and tumor necrosis factor alpha produced in response to tissue injury and

inflammation (Petersen *et al.*, 2004). The persistent inflammation caused by chronic mycobacteriosis is a likely cause of the deposition of amyloid in these ducks.

It is generally assumed that most *M. a. avium* infections in birds result from entry of the organisms into the body through the digestive tract (Montali *et al.*, 1976; Cromie *et al.*, 1991, 1992, Tell *et al.*, 2001; Schmidt *et al.*, 2003). Microbial shedding is also thought to occur through the faeces as many birds with mycobacteriosis have severe diffuse granulomatous enteritis. The lesion distribution in the white-winged ducks in this study, however, was somewhat unusual. In addition to the expected involvement of the liver and spleen, there was often massive involvement of the air sacs, other mesothelial surfaces, the lung and the upper digestive tract. Lesions in the intestinal mucosa were uncommon, an important difference from other reports of mycobacteriosis in birds (Montali *et al.*, 1976; Tell *et al.*, 2001; Schmidt *et al.*, 2003). An aerogenic route of mycobacterial entry has been previously reported for dabbling ducks and other species (Cromie *et al.*, 1991; Gerlach, 1997). Unfortunately, there are not previously reported descriptions of the pathology of mycobacteriosis in white-winged ducks affected by mycobacteriosis. This precludes comparison between these birds and our series. There are also very limited data available on the gross and microscopic pathology in other species of ducks with mycobacteriosis. The liver, spleen and kidneys were usually the only affected organs (Mallick *et al.*, 1970; Thoen *et al.*, 1976; Roffe, 1989; Cromie *et al.*, 1991). Whether the high prevalence of respiratory lesions seen in our series is the

result of inhalation or the result of preferred colonization of the respiratory tract by mycobacteria that enter through a different route is not known.

Heavy metal concentrations in liver were determined because metals have the ability to cause immune suppression, and ducks, because of their feeding behaviours and aquatic habits, are likely to accumulate environmental toxins, especially metals (Di Giulio & Scanlon, 1984; Mateo & Guitart, 2003; Fairbrother *et al.*, 2004). The absent or low concentrations of heavy metals in these ducks ruled out this possible explanation for their susceptibility to infection with mycobacteria. Slight elevations in liver barium concentrations in one duck and slight elevations in both cadmium and thallium in another were not considered significant since these concentrations were lower than those found in other species of ducks in previous reports (Cohen *et al.*, 2000; Braune & Malone, 2006; Mochizuki *et al.*, 2005).

In conclusion, this study demonstrated that disease caused by *M. a. avium* was the major cause of mortality in this population of white-winged ducks kept at Sylvan Heights Waterfowl Center. In conjunction with reports from the United Kingdom, it can be concluded that mycobacterial infections are the most significant factor limiting the *ex situ* recovery of this species. The reason for this high susceptibility to mycobacteriosis is unknown, but a defect in their ability to kill intracellular mycobacteria may be one possible explanation. The low heterozygosity of these ducks leading to immunodeficiency is possible (Cromie *et al.*, 2000, Riggs, 2005), as occurs in other species of animals with



low genetic diversity (Acevedo-Whitehouse *et al.*, 2003; Bonneaud *et al.*, 2006). If this supposition is correct, additional efforts to maintain this species with the currently available genetic stock may prove very difficult. *M. a. avium* is ubiquitous in the environment. Exposure to even low levels of the organism may ultimately result in infection and disease in the white-winged duck no matter what management efforts are undertaken. A more fruitful strategy to save this species may be to establish a new and genetically diverse captive breeding population of these ducks from the remaining wild population, together with a scientifically managed breeding program assuring the maintenance of genetic diversity.

## REFERENCES

Acevedo-Whitehouse, K., Gulland, F., Greig, D. & Amos, W. (2003). Disease susceptibility in California sea lions. *Nature*, 422 (6), 35.

Acevedo-Whitehouse, K., Vicente, J., Gortazar, C., Höfle, U., Fernández-de-Mera, I.G. & Amos, W. (2005). Genetic resistance to bovine tuberculosis in the Iberian wild boar. *Molecular Ecology* 14, 3209-3217.

Anderson, J.M. (2000). Multinucleated giant cells. *Current Opinion in Hematology*, 7, 40-47.

Aranaz, A., Liébana, E., Mateos, A. & Domínguez, L. (1997). Laboratory diagnosis of avian mycobacteria. *Seminars in Avian & Exotic Pet Medicine*, 6, 9-17.

Bacon, L.D., Hunt, H.D. & Cheng, H.H. (2000). A review of the development of chicken lines to resolve genes determining resistance to diseases. *Poultry Science*, 79, 1082-1093.

Baghdadi, J.E., Orlova, M., Alter, A., Ranque, B., Chentoufi, M., Lazrak, F., Archane, M.I., Casanova, J.L., Benslimane, A., Schurr, E. & Abel, L. (2006). An autosomal

dominant major gene confers predisposition to pulmonary tuberculosis in adults. *Journal of Experimental Medicine*, 203, 1679-1684.

Barthel, R., Piedrahita, J.A., McMurray, D.N., Payeur, J., Baca, D., Suarez-Guemes, F., Perumalla, V.S., Ficht, T.A., Templeton, J.W. & Adams, L.G. (2000). Pathologic findings and association of *Mycobacterium bovis* infection with the bovine NRAMP1 gene in cattle from herds with naturally occurring tuberculosis. *American Journal of Veterinary Research*, 61, 1140-1144.

Bartos, M., Hlozek, P., Svastova, P., Dvorska, L., Bull, T., Matlova, L., Parmova, I., Kuhn, I., Stubbs, J., Moravkova, M., Kintr, J., Beran, V., Melicharek, I., Ocepek, M. & Pavlik I. (2006). Identification of members of *Mycobacterium avium* species by Accu-Probes, serotyping, and single IS900, IS901, IS1245 and IS901-flanking region PCR with internal standards. *Journal of Microbiological Methods*, 64, 3333-3334.

Bellamy, R.J. & Hill, A.V. (1998). Genetic susceptibility to mycobacteria and other infectious pathogens in humans. *Current Opinions in Immunology*, 10, 483-487.

Bellamy, R., Beyers, N., McAdam, K.P., Ruwende, C., Gie, R., Samaai, P., Bester, D., Meyer, M., Corrah, T., Collin, M., Camidge, D.R., Wilkinson, D., Hoal-Van Helden, E., Whittle, H.C., Amos, W., Van Helden, P. & Hill, A.V. (2000). Genetic susceptibility to

tuberculosis in Africans: a genome-wide scan. *Proceedings National Academy of Sciences, USA*, 97, 8005-8009.

Bellamy, R. (2005). Genetic susceptibility to tuberculosis. *Clinics in Chest Medicine*, 26, 233-246.

Bertelsen, M.F., Grøndahl, C. & Giese, S.B. (2006). Disseminated *Mycobacterium celatum* infection in a white-tailed trogon (*Trogon viridis*). *Avian Pathology*, 35, 316-319.

Bieth, F., Boschioli, M.L., Thorel, M.F., Guilloteau, L.A. (2005). Zoonotic aspects of *Mycobacterium bovis* and *Mycobacterium avium-intracellulare* complex (MAC). *Veterinary Research*, 36, 411-436.

BirdLife International. (2001). *Threatened Birds of Asia: The BirdLife International Red Data Book*. (pp.403-440). Cambridge: BirdLife International.

BirdLife International. (2006). *Cairina scutulata*. In *IUCN 2006 Red List of Threatened Species*. Available online at: [www.iucnredlist.org](http://www.iucnredlist.org). (19 July 2006).

Bonneaud, C., Peres-Tris, J., Federici, P., Chastel, O., & Sorci, G. (2006). Major histocompatibility alleles associated with local resistance to malaria in a passerine. *Evolution*, *60*, 383-389.

Bougiouklis, P., Brellou, G., Fragkiadaki, E., Iordanidis, P., Vlemmas, I. & Georgopoulou, I. (2005). Outbreak of avian mycobacteriosis in a flock of two-year-old domestic pigeons (*Columba livia f. domestica*). *Avian Diseases* *49*, 442-445.

Braune, B.M., & Malone, B.J. (2006). Mercury and selenium in livers of waterfowl harvested in northern Canada. *Archives of Environmental Contaminant Toxicology*, *50*, 284-289.

Bumstead, J.M., Bumstead, N., Rothwell, L. & Tomley, F.M. (1995). Comparison of immune responses in inbred lines of chickens to *Eimeria maxima* and *Eimeria tenella*. *Parasitology*, *111* ( Pt 2), 143-151.

Bush, M., Montali, R.J., Smith E.E. & Himes, E.M. (1978). Clinical experience with tuberculosis in exotic birds. In R.J. Montali (Ed) *Mycobacterial Infections of Zoo Animals*. (pp. 199-204). Washington DC: Smithsonian Institution.

Byrd, T.F. (1998). Multinucleated giant cell formation induced by IFN- $\gamma$ /IL-3 is associated with restriction of virulent *Mycobacterium tuberculosis* cell to cell invasion in human monocytes monolayers. *Cellular Immunology*, 188, 89-96.

Campbell, T. & Ellis, C. (2007). *Avian and Exotic Animal Hematology and Cytology*. Ames, IA: Blackwell Publishing.

Carpenter, J.W. (2005). *Exotic Animal Formulary*. St. Louis: Elsevier Saunders.

Casanova, J.L. & Abel, L (2002). Genetic dissection of immunity to mycobacteria: the human model. *Annual Review of Immunology*, 20, 581-620.

Cervino, A.C., Lakiss, S., Sow, O., Bellamy, R., Beyers, N., Hoal van Helden, E., van Helden, P., McAdam, K.P. & Hill, A.V. (2002). Fine mapping of a putative tuberculosis-susceptibility locus on chromosome 15q11-13 in African families. *Human Molecular Genetics*, 11, 1599-1603.

Chacon, O., Bermudez L.E, & Barletta, R.G. (2004). Johne's disease, inflammatory bowel disease, and *Mycobacterium paratuberculosis*. *Annual Review in Microbiology*, 58, 329-363.

Clark, S.L., Collins, M.T., Price, J.I., (1995). New methods for diagnosis of *Mycobacterium avium* infection in birds. In *Proceedings American Association of Zoo Veterinarians, Wildlife Disease Association, American Association of Wildlife Veterinarians Joint Conference*, (pp.151-154). East Lansing, MI

Cohen, J.B., Barclay, J.S., Major, A.R., & Fisher, J.P. (2000). Wintering Greater Scaup as biomonitors of metal contamination in federal wildlife refuges in the Long Island region. *Archives of Environmental and Contamination Toxicology*, 38, 83-92.

Cole S.T., Eisenach, K.D., McMurray, D.N., Jacobs, W.R.Jr. (2004). *Tuberculosis and the Tubercle Bacillus*. Washington: ASM Press.

Connor, D.H., Chandler, F.W., Schwartz, D.A., Manz, H.J. & Lack, E. (1997). *Pathology of Infectious Diseases*. New York: McGraw-Hill.

Converse, K.A. (2007). Avian tuberculosis. In N.J. Thomas, D.B. Hunter & C.T. Atkinson (Eds.), *Infectious Diseases of Wild Birds*. (pp. 289-302). Ames, IA: Blackwell Publishing.

Cotran, R.S., Kumar, V., & Collins, T. (1999). *Robbins Pathologic Basis of Diseases*. (pp.251-259). Philadelphia, PA: WB Saunders Co.

Cotter, P.F., Taylor, R.L. & Abplanalp, H. (1992). Differential resistance to *Staphylococcus aureus* challenge in major histocompatibility (B) complex congenic lines. *Poultry Sciences*, 71, 1873-1878.

Cray, C., Crim, A. & Clubb, S. (2001). Serological and molecular diagnosis of mycobacteriosis. In *Proceedings of the 22<sup>nd</sup> Association of Avian Veterinarians Conference* (pp. 83-85), Orlando, FL, USA.

Cray, C. (2004). Diagnostic use of protein electrophoresis in birds. In J. Bonagura (Ed). *Kirk's Current Veterinary Therapy XIII* (pp. 1107-1109). Philadelphia, PA: WB Saunders Co.

Cray, C., Rodriguez, M. & Zaias, J. (2007). Protein electrophoresis of psittacine plasma. *Veterinary Clinics Pathology*, 36, 64-72.

Cromie, R.L., Brown, M.J., Price, D.J. & Stanford, J.L. (1991). Susceptibility of captive wildfowl to avian tuberculosis: the importance of genetic and environmental factors. *Tubercle*, 72, 105-109.

Cromie, R.L., Brown, M.J. & Stanford, J.L. (1992). The epidemiology of avian tuberculosis in white-winged wood duck *Cairina scutulata* at The Wildfowl and Wetland Trust, Slimbridge Centre (1976-1991). *Wildfowl*, 43, 211-214.



Cromie, R.L., Brown, M.J., Forbes, N.A., Morgan, J. & Stanford, J.L. (1993). A comparison and evaluation of techniques for diagnosis of avian tuberculosis in wildfowl. *Avian Pathology*, 22, 617-630.

Cromie, R.L., Ash, N.J., Brown, M.J. & Stanford, J.L. (2000). Avian immune response to *Mycobacterium avium*: the wildfowl example. *Developmental and Comparative Immunology*, 24, 169-185.

Dannenberg, A.M. (2006) *Pathogenesis of Human Tuberculosis. Insights From the Rabbit Model*. Washington, DC: ASM Press.

Dehn, L.A., Follman, E.H., Rosa, C., Duffy, L.K., Thomas, D.L., Bratton, G.R., Taylor, R.J. & O'Hara, T.M. (2006). Stable isotope and trace elements status of subsistence-hunted bowhead and beluga whales in Alaska and gray whales in Chukotka. *Marine Pollution Bulletin*, 52, 302-319.

Del Hoyo, J., Sargatal, J. & Cabot, J. (Eds). (1992). *Handbook of the Birds of the World: Ostriches to Ducks*, Barcelona, Spain: Lynx Editions.

Di Giulio, R.T. & Scanlon, P.F. (1984). Heavy metals in tissues of waterfowl from the Chesapeake Bay, USA. *Environmental Pollution*, 35, 29-48.

Di Pietrantonio, T. & Schurr, E. (2005). Mouse models for the genetic study of tuberculosis susceptibility. *Briefings in Functional Genomics and Proteomics*, 4, 277-292.

Dorman, S.E., Hatem, C.L., Tyagi, S., Aird, K., Lopez-Molina, J., Pitt, M.L., Zook, B.C., Dannenberg, A.M., Bishai, W.R. & Manabe, Y.C. (2004). Susceptibility to tuberculosis: clues from studies with inbred and outbred New Zealand White rabbits. *Infection and Immunity*, 72, 1700-1705.

Dorrestein, G.M. (1996). Infections caused by bacteria. In Altman, R.B., Clubb, S.L., Dorrestein, G.M. & Quesenberry, K. *Avian Medicine and Surgery*. New York: WB Saunders Co.

Dunning, J.B. (1992). *CRC Handbook of Avian Body Masses*. (pp. 21). Boca Raton, FL: CRC Press.

Dvorska, L., Matlova, L., Ayele, W.Y., Fischer, O.A., Amemori, T., Weston, R.T., Alvarez, J., Beran, V., Moravkova, M. & Pavlik I. (2007). Avian tuberculosis in naturally infected captive water birds of the Ardeidae and Threskiornithidae families studied by serotyping, IS901 RFLP typing, and virulence for poultry. *Veterinary Microbiology*, 119, 366-374.

Evans, T.D., Robichaud, W.G. & Tizard, R.J. (1997). The White-winged Duck *Cairina scutulata* in Laos. *Wildfowl*, 44, 81–96.

Fairbrother, A., Smits, J. & Grasman, K. (2004). Avian immunotoxicology. *Journal of Toxicology and Environmental Health B Critical Review*, 7, 105-137.

Falkinham, J.O. (2004). Environmental sources of *Mycobacterium avium* linked to routes of exposure. In Pedley, S., Bartram, J., Rees, G., Dufour, A. & Cotruvo, J. (Eds.), *Pathogenic Mycobacteria in water: A guide to public health consequences, monitoring and management* (pp. 27-33). London, UK: IWA Publishing.

Feldman, W.H. (1938). *Avian Tuberculosis Infections*. Baltimore, MD: Williams and Wilkins.

Flynn, J.L. (2006). Lessons from experimental *Mycobacterium tuberculosis* infections. *Microbes Infections*, 8, 1179-1188.

Fontenot, D.K., Terrell, S.P. Malakooti, K. & Medina, S. (2006). Health assessment of the Guam Rail (*Gallirallus owstoni*) population in the Guam Rail recovery program. *Journal of Avian Medicine and Surgery*, 20, 225–233.

Forbes, N.A., Cromie, R.L., Brown, M.J., Montali, R.J, Bush, M. & Standford, J.L. (1993). Serodiagnosis of mycobacteriosis in waterfowl. In *Proceedings of the 14th Association of Avian Veterinarians Conference* (pp. 182). Pittsburgh, PA, USA.

Francis, J. (1958). *Tuberculosis in Animals and Man: A Study on Comparative Pathology*. London, UK: Cassell Press.

Friend, M. (2001). Avian tuberculosis. In M. Friend & J.C. Franson (Eds.). *Field Manual of Wildlife Diseases* (pp. 93–98). Madison, WI: U.S. Geological Survey, Biological Resources Division, National Wildlife Health Center.

Fudge, A. (2000). *Laboratory Medicine: Avian and Exotics Pets*. New York: WB Saunders Co.

Fulton, R.M. & Thoen, C.O. (2003). Tuberculosis. In *Diseases of Poultry*. (pp. 836-844). Ames, IA: Iowa State Press.

Gerlach, H. (1997). Bacteria. In B.W. Ritchie, G.J. Harrison & L.R. Harrison (Eds). *Avian Medicine: Principles and Application*. (pp. 520-536). Lake Worth, FL: Wingers Publishing.

Griffith, D.E. (2007). Therapy of non-tuberculous mycobacterial disease. *Current Opinions in Infectious Diseases*, 20, 198-203.

Gross, W.B., Falkinham, J.D. & Payeur, J.B. (1989). Effect of environmental-genetic interactions on *Mycobacterium avium* challenge infection. *Avian Diseases*, 33, 411-415.

Hejlíček, K. & Treml, F. (1993). Epizootiology and pathogenesis of avian mycobacteriosis in doves (*Streptopelia sp.*) *Veterinary Medicine (Praha)* 38, 319-328.

Hejlíček, K. & Treml, F. (1995). Comparison of the pathogenesis and epizootologic importance of avian mycobacteriosis in various types of domestic and free-living syntropic birds. *Veterinary Medicine (Praha)* 40, 187-194.

Hellmer, P. (2006). Advances in diagnosing imaging. In Harrison, G.J. & Lightfoot, T.L. (Eds.). *Clinical Avian Medicine* (pp. 681-688). Tampa, FL: Spix Publishing.

Hershfield, E. (1999). Tuberculosis: Treatment. *Canadian Medical Association Journal* 161: 405-411.

Hill, A.V.S. (2006). Aspect of genetic susceptibility to human infectious diseases. *Annual Reviews in Genetics*, 40, 469-486.

Hillgarth, N. & Kear, J. (1981). Diseases of perching ducks in captivity. *Wildfowl*, 32, 156-162.

Hoop, R.K., Bottger, E.C. & Pfyffer, G.E. (1996). Etiological agents of mycobacteriosis in pet birds between 1986 and 1995. *Journal of Clinical Microbiology*, 34, 991-992.

Hu, J., Bumstead, N., Barrow, P., Sebastiani, G., Olien, L., Morgan, K. & Malo, D. (1997). Resistance to salmonellosis in the chicken is linked to NRAMP1 and TNC. *Genome Research*, 7, 693-704.

Johansen, T.B., Olsen, I., Jensen, M.R., Dahle, U.R., Holstad, G., Djonne, B. (2007). New probes used for IS1245 and IS1311 restriction fragment length polymorphism of *Mycobacterium avium* subsp. *avium* and *Mycobacterium avium* subsp. *hominissuis* isolates of human and animal origin in Norway. *BMC Microbiology*, 5, 7-14.

Jubb, K.V.F., Kennedy, P.C. & Palmer, N. (1993). *Pathology of Domestic Animals*, Volume 1 (4th Edition). New York, NY: WB Saunders.

Kalisinska, E., Salicki, W., Myslek, P., Kavetska, K.M. & Jackowski, A. (2004). Using the Mallard to biomonitor heavy metal contamination of wetlands in north-western Poland. *Science Total Environment*, 320, 145-161.

Katoch, V.M. (2004). Infections due to non-tuberculous mycobacteria (NTM). *Indian Journal of Medical Research*, 120, 290-304.

Keller, F., & Waller, D.M. (2002). Inbreeding effects in wild populations. *Trends in Ecology and Evolution*, 17, 230-241.

Kothlow, S., Mannes, N.K., Schaerer, B., Rebeski, D.E., Kaspers, B. & Schultz, U. (2005). Characterization of duck leucocytes by monoclonal antibodies. *Developments in Comparative Immunology*, 29, 733-748.

Kunkel, S., Lucaks, N., Strieter, R. & Chensue, S. (1998). Animal models of granulomatous inflammation. *Seminars in Respiratory Infections*, 13, 221-228.

Landman, W.J.M., Gruys, E. & Gielkens, A.L.J. (1998). Avian amyloidosis. *Avian Pathology*, 27, 437-449.

Lennox, A.M. (2002). Successful treatment of mycobacterial infection in three psittacine birds. In *Proceedings of the 23<sup>rd</sup> Association of Avian Veterinarians Conference*, (pp. 111-114), Reno, NV, USA.

Lim, T.K. (2000). Human genetic susceptibility to tuberculosis. *Annals Academy of Medicine of Singapore*, 29, 298-304.

Mahon, C.R., Manuselis, G. & Lehman, D.C. (2007). *Textbook of Diagnostic Microbiology*. New York, NY: WB Saunders Co.

Mallick, B.B., Chakrabarthy, R.I. & Chattopadhyay, S.K. (1970). Some observations on the naturally occurring cases of avian tuberculosis in ducks. *Indian Journal of Animal Health*, 9, 171-173.

Mateo, R. & Guitart, R. (2003). Heavy metals in livers of Waterbirds from Spain. *Archives of Environmental Contaminant Toxicology*, 44, 398-404.

Mendenhall, M.K., Ford, S.L., Emerson, C.L., Wells, R.A., Gines, L.G. & Eriks, I.S. (2000). Detection and differentiation of *Mycobacterium avium* and *Mycobacterium genavense* by polymerase chain reaction and restriction enzyme digestion analysis. *Journal of Veterinary Diagnostic and Investigation*, 12, 57-60.

Meyerholz, D.K., Vanloubbeeck, Y.E., Hoistetter, S.J., Jordan, D.M. & Fales-Williams, A.J. (2005). Surveillance of amyloidosis and other diseases at necropsy in captive trumpeter swans (*Cygnus buccinator*). *Journal of Veterinary Diagnostics and Investigation*, 17, 295-298.



Mijs, W., de Haas, P., Rossau, R., Van der Laan, T., Rigouts, L., Portaels, F. & van Soolingen, D. (2002). Molecular evidence to support a proposal to reserve the designation '*Mycobacterium avium* subsp. *avium*' for bird-type isolates and '*M. avium* subsp. *hominissuis*' for the human/porcine type of *M. avium*. *International Journal of Systematic Evolutionary Microbiology*, 52(Pt 5), 1505-1518.

Miller, H.C. & Lambert, D.M. (2004). Genetic drift outweighs balancing selection in shaping post-bottleneck major histocompatibility complex variation in New Zealand robins (Petroicidae). *Molecular Ecology*, 13, 3709–3721.

Miller, W.J. (2007). Ring-neck doves. Available on line at [www.ringneckdove.com](http://www.ringneckdove.com) (19 July 2007).

Mobius, P., Lentzsch, P., Moser, I., Naumann, L., Martin, G. & Kohler, H. (2006). Comparative macrorestriction and RFLP analysis of *Mycobacterium avium* subsp. *avium* and *Mycobacterium avium* subsp. *hominissuis* isolates from man, pig, and cattle. *Veterinary Microbiology*, 117, 284-291.

Mochizuki, M., Mori, M., Akinaga, M., Yugami, K., Oya, C., Hondo, R., & Fukiko, U. (2005). Thallium contamination in wild ducks in Japan. *Journal of Wildlife Diseases*, 41, 664-668.

Montali, R.J., Bush, M., Thoen, C.O. & Smith, E. (1976). Tuberculosis in captive exotic birds. *Journal of the American Veterinarian Medical Association*, 169, 920-927.

Morita, Y., Arai, M., Nomura, O., Maruyama, S. & Katsube, Y. (1994). Avian tuberculosis which occurred in an imported pigeon and pathogenicity of the isolates. *Journal of Veterinary Medical Sciences*, 56, 585-587.

Morita, Y., Maruyama, S., Kabeya, H., Nagai, A., Kozawa, K., Kato, M., Nakajima, T., Mikami, T., Katsube, Y. & Kimura, H. (2004). Genetic diversity of the *dnaJ* gene in the *Mycobacterium avium* complex. *Journal of Medical Microbiology*, 53, 813-817.

Naik, S. (2006). Can we look forward to genetic tests for tuberculosis susceptibility and severity? *Indian Journal of Medical Research*, 124, 379-382.

North, R.J. & Jung Y.J. (2004) Immunity to tuberculosis. *Annual Review in Immunology*, 22, 599-623.

O'Brien, S.J., Martenson, J.S., Miththapala, S., Janczewski, D.N., Pecon Slattery, J., Johnson, W.E., Gilbert, D.A., Roelke, M.E., Packer, C., Bush, M. & Wildt, D.E. (1996) Conservation genetics of the Felidae. In J.C. Avise & J.L. Hamrick. (Eds.). *Conservation Genetics: Case Histories from Nature* (pp. 50-74), New York, NY: Chapman and Hall.

Okamoto, H., Mizuno, K. & Horio, T. (2003). Monocyte-derived multinucleated giant cells and sarcoidiosis. *Journal of Dermatological Sciences*, 31, 119-128.

Oliver, K.W. (2005). *Ring-neck Doves: A Handbook of Care and Breeding*. Author's edition.

Pan, H., Yan, B.S., Rojas, M., Shebzukhov, Y.V., Zhou, H., Kobzik, L., Higgins, D.E., Daly, M.J., Bloom, B.R. & Kramnik, I. (2005). Ipr1 gene mediates innate immunity to tuberculosis. *Nature* 434, 767-772.

Phalen, D.N., Grimes, J.E., Phalen, S.W., McMurray, D.N. & Frahm, M. (1995). Serological diagnosis of mycobacterial infection in birds (preliminary report). In *Proceedings of the 16<sup>th</sup> Association of Avian Veterinarians Conference* (pp. 67-73), Philadelphia, PA, USA.

Phalen, D.N. (2000). Avian Mycobacteriosis. In J.D. Bonagura (ed). *Kirk's Current Veterinary Therapy XII* (pp. 1116-1118). New York, NY: WB Saunders Co.

Petersen, H. H., Nielsen, J. P. & Heegaard, M. H. (2004). Application of acute phase protein measurements in veterinary clinical chemistry. *Veterinary Research*, 35, 163-187.

Phillips, C.J., Foster, C.R, Morris, P.A. & Teverson, R. (2002). Genetic and management factors that influence the susceptibility of cattle to *Mycobacterium bovis* infection. *Animal Health Research Review*, 3, 1-13.

Pollock, C.G. (2006). Implications of mycobacteria in clinical disorders. In G.J. Harrison & T.L. Lightfoot (Eds.). *Clinical Avian Medicine* (pp. 681-688). Tampa, FL: Spix Publishing.

Pond, C.L. & Rush, H.G. (1981). Infection of white Carneaux pigeons (*Columbia livia*) with *Mycobacterium avium*. *Laboratory Animals Science*, 31, 196-199.

Portaels, F., Realini, L., Bauwens, L., Hirschel, B., Meyers W.M. & DeMeurichy, W. (1996). Mycobacteriosis caused by *Mycobacterium genavense* in birds kept in a zoo: 11-year survey. *Journal of Clinical Microbiology*, 34, 319-323.

Ramis, A., Ferrer, L., Aranaz, A., Liébana, E., Mateos, A., Domínguez, L., Pascual, C., Fernandez-Garayazabal, J. & Collins, M.D. (1996). *Mycobacterium genavense* infection in canaries. *Avian Diseases*, 40, 246-251.

Realini, L., De Ridder, K., Hirschel, B. & Portaels, F. (1999). Blood and charcoal added to acidified agar media promote the growth of *Mycobacterium genavense*. *Diagnostic Microbiology and Infectious Diseases*, 34, 45-50.

Riggs, G. (2005). Mycobacterial infection in waterfowl collections: a conservation perspective. In *Proceedings of the 26<sup>th</sup> Association of Avian Veterinarians Conference*, (pp. 70-76), Monterey Bay, CA, USA.

Roffe, T.J. (1989). Isolation of *Mycobacterium avium* from waterfowl with polycystic livers. *Avian Diseases*, 33, 195-198.

Rose, P.M. & Scott, D.A. (1997). *Waterfowl Population Estimates*. 2<sup>nd</sup> edition. Wageningen, The Netherlands, Wetlands International.

Sabočanec, R., Konjevič, D., Čurič, S., Cvetnić, Ž. & Špičić, S. (2006). Spontaneous *Mycobacterium avium* serovar 2 infection in a Muscovy Duck (*Cairina moschata*)-A case report. *Veterinarski Archives*, 76, 185-192.

Saggese, M.D. & Phalen, D.N. (2005). Serological and histological findings in doves with mycobacteriosis. In *Proceedings of the 26<sup>th</sup> Association of Avian Veterinarians Conference* (pp.71-73), Monterey Bay, CA, USA.

Saggese, M.D., Tizard, I. & Phalen, D.N. (2007a). Mycobacteriosis in naturally infected ring-neck doves (*Streptopelia risoria*): association of feather color with susceptibility to infection and disease and lesion type. *Chapter II. Ph. D dissertation*, Texas A&M University. College Station, Texas.

Saggese, M.D., Tizard, I. & Phalen, D.N. (2007b). Comparison of sampling methods and diagnostic techniques for the diagnosis of mycobacteriosis in ring-neck doves (*Streptopelia risoria*). *Chapter III. Ph. D dissertation*, Texas A&M University. College Station, Texas.

Saggese, M.D., Riggs, G., Tizard, I., Bratton, G., Taylor, R. & Phalen, D.N. (2007). Gross and microscopic findings and investigation of the aetiopathogenesis of mycobacteriosis in a captive population of white-winged ducks (*Cairina scutulata*). *Avian Pathology*, 36, 415-422.

Schmidt, R.E., Reavill, D.R. & D. Phalen. (2003). *Pathology of Pet and Aviary Birds*. Ames, IA: Blackwell Publishing.

Schurr, E (2007). Is susceptibility to tuberculosis acquired or inherited? *Journal of Internal Medicine*, 261, 106-111.

Smith, M.B., Boyars, M.C., Veasey, S. & Woods, G.L. (2000). Generalized tuberculosis in the acquired immune deficiency syndrome. A clinicopathologic analysis based on autopsy findings. *Archives of Pathology and Laboratory Medicine*, 124, 1267-1274.

Steinmetz, H.W., Rutz, C., Hoop, R.K., Grest, P., Bley, C.R. & Hatt, J.M. (2006). Possible human-avian transmission of *Mycobacterium tuberculosis* in a green-winged macaw (*Ara chloroptera*). *Avian Diseases*, 50, 641-645.

Stout, J.H., Trust, K.A., Cochrane, J.F., Suydam, R.S. & Quakenbusch, L.T. (2002). Environmental contaminants in four eider species from Alaska and Artic. *Russia Environmental Pollution*, 119, 215-226.

Supartika, I.K., Toussaint, M.J. & Gruys, E. (2006). Avian hepatic granuloma. A review. *Veterinary Quarterly*, 28, 82-89.

Taffik, H. (2001). The role of human genetic factors in susceptibility to tuberculosis. *Acta Cientifica Venezolana*, 52, Supplement 1, 16-18.

Tatum, L.M., Zaias, J., Mealey, B.K., Cray, C., Bossart, G.D. (2000). Protein electrophoresis as a diagnostic and prognostic tool in raptor medicine. *Journal of Zoo and Wildlife Medicine*, 31, 497-502.

Tell, L., Woods, L. & Cromie, R.L. (2001). Mycobacteriosis in birds. *Revue Scientifique et Technique, Office International des Epizooties, 1*, 180-203.

Tell, L., Woods, L., Foley, J., Needham, M.L. & Walker, R.L. (2003a). A model of avian mycobacteriosis: clinical and histopathologic findings in Japanese quail (*Coturnix coturnix japonica*) intravenously inoculated with *Mycobacterium avium*. *Avian Diseases, 47*, 433-443.

Tell L., Woods, L., Foley, J., Needham, M.L. & Walker, R.L. (2003b). Diagnosis of avian mycobacteriosis: comparison of culture, acid-fast stains and polymerase chain reaction for the identification of *Mycobacterium avium* in experimentally inoculated Japanese quail (*Coturnix coturnix japonica*). *Avian Diseases, 47*, 444-452.

Thoen, C.O. (1997). Tuberculosis. In Calnek, B.W. (ed.) *Diseases of Poultry*. 10th edition. Ames, IA: Iowa State University Press.

Thoen, C.O., & Himes, E.M. (1976). Isolation of *Mycobacterium avium* serotype 3 from a white-headed tree duck (*Dendrocygna viduata*). *Avian Diseases, 20*, 587-592.

Thompson, J.D., Gibson, T., Plewniak, J.F., Jeanmougin, F. & Higgins, D.G. (1997). The CLUSTAL X windows interface: flexible strategies for multiple sequence alignment aided by quality analysis tools. *Nucleic Acid Research, 25*, 4876-4882.



Tomioka, H. (2004). Present status and future prospects of chemotherapeutics for intractable infections due to *Mycobacterium avium* complex. *Current Drug Discoveries and Technology*, 1, 255-268.

Travis, E.K., Junge, R.E. & Terrell, S.P. (2007). Infection with *Mycobacterium simiae* complex in four captive Micronesian Kingfishers. *Journal of the American Veterinary Medical Association*, 230, 1524-1529.

Turenne, C.Y., Semret, M., Cousins, D.V., Collins, D.M. & Behr, M.A. (2006). Sequencing of hsp65 distinguishes among subsets of the *Mycobacterium avium* complex. *Journal of Clinical Microbiology*, 44, 433-440.

Van der Heyden, N. (1997). Clinical manifestations of mycobacteriosis in pet birds. *Seminars in Avian and Exotic Pets Medicine*, 6, 18-24.

Van der Schaaf, A., Hopmans, J.L. & Van Beek, J. (1976). Mycobacterial intestinal disease in woodpigeons (*Columbia palumbus*). *Tijdschr Diergeneeskd*, 101, 1084-1092.

Van Helden, P.D., Möller, M., Babb, C., Warren, R., Walzl, G., Uys, P. & Hoal, E. (2006). Tuberculosis epidemiology and human genetics. *Novartis Foundation Symposium*, 279, 17-31.

Werner, L. & Reavill, D.R. (1999). The diagnostic utility of serum protein electrophoresis. *Veterinary Clinics of North America Exotic Animal Practice*, 2, 651-662.

Zekarias, B., Ter Hurne, A.A., Landman, W.J., Rebel, J.M., Pol, J.M. & Gruys, E. (2002). Immunological basis of differences in disease resistance in the chicken. *Veterinary Research*, 33, 109-125.

Zsivanovits, H.P., Neumann, U., Brown, M.J. & Cromie, R.L. (2004). Use of an enzyme-linked immunosorbent assay to diagnose avian tuberculosis in a captive collection of wildfowl. *Avian Pathology*, 33, 571-575.

## APPENDIX A

Table A. 1. Selected clinical biochemistry and plasma protein electrophoresis value of infected and uninfected ring-neck doves (*Streptopelia risoria*).

| Variable             | Infected doves |             |                     | Uninfected doves |             |                   |
|----------------------|----------------|-------------|---------------------|------------------|-------------|-------------------|
|                      | n              | range       | mean $\pm$ SD       | n                | range       | mean $\pm$ SD     |
| Total protein (g/dl) | 16             | 2.1-4.5     | 2.994 $\pm$ 0.188   | 11               | 1-3.1       | 2.309 $\pm$ 0.175 |
| Albumin (g/dl)       | 16             | 0.235-1.140 | 0.686 $\pm$ 0.077   | 11               | 0.314-1.578 | 1.031 $\pm$ 0.091 |
| Globulins (g/dl)     | 16             | 0.965-3.448 | 2.006 $\pm$ 0.202   | 11               | 0.508-1.404 | 0.960 $\pm$ 0.087 |
| Alpha                | 16             | 0.296-0.734 | 0.5207 $\pm$ 0.0313 | 11               | 0.130-0.336 | 0.253 $\pm$ 0.01  |
| Beta                 | 16             | 0.416-2.039 | 0.857 $\pm$ 0.107   | 11               | 0.251-0.709 | 0.433 $\pm$ 0.042 |
| Gamma                | 16             | 0.203-1.501 | 0.628 $\pm$ 0.101   | 11               | 0.127-0.567 | 0.2739 $\pm$ 0.04 |
| AST (U/L)            | 16             | 41-423      | 136.2 $\pm$ 22.55   | 11               | 30-344      | 141.3 $\pm$ 26.21 |
| CK (U/L)             | 16             | 20-4242     | 654.9 $\pm$ 261.5   | 11               | 20-1191     | 404.6 $\pm$ 125.4 |
| UA (mg/dl)           | 16             | 2.3-7.6     | 5.450 $\pm$ 0.379   | 11               | 1.7-11.1    | 6.191 $\pm$ 0.832 |

## VITA

Miguel Daniel Saggese received his B.S. at University of Buenos Aires, Buenos Aires, Argentina, in 1995. He entered the Residence/Graduate School program at The Raptor Center, University of Minnesota in August 2001 and received his Master of Science degree in July 2004. His research interests include avian medicine and infectious diseases of companion and wild birds. He is currently an assistant professor in avian diseases and veterinary microbiology at Western University of Health Sciences, California.

Miguel Daniel Saggese may be reached at 309 E. Second Street, College of Veterinary Medicine, Western University of Health Sciences, Pomona, California 90012.

His email address is [msaggese@westernu.edu](mailto:msaggese@westernu.edu)