

Microsporidia and Human Infections

JOHN A. SHADDUCK^{1*} AND ELIZABETH GREELEY²

College of Veterinary Medicine, Texas A&M University, College Station, Texas 77843,¹ and Department of Veterinary Pathobiology, College of Veterinary Medicine, University of Illinois, Urbana, Illinois 61801²

INTRODUCTION	158
GENERAL CHARACTERISTICS OF ORGANISMS IN THE PHYLUM MICROSPORA.....	158
BIOLOGY AND LIFE CYCLE.....	158
TAXONOMY AND CLASSIFICATION.....	159
Genus <i>Encephalitozoon</i>	159
Genus <i>Nosema</i>	160
Genus <i>Pleistophora</i>	160
Genus <i>Enterocytozoon</i>	160
MORPHOLOGIC EVIDENCE OF HUMAN INFECTION.....	161
Genus <i>Encephalitozoon</i>	161
Genus <i>Nosema</i>	161
Genus <i>Pleistophora</i>	162
Genus <i>Enterocytozoon</i>	162
Genera Unknown	162
SEROLOGIC EVIDENCE OF HUMAN INFECTION	162
SOURCES OF HUMAN INFECTION	163
DIAGNOSTIC TECHNIQUES.....	163
THERAPY	163
BIOLOGY OF THE DISEASE IN ANIMALS	163
LITERATURE CITED.....	164

INTRODUCTION

Microsporidia are obligate intracellular parasites found in many vertebrates and invertebrates. The organisms are sufficiently unique to be classified in a separate phylum of protistan organisms, phylum Microspora (58). The parasites are characterized by the structure of their spores, which have a complex tubular extrusion mechanism used for injecting the infective material (sporoplasm) into host cells (12). These parasites are important causes of disease in several animal species, particularly rabbits, foxes, dogs, and squirrel monkeys (12, 53, 55). Recently, several members of the phylum Microspora have been recognized in human tissues and implicated as participants in human diseases (10, 11, 17).

GENERAL CHARACTERISTICS OF ORGANISMS IN THE PHYLUM MICROSPORA

All microsporidia are small, obligate intracellular parasites (12). Typical sizes for mammalian microsporidia range from 1.5 to about 5 μm wide and 2 to 7 μm long (12, 31). Many genera and species of parasites belong to the phylum Microspora. To date, however, only four genera (*Encephalitozoon*, *Nosema*, *Pleistophora*, and *Enterocytozoon*) have been recognized in humans. Of these, only the genus *Enterocytozoon* is unique to humans. Placement of microsporidia in the appropriate genus requires careful electron microscopic observation of the entire life cycle (12). Features of particular relevance include the size of the spore, the configuration of the nuclei in spores and developing forms, and the relationship between the parasite and the host cell (11). The number of coils of the polar tubule is often reported as

another identifying feature. All microsporidia share several common morphologic characteristics (12, 58).

Spores with polar tubules occur in all microsporidia, and the polar tubule is one of the principal features used to distinguish microsporidia from other protozoa. Other characteristics of the spore include a thick spore wall composed (in many species) of an electron-dense coat which may be smooth or irregular. Underlying the outer coat is a thick electron-lucent layer composed, in part at least, of chitin. Beneath this thick electron-lucent coat is another thin electron-dense coat enveloping the spore organelles. In addition to the polar tubule with its anchoring disk and the polar vacuole, other organelles such as ribosomes and nuclei can be recognized, but mitochondria are absent (12).

Spores have a complex tubular extrusion mechanism used to inject the sporoplasm into new host cells. The extrusion mechanism consists of a polar tubule coiled inside the spore wall and attached to an anchoring disk. The free end of the polar tubule envelops or is attached to the nuclear material which upon extrusion is named the sporoplasm. In response to environmental stimuli (such as pressure or pH changes), a polar vacuole situated at the opposite end of the spore from the anchoring disk suddenly distends and the subsequent intracellular pressure everts the polar tubule with its attached sporoplasm. The force of eversion is sufficient to "inject" sporoplasm into the new host cell. It is not yet clear whether this mechanism is the most common one used for infecting mammalian cells, but it is an important mechanism of infection of invertebrate cells (12).

BIOLOGY AND LIFE CYCLE

Microsporidia are true eucaryotes because they have a nucleus with a nuclear envelope and an array of intracytoplasmic membranes. Nuclear configuration differs, however,

* Corresponding author.

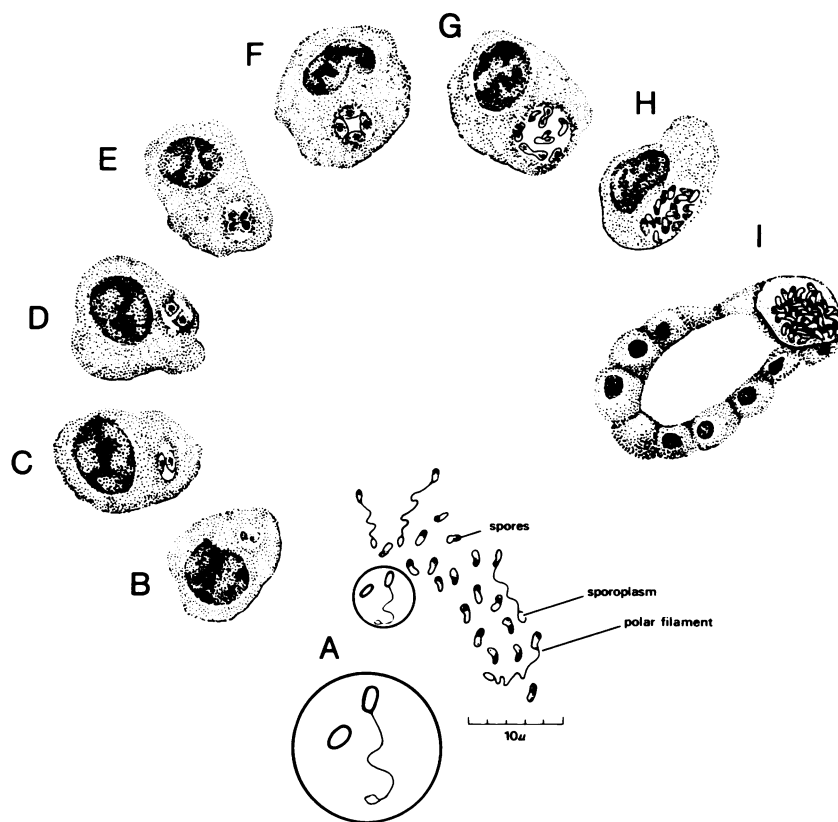


FIG. 1. Diagram of the life cycle of *E. cuniculi* in a renal tubular epithelial cell. A, Mature spores, some with extruded polar tubules (filament) and attached sporoplasm. B to G, Proliferation takes place in parasitophorous vacuoles with most immature forms in close opposition to the wall of the vacuole. H and I, Maturing forms and spores accumulate in the enlarging vacuole, which eventually ruptures. Enlargement of A shows attachment of spore to sporoplasm by polar tubule (filament). From reference 25, with permission of the publisher.

among genera of microsporidia. In some, two nuclei are arranged as a tightly joined pair (called a diplokaryon), whereas in others the nucleus is single (12). In *Enterocytozoon* (37), diplokarya may occur early in the life cycle while single nuclei occur at later stages. In other genera the nuclear configuration is constant as either a single (e.g., *Encephalitozoon*) (43) or double (e.g., *Nosema*) (34) nucleus throughout the life cycle. When organisms with diplokarya divide, each diplokaryon divides producing, albeit briefly, "double diplokarya." Chromosomes separate on mitotic spindles without centrioles.

Recent studies suggest that microsporidia resemble prokaryotes in many respects. In particular, a representative microsporidian (*Vairimorpha necatrix*) has been shown to have small (70S) ribosomes which contain 16S and 23S ribosomal ribonucleic acids (RNAs), typical of prokaryotes. Microsporidia seem to lack eucaryotic 5.8S RNA, but they do have a large (23S) single prokaryote-like ribosomal RNA subunit which contains sequences that correspond to the 5.8S ribosomal RNA subunit typical of eucaryotes. The 16S subunit ribosomal RNA is far shorter than that of the typical eucaryotic (18S) ribosomal RNA, and there is little homology between the small subunit ribosomal RNAs of microsporidia and other eucaryotes (16, 65, 66). It has been suggested, therefore, that microsporidia arose as a very early branch of eucaryotes. This has led to the assumption that the absence of mitochondria, peroxisomes, Golgi membranes, and other typical eucaryotic structures is evidence of the primitive divergence of microsporidia rather than loss of previously differentiated characteristics.

Microsporidia multiply extensively in the cytoplasm of appropriate host cells (12) (Fig. 1). The general pattern of division includes a phase of repeated divisions by binary fission (merogony) or multiple fission (schizogony) and a phase culminating in spore production (sporogony). Merogony and sporogony may occur concomitantly in the same infected host cell. In the host cell, division may take place with the parasite surrounded by a protective membrane of either host or parasite origin or with the parasites free in the host cytoplasm. During sporogony, a sporont divides by either binary or multiple fission to form sporoblasts which mature without further division into spores. The sporogonic phases of parasite development are characterized by a dense amorphous surface coat deposited on the plasma membrane as well as a continuously thickening spore wall and the development of increasingly complex cytoplasmic organelles until the final maturation is achieved in the mature spore.

TAXONOMY AND CLASSIFICATION

Genus *Encephalitozoon*

Parasites of the four genera affecting humans can be distinguished by their developmental cycle and host-parasite relationships in infected cells. *Encephalitozoon cuniculi* develop within host cells in vacuoles bounded by a membrane that is thought to be of host cell origin (43). *Encephalitozoon* sp. has been recognized in numerous mammalian species, including humans, and in each case the parasites are morphologically and antigenically indistinguishable (40). There-

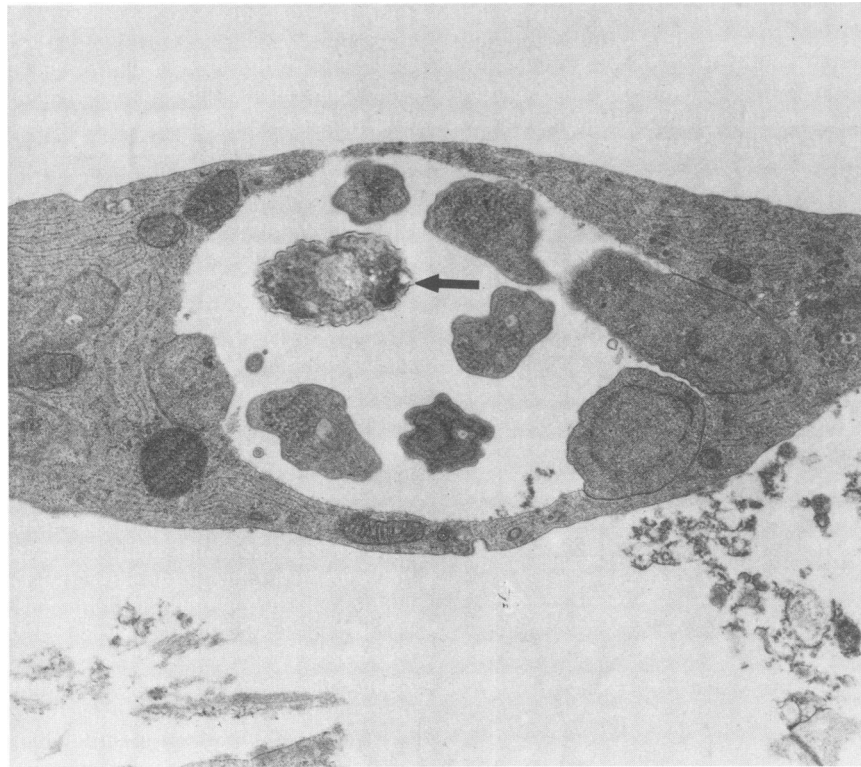


FIG. 2. Developing forms of *E. cuniculi* are seen embedded in the wall of a parasitophorous vacuole in a rabbit choroid plexus cell in cell culture. An early spore is in the lumen of the vacuole (arrow). From reference 69, with permission of the publisher.

fore, all are classified as *E. cuniculi* (12). Typically, meronts are rounded and oval or slightly irregular structures which measure approximately 2 to 6 by 1 to 3 μm . The parasites in this stage divide repeatedly by binary fission and at each stage have only a single nucleus (at no time in the life cycle is there a diplokaryon arrangement). Meronts occur isolated in small vacuoles or at the edge of larger vacuoles in close contact with the vacuolar membrane (Fig. 2). Meronts have a simple plasma membrane, isolated single nuclei, and scanty simple cytoplasmic organelles. After multiple divisions, meronts enter sporogony, during which the plasma membrane tends to thicken and the organelles become more complex. Finally, each sporont divides into two nucleated sporoblasts which display an increased volume of endoplasmic reticulum and mature cytoplasmic organelles. The sporoblasts further thicken their cell wall, a process which begins on the free surface away from the vacuole membrane and is completed when the sporoblast lies free in the center of the cytoplasmic vacuole. The spores are ellipsoid and measure approximately 2.5 by 1.5 μm (Fig. 3). They have a corrugated exospore surface, a thick endospore, four to seven (usually five or six) coils of the polar tubules, and often a polar vacuole (43).

Genus *Nosema*

Nosema connori (57) has been recognized in human tissue only as sporoblasts with immature and mature spores (34). Some of the structures lie in cysts bounded by membranes, but most of the parasites are in direct contact with the cytoplasm. Spores are oval, measuring approximately 4 by 2 μm . Nuclei in the diplokaryon arrangement are seen in all forms. The polar tube has about 11 coils. Despite the paucity

of information about developmental stages, the parasite was tentatively assigned to the genus *Nosema* (57) on the basis of the diplokaryon arrangement in the sporoblasts and spores plus the absence of either a pansporoblastic membrane or a parasitophorus vacuole.

Genus *Pleistophora*

Organisms resembling microsporidia of the genus *Pleistophora* have been recognized in one human patient (30). In this patient, atrophic and degenerating muscle fibers were infiltrated by spores which occurred in clusters of at least 12 organisms, each cluster enclosed by an enveloping membrane. The spores were oval, approximately 2.8 by 3.4 μm . Not all developmental stages were seen. There was clear evidence of a process of sporogony in which multiple spores developed from a single sporont within a membrane, frequently referred to as the pansporoblastic membrane. The spore wall is typical for many microsporidia, having a thin electron-dense exospore layer, a thick electron-lucent endospore, and a thin internal plasmalemma. Approximately 11 cross sections of the polar tubule were recognized in spores.

Genus *Enterocytozoon*

Enterocytozoon bienusi is the microsporidian parasite most commonly recognized in humans and, so far, has been detected only in enterocytes (11, 19, 20, 37; W. K. Gourley and T. L. Swedo, Lab. Invest. 58:35A, 1988). All stages are seen in direct contact with the host cell cytoplasm. Early developmental stages may have diplokaryotic nuclei (this observation is in dispute), but later stages display isolated

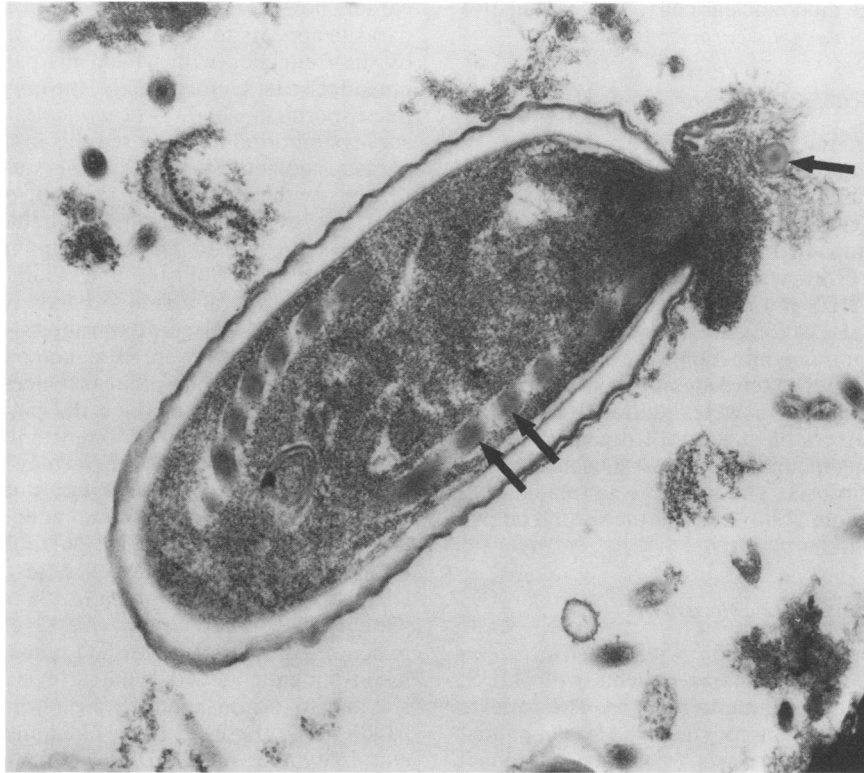


FIG. 3. Mature spore of *E. cuniculi* in the process of extrusion of the polar tubule. The tubule is seen in cross section outside the spore and in tangential section within the spore (arrows). The outer and inner thin electron-dense and thick electron-lucent layers of the spore wall are obvious.

nuclei. The parasites are small, approximately 2 to 4 μm in diameter, and have a simple plasma membrane during the early stages of division. During sporogony, multinucleate sporogonial plasmodia develop. As the exospore coat is deposited on the plasma membrane, the nuclei become isolated. The differentiating primordia of the anchoring disks of the polar tube develop in association with each nucleus, and at a slightly later stage four to five coils of the polar tube can be visualized. After the polar tube anchoring device and other membranous structures are fully differentiated, the sporogonial plasmodium divides into distinct sporoblasts. The sporoblasts, which are uninucleate, mature into spores by condensation of their cytoplasm and deposition of an electron-lucent endospore layer beneath the exospore coat. Spores are approximately 1.5 by 0.5 μm in tissue section and differ from other microsporidia by having a very thin endospore layer.

MORPHOLOGIC EVIDENCE OF HUMAN INFECTION

Genus *Encephalitozoon*

Only one species of *Encephalitozoon* (*E. cuniculi*) is known. The first reported human infection of microsporidia was reported in 1959 in a 9-year-old Japanese boy who suffered from a severe neurological illness characterized by convulsions, vomiting, headaches, fever, and periods of unconsciousness (35). Oval bodies, thought by light microscopy to be *Encephalitozoon* spp., were recognized in the cerebrospinal fluid and urine of the child. *Encephalitozoon* spp. also were recovered from mice inoculated with these fluids, but this report must be interpreted cautiously since

mice are now known to be latently infected with *E. cuniculi*. Nevertheless, the direct observation of the *Encephalitozoon*-like organisms in cerebrospinal fluid has been accepted as evidence of infection (11, 12). The patient was treated with sulfisoxazole and recovered. A second child, aged 2 years, born in Colombia but a resident of Sweden, was afflicted by a similar illness of several months' duration (6). Spores were recognized in the urine twice. The parasites from urine were stained by immunofluorescence with anti-*Encephalitozoon* antisera. Inoculation of urine samples into *Encephalitozoon*-free mice gave rise to infection in mice. Anti-*E. cuniculi* antibodies were detected in the patient's serum. The child is apparently still alive but was lost to follow-up. Terada et al. (59) recently described the ultrastructural appearance of an *E. cuniculi*-like organism in a liver biopsy from a patient with acquired immunodeficiency syndrome (AIDS) (24). Lesions included suppurative necrosis and granulomas involving predominantly the portal tracts.

Genus *Nosema*

The single reported case of human infection with the microsporidian parasite *N. connori* was a disseminated fatal infection in a 4-month-old infant with combined immunodeficiency disease (34). Parasites were widely distributed in the myocardium, diaphragm, media of the arterial walls in many organs, and in kidney tubules, adrenal cortex, liver, and lungs. Despite the widespread distribution of the parasite and large numbers of organisms in many cells and tissues, little host response occurred except in the diaphragm, where there was a marked interstitial inflammatory infiltrate com-

posed primarily of large mononuclear cells. This patient also was afflicted with *Pneumocystis carinii* pneumonia.

Genus *Pleistophora*

One case of human infection thought to be due to a parasite belonging to the genus *Pleistophora* has been reported (30). The patient was a 20-year-old man with a 7-month history of progressive generalized muscle weakness and contractions accompanied by fever, generalized lymphadenopathy, and an 18-kg weight loss. The patient was diagnosed as having AIDS not associated with human immunodeficiency virus (HIV) (32). Lesions apparently associated with the microsporidian infection were described from two sets of muscle biopsies taken 5 months apart. Atrophic and degenerating muscle fibers were infiltrated by spores which occurred in clusters of at least 12 organisms each, surrounded by enclosing membranes. Later muscle biopsies showed scarring and fibrosis. The patient was treated with trimethoprim-sulfisoxazole, followed after the second biopsy by sulfadiazine.

Genus *Enterocytozoon*

At least seven cases of infection with *Enterocytozoon bienusi* have been reported in human patients with AIDS. The organism is apparently unique to humans. The parasite has been found infesting the enterocytes of a Haitian patient with AIDS who also had giardiasis (19). Two additional patients with intestinal infections were described by Gourley and Swedo (Lab. Invest. 58:35A, 1988). Other patients with infections of the small intestine have been reported by Rijpstra et al. (47), Dobbins and Weinstein (20), and Owen (R. L. Owen, Abstr. Annu. Meet. Am. Soc. Microbiol. 1987, J18, p. 202). Modigliani et al. (37) also reported a parasite, possibly *Enterocytozoon* sp., in one of four patients with AIDS and a tentative diagnosis of *Enterocytozoon* sp. was reported in a British AIDS patient (18). Microsporidia were identified by light microscopy in semithin plastic sections of intestinal-biopsy specimens from 13 patients with AIDS. These identifications were confirmed for all 13 patients by electron microscopy, and microsporidia were found only by electron microscopy in intestinal biopsies from 6 additional AIDS patients (J. Orenstein, F. Jannotta, W. Steinberg, J. Keiser, P. Smith, D. Kotter, H. Rotterdam, and J. Chiang, Lab. Invest. 60:68A, abstr. no. 405, 1989).

Genera Unknown

Two cases of corneal infection have been reported in the literature (2, 46) and we are aware of a third (R. M. Davis, personal communication). Unfortunately, it was not possible to determine precisely the genus and species of the parasites, but they have been variously placed in the genus *Nosema* or a new genus, *Microsporidium* (12).

There are several reports in which bodies or structures have been incorrectly identified as microsporidia and thus attributed as contributing to human disease (32, 60, 64). Several of these erroneous attributions have been corrected (3, 11, 13).

SEROLOGIC EVIDENCE OF HUMAN INFECTION

Several serologic surveys in selected human populations suggest that antibodies against *E. cuniculi* occur relatively commonly in some groups of people (5, 26, 56). As noted

earlier, however, the most common human microsporidian parasite appears to be *Enterocytozoon* sp., at least as judged by the frequency with which this parasite is recognized in human tissues. Unfortunately, the only available mammalian microsporidian isolate is *E. cuniculi*; therefore, all serologic surveys reported to date used this organism as the source of parasite antigens. Whether these surveys reveal actual infections with *Encephalitozoon* spp. or other microsporidia with cross-reacting antigens or whether these positive serologic tests for *Encephalitozoon* spp. are spurious remains to be determined. Hollister and Canning (26) reported the presence of several common bands on immunoblots, using known positive antisera from rabbits, mice, and dogs. When positive human sera were used, comparable bands reacted in some instances, but in other instances they did not.

The frequency with which the positive serologic results are being reported by different investigators in various populations suggests that there may well be latent human microsporidian infections, if not due to *Encephalitozoon* spp., then at least caused by an antigenically related organism or organisms. Singh et al. (56) found antibody by the use of indirect immunofluorescence tests in 33 of 92 (36%) Ghanaian patients with malaria, 38 of 89 (43%) Nigerian patients with tuberculosis, and 13 of 70 (19%) Malaysian patients with filariasis. An additional 263 sera were examined from patients with typhoid fever, leprosy, toxoplasmosis, and toxocariasis and from normal persons and animal handlers. Of these, 11 (4.2%) had antibody against *E. cuniculi*. In another study (5), 30 sera from homosexual Swedish men were examined (again by indirect immunofluorescence), and 10 (33%) were positive for antibodies to *E. cuniculi*, 11 (37%) were positive for antibodies to *Toxoplasma gondii*, and 13 (43%) were positive for antibodies against *P. carinii*. In this study all 10 of the patients who were positive for antibody to *E. cuniculi* had traveled to tropical countries. This finding was consistent with another report (70) in which 14 of 105 (13%) healthy Swedes returning from visits to the tropics had antibodies to *E. cuniculi*. In this study also, 38 of 100 (38%) sera from patients with malaria were positive for *E. cuniculi* as were 2 of 23 (8.7%) from patients with filariasis, and 8 of 54 (15%) sera from patients with Chagas' disease. Unfortunately, none of these studies included the use of immunoblots. The utility of the immunoblot technique has been demonstrated not only by the work of Hollister and Canning (26), but also by another study in which the reactivity of serum from an infected child against *E. cuniculi* was confirmed on immunoblots (70). In this case, the patient's serum reacted with at least 12 different bands on a sodium dodecyl sulfate-polyacrylamide gel electrophoretic preparation of *E. cuniculi*.

Hollister and Canning (26) examined sera from patients with schistosomiasis, and 21 of 175 (12%) were positive for *E. cuniculi* by the use of an enzyme-linked immunosorbent assay technique. In the same study, sera from 34 of 451 (7.5%) malaria patients and 10 of 159 (6.3%) neurological disease patients, but none from normal persons, were positive. In a study conducted in the United States, 7 of 11 (64%) HIV antibody-positive patients with clinical AIDS were positive in an immunofluorescence test against *E. cuniculi*, 5 of 5 (100%) HIV-positive patients with AIDS-related complex were positive, and 1 of 2 patients who were HIV positive but asymptomatic also had antibodies against *E. cuniculi*; thus, 13 of 18 (72%) HIV-positive patients were also positive for antibodies to *E. cuniculi* (R. H. Sacks, personal communication). Of 33 normal patients used as controls, (33%) also had antibodies to *E. cuniculi*.

Some concern has been expressed about cross-reactivity of antigens among insect and mammalian microsporidia, and indeed some cross-reactivities have been demonstrated (41). Other workers have found minimal evidence of cross-reacting antigens (25, 27). Obviously, one could have more confidence in the serological results if human isolates were available as sources of antigens. Nevertheless, the data seem highly suggestive that latent human infections with microsporidia occur. In animal studies, the data show quite clearly that animals with positive anti-*E. cuniculi* immunoglobulin G titers are latently infected (15, 49, 53), and that several serological techniques are useful for detecting antibodies (4, 38, 44).

SOURCES OF HUMAN INFECTION

Sources of infections for human patients are not known (9). The possibilities include spread from other infected persons or spread from infected animals, birds, lower vertebrates, or invertebrates (8, 22, 29). In animals, transplacental transmission of *E. cuniculi* takes place (27) and seems to be important in the pathogenesis of the disease, especially in foxes (39), dogs (8), and squirrel monkeys (71). In other species such as mice and rabbits, the most important source of infections is horizontal spread, probably via contaminated urine (14, 15). Whether insect microsporidia can serve as sources of human infections is unknown. There is evidence of limited multiplication of one insect microsporidian (*Nosema algerae*) in the tail skin of euthymic and athymic mice (63), but another insect organism (*Nosema locustae*) did not replicate (Shaddock, unpublished data). *N. algerae* grows in pig kidney cells in vitro only at temperatures below 28°C (62). *Enterocytozoon* sp. has been reported only in humans. Whether it has a reservoir host is unknown.

DIAGNOSTIC TECHNIQUES

There are several techniques for recognizing microsporidia in human material. The organisms have been demonstrated by light microscopy in human cerebrospinal fluid (35) and urine and recognized by immunofluorescence in smears of these fluids (6). Proper identification of the organisms requires careful attention to the preparative technique. Since microsporidia are so small, they may be inadequately centrifuged from specimens, improperly stained, or mistaken for bacteria. Gram, acid-fast, and periodic acid-Schiff techniques as well as Giemsa stain are useful approaches to the evaluation of sediments from body fluids (12). Spores are gram positive, and portions of the internal spore structure are acid fast and periodic acid-Schiff positive. Giemsa-stained organisms are easier to see in histological sections than those stained with hematoxylin and eosin. If the limited reports are reflective of the general human population, it can be predicted that organisms will be shed sporadically in urine. This has been shown to be true in infected animals (8, 14), necessitating repeated examination of urine sediments before the parasites will be successfully identified in most patients.

In tissue sections, parasites are small and often stain very poorly with hematoxylin and eosin (53). Careful examination is crucial since the parasites may be widely scattered and occur in the absence of detectable tissue responses. Again, the use of special staining techniques, especially Gram, Giemsa, acid-fast, and immunohistochemical techniques (21, 68), are invaluable in detecting the parasites. The organisms also are refractile and sometimes can be recognized by the

use of a polarizing microscope even in poorly stained material (47). Careful electron microscopic examination also is indicated both to detect the presence of the organisms and to classify them appropriately (11, 12; Owen, Abstr. Annu. Meet. Am. Soc. Microbiol. 1987). As noted above, ultrastructural evaluation of the nuclear configuration, relationship of parasite and host cell, numbers of dividing forms from each meront or sporont, and numbers of coils in the polar filament are all important for proper parasite classification.

E. cuniculi can be cultivated successfully in vitro in a variety of cell cultures (50, 52, 54). This technique has been unreliable as a diagnostic tool when used to detect parasites in animal tissues. Ground tissue from an infected animal may or may not contain sufficient viable organisms to be detected in cell culture in vitro. Nevertheless, attempts to grow parasites from human specimens is strongly encouraged since this approach might result in the recovery of human isolates. Saving unfixed patient material in sterile phosphate-buffered saline or tissue culture-balanced salt solutions at -70°C or colder offers the opportunity to recover viable organisms by cultivation in cell cultures or in *E. cuniculi*-free athymic mice.

THERAPY

There is no known therapy for microsporidium infections. Some patients have been treated with sulfa drugs and have survived (30, 35), and trimethoprim-sulfisoxazole has been shown to have some effect on *E. cuniculi* growing in vitro (67). The antibiotic fumagillin is highly effective against *E. cuniculi* growing in vitro (51), but the only formulation available is intended for use in honey bees and is toxic to mammals.

BIOLOGY OF THE DISEASE IN ANIMALS

Microsporidia are ubiquitous parasites of a number of experimental animals and frequently are encountered as latent contaminants (53). The reported prevalence in rabbits ranges from 15 to 90%, and for mice and rats prevalence values are 20 to 50% (53). Both vertical and horizontal transmission occurs (12, 27).

Mice and rabbits have clinically silent persistent infection (7). Mice with clinically inapparent *Encephalitozoon* spp. are more resistant to experimental induction of tumors than uninfected animals, and the tumor growth rate is slower (1, 45, 61). Occasionally, transplantable tumors become contaminated by acquiring the protozoan from latently infected animals during the course of animal-to-animal passage; these infected tumors often demonstrate altered biological behavior (45). Immunologic changes in infected mice include elevated natural killer cell activity (42), activated macrophages, and transient but profound depression of lymphocyte blastogenic responses to several mitogens (48, 49). These alterations may explain the changes in tumor biology in infected animals. In infected rabbits there is a high frequency of focal granulomas and necrotic lesions in the brain, and infected rabbits also have severe chronic, non-suppurative, interstitial nephritis (12, 53).

In contrast to the disease in rabbits and rodents, microsporidiosis in young carnivores is a severe, clinically obvious, and usually fatal disease (8, 39). Lesions include severe meningoencephalitis, nephritis, and arteritis, and organisms occur in the brain, kidneys, spleen, and liver (36). Encephalitozoonosis in foxes raised commercially in Scan-

dinavia is similar to the disease in dogs but much more severe. The parasite is transmitted transplacentally, and, in addition to the lesions described above, affected foxes have polyarteritis nodosa and hypergammaglobulinemia (39).

Athymic mice infected with *E. cuniculi* die of the disease (23, 49), but they can be protected by administration of sensitized T cells from syngeneic euthymic donors (48). Immune serum alone and macrophages alone do not protect (48). Lymphokines generated in cultures of sensitized spleen cells from euthymic mice stimulated in vitro by *E. cuniculi* antigens activate macrophages to kill the parasite (48). It is presumed that a comparable mechanism occurs in vivo. Phagosomes do not fuse with either free parasites or parasites in parasitophorous vacuoles unless infected macrophages are activated by lymphokines or parasites are coated with specific immunoglobulins. Antibody is produced during latent infections, and persistence of antibody is indicative of latent infection with the parasite, but does not afford protection.

Encephalitozoon infection of newborn nonhuman primates is a severe, clinically apparent, and frequently fatal disease (71). Afflicted newborns and fetuses have severe encephalitis, hepatitis, nephritis, and arteritis, and organisms are seen frequently in the tissues (71). In a serologic study of an infected colony of squirrel monkeys, more than 70% of the sera from 286 monkeys were positive on at least one occasion for antibodies against *E. cuniculi* (J. A. Shadduck and G. B. Baskin, submitted for publication). Encephalitozoonosis can be produced experimentally in vervet monkeys, but the clinical disease is mild (A. van Dellen, personal communication).

In animals, host-parasite relationships can be placed in three major categories with considerable overlap. The relationships are the following: (i) parasite proliferation in the absence of effective host defense, seen in athymic mice in vivo and cell cultures in vitro; (ii) acute, clinically detectable, potentially fatal disease, seen in neonatal dogs, foxes, and squirrel monkeys (survivors may self-cure); (iii) resistant, clinically silent infection, seen in euthymic mice and rabbits of all ages and dogs, foxes, and squirrel monkeys infected as adults. Limited evidence from squirrel monkeys suggests that some may also self-cure, at least if loss of detectable antibody can be taken as evidence of cure.

It seems reasonable to predict that additional reports of human infections will appear and evidence for latent infections will become more convincing. More than one host-parasite relationship may occur in humans, depending on the infecting organism and the adequacy of host defenses. Immunologically impaired patients are likely to be at increased risk, and in all likelihood infection with these parasites will be shown to contribute to their disease. Data from the infected squirrel monkey colony in which newborns and placentas were infected (71) and the occurrence of other microsporidia in immunodeficient humans suggest that it would be especially useful to evaluate carefully the placenta and newborn infants of AIDS-infected women for evidence of infection with microsporidia.

LITERATURE CITED

- Arison, R. N., J. A. Cassaro, and M. P. Pruss. 1966. Studies on a murine ascites-producing agent and its effect on tumor development. *Cancer Res.* **26**:1915-1920.
- Ashton, N., and P. A. Wirasinha. 1973. Encephalitozoonosis (Nosematosis) of the cornea. *Br. J. Ophthalmol.* **57**:669-674.
- Barker, R. J. 1974. The nature of *Encephalitozoon brumpti* Coulon, 1924. *J. Parasitol.* **60**:542-544.
- Beckwith, C., N. C. Peterson, J. J. Liu, and J. A. Shadduck. 1988. Dot-enzyme linked immunosorbent assay [dot-ELISA] for antibodies to *Encephalitozoon cuniculi*. *Lab. Anim. Sci.* **38**:573-576.
- Bergquist, N. R., L. Morfeldt-Mansson, P. O. Pehrson, B. Petrini, and J. Wasserman. 1984. Antibody against *Encephalitozoon cuniculi* in Swedish homosexual men. *Scand. J. Infect. Dis.* **16**:389-391.
- Bergquist, N. R., G. Stintzing, L. Smedman, T. Waller, and T. Andersson. 1984. Diagnosis of encephalitozoonosis in man by serological tests. *Br. Med. J.* **288**:902.
- Bismanis, J. E. 1970. Detection of latent murine nosematosis and growth of *Nosema cuniculi* in cell cultures. *Can. J. Microbiol.* **16**:237.
- Botha, W. S., A. F. van Dellen, and C. G. Stewart. 1979. Canine encephalitozoonosis in South Africa. *J. S. Afr. Vet. Med. Assoc.* **50**:135-144.
- Bywater, J. E. C. 1979. Is encephalitozoonosis a zoonosis? *Lab. Anim.* **13**:149-151.
- Cali, A., and R. L. Owen. 1988. Microsporidiosis, p. 929-950. In A. Balows, W. J. Hausler, Jr., and E. H. Lennette (ed.), *Laboratory diagnosis of infectious diseases, principles and practice*, vol. 1. Bacterial, mycotic and parasitic diseases. Springer-Verlag, New York.
- Canning, E. U., and W. S. Hollister. 1987. Microsporidia of mammals—widespread pathogens or opportunistic curiosities? *Parasitol. Today* **3**:267-273.
- Canning, E. U., and J. Lom. 1986. The microsporidia of vertebrates. Academic Press, Inc., New York.
- Chalupsky, J., P. Lensky, P. Bedrnik, and J. Vavra. 1972. An attempt to demonstrate the connection between multiple sclerosis and *Encephalitozoon cuniculi* infection. *J. Protozool. Suppl.* **19**:76-77.
- Cox, J. C. 1977. Isolation of *Encephalitozoon cuniculi* from urine samples. *Lab. Anim.* **11**:233-234.
- Cox, J. C., H. A. Gallichio, D. Pye, and N. B. Walden. 1977. Application of immunofluorescence to the establishment of an *Encephalitozoon cuniculi*-free rabbit colony. *Lab. Anim. Sci.* **27**:204-209.
- Curgy, J. J., J. Vavra, and C. Vivares. 1980. Presence of ribosomal RNAs with prokaryotic properties in *Microsporidia*, eukaryotic organisms. *Biol. Cell.* **38**:49-51.
- Current, W. L., and R. L. Owen. 1989. Cryptosporidiosis and microsporidiosis, p. 223-249. In M. J. G. Farthing and G. T. Keusch (ed.), *Enteric infection: mechanisms, manifestations and management*. Chapman & Hall, Ltd., London.
- Curry, A. L., J. McWilliam, N. Y. Hagboubi, and B. K. Mandal. 1988. Microsporidiosis in a British patient with AIDS. *J. Clin. Pathol.* **41**:477-478.
- Desportes, I., Y. Le Charpentier, A. Galian, F. Bernard, B. Cochand-Priolet, A. Lavergne, P. Ravisse, and R. Modigliani. 1985. Occurrence of a new microsporidian: *Enterocytozoon bieneusi* n. g., n. sp., in the enterocytes of human patients with AIDS. *J. Protozool.* **32**:250-254.
- Dobbins, W. O., III, and W. M. Weinstein. 1985. Electron microscopy of the intestine and rectum in acquired immunodeficiency syndrome. *Gastroenterology* **88**:738-749.
- Gannon, J. 1978. The immunoperoxidase test diagnosis of *Encephalitozoon cuniculi* in rabbits. *Lab. Anim.* **12**:125-127.
- Gannon, J. 1980. A survey of *Encephalitozoon cuniculi* in laboratory animal colonies in the United Kingdom. *Lab. Anim.* **14**:91-94.
- Gannon, J. 1980. The course of infection of *Encephalitozoon cuniculi* in immunodeficient and immunocompetent mice. *Lab. Anim.* **14**:189-192.
- Gordon, S. C., K. R. Reddy, E. E. Gould, R. McFadden, C. O'Brien, M. de Medina, L. J. Jeffers, and E. R. Schiff. 1986. The spectrum of liver disease in acquired immunodeficiency syndrome. *J. Hepatol.* **2**:475-484.
- Greene, C. 1984. Clinical microbiology and infectious diseases of the dog and cat, p. 782. The W. B. Saunders Co., Philadelphia.
- Hollister, W. S., and E. U. Canning. 1987. An enzyme-linked immunosorbent assay (ELISA) for detection of antibodies to

- Encephalitozoon cuniculi* and its use in determination of infections in man. *Parasitology* 94:209–219.
27. Hunt, R. D., N. W. King, and H. L. Foster. 1972. Encephalitozoonosis: evidence for vertical transmission. *J. Infect. Dis.* 126:212–214.
 28. Irby, W. S., Y. S. Huang, C. Y. Kawanishi, and W. M. Brooks. 1986. Immunoblot analysis of exospore polypeptides from some entomophilic *Microsporidia*. *J. Protozool.* 33:14–20.
 29. Kemp, R. L., and J. P. Kluge. 1975. *Encephalitozoon* sp. in the blue-masked lovebird, *Agapornis personata* (Reichenow): first confirmed report of microsporidian infection in birds. *J. Protozool.* 22:489–491.
 30. Ledford, D. K., M. D. Overman, A. Gonzalvo, A. Cali, S. W. Mester, and R. F. Lockey. 1985. Microsporidiosis myositis in a patient with acquired immunodeficiency syndrome. *Ann. Intern. Med.* 102:628–630.
 31. Levine, N. D., J. O. Corliss, F. E. G. Cox, G. Deroux, J. Grain, B. M. Honigberg, G. F. Leedale, A. R. Loeblich III, J. Lom, D. Lynn, E. G. Merinfeld, F. C. Page, G. Poljansky, V. Sprague, J. Vavra, and F. G. Wallace. 1980. A newly revised classification of the protozoa. *J. Protozool.* 27:37–58.
 32. Macher, A. M., R. Neafie, E. Angritt, and S. M. Tuur. 1988. Microsporidial myositis and the acquired immunodeficiency syndrome (AIDS): a four-year follow-up. *Ann. Intern. Med.* 109:343.
 33. Marcus, P. B., J. J. van der Walt, and P. J. Burger. 1973. Human tumor microsporidiosis. *Arch. Pathol.* 95:341–343.
 34. Margileth, A. M., A. J. Strano, R. Chandra, R. Neafie, M. Blum, and R. M. McCully. 1973. Disseminated nosematosis in an immunologically compromised infant. *Arch. Pathol.* 95:145–150.
 35. Matsubayashi, H., T. Koike, T. Mikata, and S. Hagiwara. 1959. A case of *Encephalitozoon*-like body infection in man. *Arch. Pathol.* 67:181–187.
 36. McCully, R. M., A. F. Van Dellen, P. A. Basson, and J. Lawrence. 1978. Observations on the pathology of canine microsporidiosis. *Onderstepoort J. Vet. Res.* 45:75–92.
 37. Modigliani, R., C. Bories, Y. Le Charpentier, M. Salmeron, B. Messing, A. Galian, J. C. Rambaud, A. Lavergne, B. Cochand-Priollet, and I. Desportes. 1985. Diarrhea and malabsorption in acquired immune deficiency syndrome: a study of four cases with special emphasis on opportunistic protozoan infestation. *Gut* 26:179–181.
 38. Mohn, S. F. 1982. Encephalitozoonosis in the blue fox. Comparison between the India-ink immunoreaction and the indirect immunofluorescent antibody test in detecting *Encephalitozoon cuniculi* antibodies. *Acta Vet. Scand.* 23:99–106.
 39. Mohn, S. F., K. Nordstoga, and O. M. Moller. 1982. Experimental encephalitozoonosis in the blue fox. Transplacental transmission of the parasite. *Acta Vet. Scand.* 23:211–220.
 40. Montrey, R. D., J. A. Shadduck, and S. P. Pakes. 1973. An in vitro study of three encephalitozoon isolates. *J. Infect. Dis.* 127:450–454.
 41. Niederkorn, J. Y., J. A. Shadduck, and E. Weidner. 1980. Antigenic cross-reactivity among different microsporidian spores as determined by immunofluorescence. *J. Parasitol.* 66:675–677.
 42. Niederkorn, J. Y., J. K. Brieland, and E. Mayhew. 1983. Enhanced natural killer cell activity of experimental murine encephalitozoonosis. *Infect. Immun.* 41:302–307.
 43. Pakes, S. P., J. A. Shadduck, and A. Cali. 1975. Fine structure of *Encephalitozoon cuniculi* from rabbits, mice and hamsters. *J. Protozool.* 22:481–488.
 44. Pakes, S. P., J. A. Shadduck, D. B. Feldman, and J. A. Moore. 1984. Comparison of tests for the diagnosis of spontaneous encephalitozoonosis in rabbits. *Lab. Anim. Sci.* 34:356–359.
 45. Petri, M. 1966. The occurrence of *Nosema cuniculi* (*Encephalitozoon cuniculi*) in the cells of transplantable, malignant ascites tumors and its effect upon tumor and host. *Acta Pathol. Microbiol. Scand.* 66:13–30.
 46. Pinnolis, M., P. R. Egbert, R. L. Font, and F. C. Winter. 1981. Nosematosis of the cornea. *Arch. Ophthalmol.* 99:1044–1047.
 47. Rijpstra, A. C., E. U. Canning, R. J. Van Ketel, J. K. M. Eeftinck Schattenkerk, and J. J. Laarman. 1988. Use of light microscopy to diagnose small-intestinal microsporidiosis in patients with AIDS. *J. Infect. Dis.* 157:827–831.
 48. Schmidt, E. D., and J. A. Shadduck. 1984. Mechanisms of resistance to the intracellular protozoan *Encephalitozoon cuniculi* in mice. *J. Immunol.* 133:2712–2719.
 49. Schmidt, E. C., and J. A. Shadduck. 1983. Murine encephalitozoonosis model for studying the host-parasite relationship of a chronic infection. *Infect. Immun.* 40:936–942.
 50. Shadduck, J. A. 1969. *Nosema cuniculi*: in vitro isolation. *Science* 166:516–517.
 51. Shadduck, J. A. 1980. Effect of fumagillin on in vitro multiplication of *Encephalitozoon cuniculi*. *J. Protozool.* 27:202–208.
 52. Shadduck, J. A., R. Bendele, and G. T. Robinson. 1978. Isolation of the causative organism of canine encephalitozoonosis. *Vet. Pathol.* 15:449–460.
 53. Shadduck, J. A., and S. P. Pakes. 1971. Spontaneous diseases of laboratory animals which interfere with biomedical research. Encephalitozoonosis and toxoplasmosis. *Am. J. Pathol.* 64:657–674.
 54. Shadduck, J. A., and M. B. Polley. 1978. Some factors influencing the in vitro infectivity and replication of *Encephalitozoon cuniculi*. *J. Protozool.* 25:491–496.
 55. Siebold, H. R., and E. N. Fussell. 1973. Intestinal microsporidiosis in *Callicebus moloch*. *Lab. Anim. Sci.* 23:115–118.
 56. Singh, M., G. J. Kane, L. Mackinlay, I. Quaki, Y. E. Hian, H. B. Chuan, H. L. Chuen, and L. K. Chew. 1982. Detection of antibodies to *Nosema cuniculi* (Protozoa: *Microsporidia*) in human and animal sera by the indirect fluorescent antibody technique. *Southeast Asian J. Trop. Med. Public Health* 13:110–113.
 57. Sprague, V. 1974. *Nosema connori* n. sp., a microsporidian parasite in man. *Trans. Am. Microscop. Soc.* 93:2400–2403.
 58. Sprague, V. 1977. Systematics of the microsporidia, p. 1–29. In L. A. Bulla and T. C. Cheng (ed.), *Comparative pathobiology*, vol. 2. Plenum Publishing Corp., New York.
 59. Terada, S., R. Reddy, L. J. Jeffers, A. Cali, and E. R. Schiff. 1987. Microsporidian hepatitis in the acquired immunodeficiency syndrome. *Ann. Intern. Med.* 107:61–62.
 60. Torres, C. M. 1927. Morphology of a new parasite of man. *Encephalitozoon chagasi* n. sp. observed in a case of congenital meningomyeloencephalitis with myositis and myocarditis (French). *C. R. Soc. Biol.* 97:1787–1790.
 61. Twort, J. M., and C. C. Twort. 1932. Disease in relation to carcinogenic agent amongst 60,000 experimental mice. *J. Pathol. Bacteriol.* 35:219–242.
 62. Undeen, A. H. 1975. Growth of *Nosema algerae* in pig kidney cell cultures. *J. Protozool.* 22:107–110.
 63. Undeen, A. H., and N. E. Alger. 1976. Infection of the white mouse by a mosquito parasite. *Exp. Parasitol.* 40:86–88.
 64. Viting, A. I. 1969. The parasitic nature of diffuse or multiple sclerosis. *Parasitology* 3:569–577. (In Russian.)
 65. Vossbrinck, C. R., J. V. Maddox, S. Friedman, B. A. Debrunner-Vossbrinck, and C. R. Woese. 1987. Ribosomal RNA sequence suggests microsporidia are extremely ancient eukaryotes. *Nature (London)* 326:411–414.
 66. Vossbrinck, C. R., and C. R. Woese. 1986. Eukaryotic ribosomes that lack a 5.8S RNA. *Nature (London)* 320:287–288.
 67. Waller, T. 1979. Sensitivity of *Encephalitozoon cuniculi* to various temperatures, disinfectants and drugs. *Lab. Anim.* 13:227–230.
 68. Waller, T., A. Lyngset, M. Elvander, and B. Morein. 1980. Immunological diagnosis of encephalitozoonosis from postmortem specimens. *Vet. Immunol. Immunopathol.* 1:353–360.
 69. Weisbroth, S. H., R. E. Flatt, and A. L. Kraus. 1974. The biology of the laboratory rabbit, p. 276. Academic Press, Inc., New York.
 70. World Health Organization Parasitic Diseases Surveillance. 1983. Antibody to *Encephalitozoon cuniculi* in man. *W.H.O. Weekly Epidemiol. Rec.* 58:30–32.
 71. Zeman, D. H., and G. B. Baskins. 1985. Encephalitozoonosis in squirrel monkeys. *Vet. Pathol.* 22:24–31.