

ROLE OF VACCINATION IN THE CONTROL OF TURKEY COCCIDIOSIS:
VACCINE ASSOCIATED OOCYST SHEDDING, LESIONS, AND
MUCOSAL GENE EXPRESSION

A Thesis

by

MICHELLE A. BEHL

Submitted to the Office of Graduate Studies of
Texas A&M University
in partial fulfillment of the requirements for the degree of
MASTER OF SCIENCE

May 2011

Major Subject: Poultry Science

Role of Vaccination in the Control of Turkey Coccidiosis: Vaccine Associated Oocyst
Shedding, Lesions, and Mucosal Gene Expression

Copyright 2011 Michelle A. Behl

ROLE OF VACCINATION IN THE CONTROL OF TURKEY COCCIDIOSIS:
VACCINE ASSOCIATED OOCYST SHEDDING, LESIONS, AND
MUCOSAL GENE EXPRESSION

A Thesis

by

MICHELLE A. BEHL

Submitted to the Office of Graduate Studies of
Texas A&M University
in partial fulfillment of the requirements for the degree of

MASTER OF SCIENCE

Approved by:

Chair of Committee,	Morgan Farnell
Committee Members,	David Caldwell
	Haiqi He
	Radivoje Spasojevic
	Jason Lee
Head of Department,	John Carey

May 2011

Major Subject: Poultry Science

ABSTRACT

Role of Vaccination in the Control of Turkey Coccidiosis: Vaccine Associated Oocyst Shedding, Lesions, and Mucosal Gene Expression. (May 2011)

Michelle A. Behl, B.S., University of Wisconsin-Madison

Chair of Advisory Committee: Dr. Morgan Farnell

Coccidiosis vaccine associated side effects, oocyst shedding patterns, intestinal lesions, and mucosal gene expression in the turkey were studied. The first study examined vaccine associated side effects and oocyst shedding patterns under experimental conditions. Peak oocyst shedding occurred on days 5-6, 13-17, and 19-20 days post vaccination. Throughout the course of the study, several poultts exhibited clinical coccidiosis. Based on body weights, growth was correlated with vaccine cycling.

The second study examined coccidiosis vaccine induced lesions and changes in mucosal gene expression on day 5, 10, 13, 17, and 20 days post vaccination. Poults were gavaged the equivalent of 0x, 1/2x, 1x, and 2x the available vaccine dose. Intestinal sections adjacent to the Meckel's diverticulum, ileocecal junction, and middle of the ceca were collected for histological analysis and gene expression. Measurements from the tip of the villus to the base of the lamina propria, villus width, and the *muscularis mucosae* thickness were acquired from the histological sections. Interleukin-10, IL-1 β ,

and GAPDH gene expression were measured by extracting mRNA in the tissues and quantified using real-time RT-qPCR.

Starting on day five post vaccination, the control group weighed significantly more than the group that received the 2x dose. Body weight and oocyst dose were inversely related through day 17. Intestinal measurements did not necessarily correlate with the vaccine dose, although there appears to be some correlation on day five. There were no significant changes in the mucosal gene expression of IL-10 and IL-1 β in the intestinal tissue adjacent to the Meckel's diverticulum throughout the course of the study. On day five post vaccination, IL-10 and IL-1 β were significantly upregulated in the ileocecal junction. Interleukin-10 was significantly upregulated on day 17 and IL-1 β was significantly down regulated on day 20 in the ileocecal junction. Both IL-10 and IL-1 β were significantly upregulated in the ceca days 5, 10, and 13 post vaccination. Interleukin-10 was significantly upregulated in the ceca on day 17 and significantly down regulated on day 20. Individual variation among poult in the same group merits further attention.

DEDICATION

to my wonderful husband and children

-with love anything is possible

ACKNOWLEDGEMENTS

I would like to thank my committee chair, Dr. Farnell, and my committee members, Dr. Caldwell, Dr. He, Dr. Lee, and Dr. Spasojevic, for their guidance and support throughout the course of this research.

My accomplishments would not have been possible without the concerted effort of several groups and individuals. I would like to acknowledge Willmar Poultry Company d.b.a. Ag Forte for financially supporting my education and research. The Life Science Innovations – Research Group offered the use of their isolation rooms. Marilyn Edman and Donna McLouth in the Diagnostic Laboratory provided guidance and technical support in addition to their facilities for sample processing. Roger Harkess with Nova Tech Engineering offered technical support and additional resources. Dr. Kogut at USDA-ARS Southern Great Plains Research Laboratory supplied the equipment and facilities needed for the mucosal gene expression. Dr. Rami Dalloul provided cytokine primer sequences. Dr. Daniel Shaw provided histopathological results and interpretation of the intestinal slides.

Dr. Gorica and Dr. Rade Spasojevic provided guidance throughout my education both professionally and personally. Rade proofed countless pages of papers and Gorica supported me through my graduate meltdowns. Without them, this great learning experience would not have been possible. I am truly indebted to Rade for his time and wisdom that he has so generously shared with me. Finally, I would like to thank my husband, John, and children, Adriana and Abigail, for their patience, support, and love.

NOMENCLATURE

Ce	Ceca
GAPDH	Glyceraldehyde 3-Phosphate Dehydrogenase
ICJ	Ileocecal Junction
IEC	Intraepithelial Cell
IL	Interleukin
ISCOM	Immune Stimulating Complexes
MD	Meckel's Diverticulum
mRNA	Messenger RNA
OPG	Oocyst per Gram
qRT-PCR	Quantitative Real Time Polymerase Chain Reaction

TABLE OF CONTENTS

	Page
ABSTRACT	iii
DEDICATION	v
ACKNOWLEDGEMENTS	vi
NOMENCLATURE	vii
TABLE OF CONTENTS	viii
LIST OF FIGURES	x
LIST OF TABLES	xii
CHAPTER	
I INTRODUCTION	1
Rationale and Significance	2
II LITERATURE REVIEW	4
Coccidia	4
Avian Immune Response	6
Gene Expression	9
Anticoccidial Drugs	11
Vaccines	14
Alternative Treatments	20
Conclusion	22
III COCCIDIOSIS VACCINE INDUCED OOCYST SHEDDING PATTERNS	24
Overview	24
Introduction	25
Materials and Methods	27
Results and Discussion	30

CHAPTER	Page
IV	COCCIDIOSIS VACCINE INDUCED LESIONS AND MUCOSAL GENE EXPRESSION OF IL-10 & IL-1 β 38
	Overview 38
	Introduction 39
	Materials and Methods 45
	Results and Discussion 50
VI	CONCLUSIONS 67
	REFERENCES 70
	VITA 77

LIST OF FIGURES

FIGURE		Page
1	Mean daily OPG fecal by pen	32
2	Combined mean daily OPG fecal	33
3	Mean daily OPG litter by pen	35
4	Combined mean daily OPG litter	36
5	Average weekly body weight by pen	37
6	Ceca distended, filled with fibrino-necrotic material	51
7	Cecal cores visible through the intestinal wall	51
8	Cecal cores - fibrino-necrotic material present in the lumen	52
9	Fibrino-necrotic material in the lumen and mucosal damage in the form of focal ulcerations and hemorrhaging	52
10	Lumen of the ceca filled with fibrino-necrotic material and coccidia	53
11	Epithelial cells in the ceca contain coccidia at numerous stages of development	54
12	Coccidia at numerous stages of development	54
13	Atrophy of the villus	55
14	Control villus	55
15	Body weight at the time of tissue collection	56
16	Intestinal measurements taken from the Meckel's diverticulum	57
17	Intestinal measurements taken from the ileocecal junction	59

FIGURE	Page
18 Intestinal measurements taken from the ceca.....	60
19 Fold change in mRNA gene expression in the Meckel's diverticulum.....	62
20 Fold change in mRNA gene expression in the illeocecal junction.....	63
21 Fold change in mRNA gene expression in the ceca	64

LIST OF TABLES

TABLE		Page
1	Real-time RT-qPCR primer and probes sequences of the targeted genes..	49

CHAPTER I

INTRODUCTION

Avian coccidiosis is caused by infections with the intestinal protozoa of the phylum Apicomplexa and genus *Eimeria*. The disease most notably characterized by diarrhea and enteritis, is a universal problem in the poultry industry. When considering treatment costs and lost performance, the disease costs the industry an estimated \$3 billion dollars each year worldwide, making it the most expensive disease affecting the poultry industry today (Dalloul and Lillehoj, 2006). Traditionally, the poultry industry has relied heavily on the use of anticoccidial medications to prevent or treat the disease (Williams, 2002). Unfortunately, *Eimeria* easily develop resistance to chemicals and antibiotics making them less effective for long-term treatment (Li et al., 2004). A recent field study conducted by Chapman and Rathinam (2007) revealed the majority of turkey strains of *Eimeria* are either partially or fully resistant to the commonly used ionophore, monensin. The growing demand for naturally raised poultry products and increasing chemical resistance has fueled the need to find alternative methods to prophylactic treatments for the control of coccidiosis. Consequently, intensive rearing systems favor the *Eimeria* life cycle (Long, 1984) therefore the threat of coccidiosis is unlikely to disappear. When compared to chemical coccidiostats, coccidial vaccines are relatively new for turkeys. The first chemical treatment appeared approximately 70 years ago

This thesis follows the style of Poultry Science.

while the first coccidial turkey vaccine, Coccivac-T®, appeared only 21 years ago. Comparatively, the first chicken vaccine was formulated nearly 60 years ago (Williams, 2002). Although vaccines appear to be a viable alternative to prophylactic treatment, side effects such as post-vaccinal setbacks in weight gain have limited their acceptance (Danforth, 1998).

Rationale and Significance

Due to limited peer reviewed data concerning turkey coccidiosis vaccination, Willmar Poultry Farms (WPF) (Willmar, MN) conducted a series of trials to determine the efficacy of Coccivac-T® in their commercial system. For a three month period, Coccivac-T® vaccination replaced the traditionally used ionophore, monensin on all poult placements in the WPF commercial system. The vaccine was administered at the hatchery using a Spraycox® II cabinet (Intervet/Schering-Plough Animal Health) or a proprietary experimental gel drip bar with supplemental lighting (Danisco®, Madison, WI). Vaccine uptake was measured by assessing residual vaccine dye on the inside of the beak 15 minutes post vaccination. Although the gel drip bar averaged 85% uptake versus the spray at 75%, both application methods resulted in highly variable vaccine uptake (unpublished). Factors such as hatch timing, hydration of the poult, and inherent pecking order probably played a role in vaccine uptake. Later hatching or extremely hydrated poult consumed less than the earlier hatching, less hydrated poult. Inconsistent consumption also occurred with poult that were comparable in hatch

timing and hydration level (unpublished). Naturally, aggressive poult consumed more droplets than docile ones.

In the field, clinical coccidiosis was diagnosed to some extent in most flocks vaccinated with Coccivac-T®. Poults developed enteritis at approximately 10 days of age and exhibited ruffled feathers, general morbidity, and a decrease in flock uniformity. Examination of the intestinal scrapings from the mortalities and fecal droppings in the barn revealed excessive amounts of oocysts. Oocyst levels in scrapings that were too numerous to count could be seen as early as day seven. In an attempt to control the clinical coccidiosis, flocks were treated with amprolium during brooding to reduce oocyst levels (unpublished data).

Coccidiosis and coccidiosis vaccination have been studied in the chicken but to a lesser extent in the turkey. The nature of the disease is somewhat different between the two hosts (Saif, 2003); therefore, information collected in the chicken may not be fully applicable to the turkey. Clinical signs are not easily detected in the turkey because lesions heal quickly, making coccidiosis difficult to diagnose (Saif, 2003). A better understanding of the disease in the turkey may provide an insight to control it.

CHAPTER II

LITERATURE REVIEW

Coccidia

Coccidia are single-cell, obligate intracellular parasites, of the genus *Eimeria*, which invade the epithelial lining of the gastrointestinal tract. Multiplication of the parasite in the epithelium results in tissue damage, nutrient malabsorption, blood loss, and infections with opportunistic pathogens such as *Clostridium perfringens* (Collier et al, 2008). Species of *Eimeria* are host specific, unique to the area of the gastrointestinal tract that it invades, and lesions it produces. Cross immunity between species of *Eimeria* does not exist (Saif, 2003; Charlton, 2006).

The life cycle of coccidia is very complex and consists of both asexual and sexual reproductive stages. The life cycle also includes a sporogony phase in which a thick wall protects the parasite making it very resistant to drying and many chemical substances, enabling it to survive for extended periods in the environment (Saif, 2003). Coccidiosis is initiated upon the ingestion of a sporulated oocyst. Once in the gastrointestinal tract, enzymatic secretions coupled with the mechanical action of the ventriculus cause the oocyst to rupture and release eight sporozoites from four sporocytes enclosed in the oocyst (Conway et al. 1991). The sporozoites invade the epithelial cells of the villi and migrate to the epithelium in the crypt for asexual proliferation (Yun et al., 2000). Upon invasion, the sporozoite transforms into the feeding stage of its life and becomes a trophozoite. The trophozoite feeds upon the

epithelial cells and continues to grow larger until it is large enough to undergo division by asexual reproduction and develop into a schizont. When the schizont ruptures, it releases thousands of merozoites that invade other cells. This cycle repeats several times, depending on the species of *Eimeria* involved, before male and female gametes known as microgametes and macrogametes form. Once the microgamete fertilizes the macrogamete, a thick wall develops around the zygote and gives rise to an immature oocyst. When the enterocyte cell wall ruptures, the immature oocyst is passed in the feces. Ingestion of a single oocyst can result in the shedding of up to one million oocysts and result in extensive tissue damage (Conway et al., 1991). The oocyst must mature in the environment in order to become infectious. Oxygen, heat, and moisture are required for sporulation. Up to 20% of ingested unsporulated vaccine oocysts can pass through the gastrointestinal tract undamaged and later sporulate and become infectious (Williams, 1998).

Seven species of *Eimeria* are known to infect the turkey. Only four of them are considered pathogenic: *Eimeria meleagriditis*, *Eimeria dispersa*, *Eimeria gallapovonis*, and *Eimeria adenoeides*. *Eimeria meleagriditis* tends to parasitize the middle one-third of the small intestine. *Eimeria dispersa* is found across the small intestine and ileocecal junction. *Eimeria gallapovonis* affect the lower portion of the ileum, ileocecal junction, and large intestine. *Eimeria adenoeides* may cause occasional lesions across the lower one-third of the intestine but primarily affects the ceca. Non-pathogenic species of *Eimeria* may be found in the gastrointestinal tract. Therefore, diagnosis of coccidiosis needs to be based on clinical signs and pathological lesions rather than solely on the

presence of coccidia in the gut alone (Saif, 2003; Charlton, 2006). Coccidiasis is described as a subclinical coccidial infection. Coccidiosis is a symptomatic infection, which results in clinical signs (Charlton, 2006).

Avian Immune Response

The avian immune system differs to some extent from the mammalian immune system in structure and functionality (Bar Shira et al., 2003). Chickens appear to lack some of the T_{H2} components of the immune response found in mammals such as the immunoglobulin (Ig) E that helps combat the extracellular stages of *Eimeria*. In addition, chickens have fewer mast cells that are notably involved with IgE pathogen defenses against protozoan parasites in mammals (Kaiser et al., 2004). Understanding the protective immunological response of the avian intestine may help to discover new ways to controlling infections with *Eimeria* (Lillehoj 1998; Hilton et al., 2002). The intestine is the largest immunological organ in the bird and its response to challenges with *Eimeria* is multifaceted (Lillehoj 1998). The immune mechanisms involved are dependent upon the area of the gastrointestinal tract being parasitized, the *Eimeria* species involved, and the developmental stage of the coccidial parasite (Lillehoj, 1998; Talabia and Mulcahy, 2005). The early asexual stages of the *Eimeria* life cycle are more immunogenic than the later sexual stages (Yun et al., 2000). The propagation of the pathogen and the immune response is not always predictable. Gross lesion scores do not necessarily increase linearly with the number of oocysts ingested (Conway et al., 1999). The immune response to *Eimeria* may not always be beneficial to the host either. The

host's inflammatory defense response to coccidia increases mucogenesis in the gastrointestinal tract. *Clostridium perfringens* is able to utilize mucus as a substrate in the gut therefore making the gastrointestinal tract a more favorable environment for the growth of *Clostridium perfringens*. The increase in *Clostridia* colonies in the gut contributes to the onset of necrotic enteritis in chickens (Collier et al., 2008).

Immune Response to Eimeria

When *Eimeria* invades the gastrointestinal tract, intraepithelial cells (IEC's), primary immune effector cells, located throughout the gastrointestinal tract, are responsible for eliciting a protective immunity to coccidiosis (Kim et al., 2008). Intraepithelial leukocytes are comprised of several cell types that regulate the mucosal immune response through the secretion of cytokines (Yun et al., 2000). Numerous cytokines are immediately produced locally to provide the early signs of invasion and enhance the immune response (Dalloul and Lillehoj, 2005). These cytokines activate lymphocytes and stimulate the secretion of IgA that is the gastrointestinal tract's first line of defense (Lowenthal et al., 2000). Secretory IgA can attach to the coccidial surface and prevent the binding of the pathogen to the epithelial surface by directly blocking attachment, through steric hindrance, or by decreasing the motility of the sporozoites. Cytokines promote antigen processing of immune cells such as the B and T cells. A complex interaction occurs between the regulation of cytokines and host's immune response to *Eimeria*. Intracellular stages of the *Eimeria* life cycle activate cell-mediated immunity while the extracellular stages activate humoral responses (Yun et al.,

2000). Cell-mediated immunity appears to play a much larger role than the humoral antibody response when considering *Eimeria* resistance (Lillehoj, 1998; Talabia and Mulcahy, 2005). The Natural killer cells play an important role in the early local defense while T cells play a much larger role in the development of natural resistance to *Eimeria* (Vermeulen, 1998). Cytokines, interleukin (IL)-1 β (Kaiser et al., 2004), IL-2, IL-5, IL-10, (Yun et al., 2000), and IFN- γ (Lillehoj, 1998) are significantly up regulated in regions across the gastrointestinal tract following challenges with *Eimeria*. A cDNA microarray of over four-hundred genes in the intestinal intraepithelial lymphocytes during primary and secondary *Eimeria maxima* infections in leghorn chickens revealed significant changes in IL-1 β , IL-2, IL-6, IL-8, IL-15, and IL-18 (Kim et al., 2008).

Interleukin-10

Interleukin-10, secreted by activated macrophages and T-regulatory cells, is one of the most important immunoregulatory cytokines. It helps to maintain balance of the innate and cell mediated immune responses by inhibiting activated macrophages (Abbass et. al, 2007) and inflammation (Kaiser et al., 2004). During peak parasitic infections in chickens, IL-10 expression is elevated. The increase in IL-10 may be an attempt of the parasite to evade macrophage-mediated destruction by suppressing the host's inflammatory response (Collier et al., 2008).

Interleukin -1 β

Interleukin-1 β , a pro-inflammatory cytokine produced by macrophages, endothelial cells, and epithelial cells, mediates the inflammatory response of the host. The level of response or inflammation depends on the amount of IL-1 β produced. Small quantities result in local inflammation. Large concentrations of IL-1 β enter the blood stream, stimulate the synthesis of acute phase plasma proteins as part of the early innate immune response, and stimulate the production of IL-6, which promotes the growth of B-lymphocytes (Abbass et al., 2007) in addition to increasing chemokine and corticosterone production (Hilton et al., 2002). Although IL-1 β appears to have a similar function in birds as it does in mammals, the location of genetic loci on the chromosome is not similar to the mammalian analogue (Abbass et al., 2007). Quantitative real time polymerase chain reaction (qRT-PCR) analysis has shown an 80-fold increase in IL-1 β gene expression seven days after a challenge with *Eimeria tenella* in the chicken. Similarly, challenges with *Eimeria maxima* tend to up regulate IL-1 β gene expression but to a much lesser extent (Kaiser et al., 2004).

Gene Expression

Gene expression profiling of immune related components, such as cytokines and Toll-like receptors, throughout the course of infections may provide insight to controlling particular diseases (Abasht et al., 2008). The characterization of mucosal immune related genes in the chicken is to some extent focused on responses to infections with *Salmonella*, although limited data concerning coccidial infections in the chicken is

available. Mucosal gene profiling in the turkey is absent in the peer reviewed literature. Gene expression can be measured by extracting the mRNA in the biological sample, amplified with probes and primers, and quantified using qRT-PCR (Roth, 2002). Reference endogenous genes, such as glyceraldehyde 3-phosphate dehydrogenase (GAPDH) are used as standards for changes in gene expression (Zhou et al., 2010). Fold changes in mRNA gene expression can be calculated using the described $2^{-\Delta\Delta CT}$ method for gene expression data acquired using qRT-PCR (Livak and Schmittgen 2001).

Based previous research of the Toll-like receptor mRNA expression in the duodenum and cecal tonsils, native breeds of chickens in India are immunologically more competent and disease resistant than the commercial equivalent (Dhinakar Raj et al., 2009). The selection for increased performance, such as growth, has resulted in adverse effects on the immune response (van Hemert et al., 2006; Dhinakar Raj et al., 2009). Similarly, distinct differences in immune responses are seen between fast and slow growing lines of broilers in the jejunum when they are challenged with *Salmonella* (van Hemert et al., 2006). The faster growing line responded to the challenge with an increase in genes that enhance T cell activation while the slower growing strain responded differently and more efficiently. The slower strain had an increase in macrophage activation. The different immune responses exhibited between the fast and slow growing broiler lines to the same pathogen may potentially explain the variations in susceptibility to *Salmonella* (van Hemert et al., 2006). The continuous investigation of gene expression in the chicken, regardless of the pathogen, provides a fundamental foundation to the study of gene expression and immune response in the turkey.

Anticoccidial Drugs

The first anti-coccidial chemotherapeutic drugs appeared on the market in 1939 (Long, 1984). Initially sulphonamide, sulphanilamide, and sulphodium iodine were used to treat the disease and sulphaquinoxaline and nitrophenide were used in the prevention of the disease. Sulpha-based chemicals inhibit meront development and the sexual stages of development. The heavy use of sulpha-based chemicals led to widespread *Eimeria* resistance. Nitrobenziamides were heavily used in the 1960's and 1970's until species of *Eimeria* acquired resistance to the chemicals and were no longer effective. Amprolium has been used since the 1960's and reports of *Eimeria* resistance exists (Long, 1984). Monensin, an ionophorous antibiotic, is one of the most widely used anticoccidial drug in turkeys operations, approximately in 70% of all meat-type turkeys (Chapman and Rathinam, 2007). The majority of field isolates are now fully or partially resistant to monensin (Chapman and Rathinam, 2007). Ionophores disrupt the normal ionic gradients of the coccidia by creating hydrophilic channels or by transporting ions across the lipid bi-layer. The gradient change results in mitochondrial damage and subsequently a lack of cellular energy. The lack of energy inhibits the transport of sodium and potassium ions across the surface membrane, which is critical for normal cellular function. Due to the nature of the chemical, ionophores easily accumulate in the host's tissue, which leads to a very narrow margin of safety (Long, 1984; Kart and Bilgili, 2008). Ionophore toxicity reports of ataxia, reduced performance, paralysis, and death occur frequently in turkeys because of cardiac muscle damage and myelin

degeneration of the nervous system induced by the ionophore (Mathis, 1993 and Kart and Bilgili, 2008).

The use of anticoccidials may interfere with the development of immunity and delay coccidial protection (Karlson and Ried, 1978; Yadav and Gupta, 2007), although the overall effect on immunity is disputed (Hu et al., 2000). The second-generation schizont is needed to induce a proper immune response but the majority of ionophores tend to stop the coccidial life cycle at the first generation schizont (Yadav and Gupta, 2007). Since various types of chemicals act on different stages of the *Eimeria* life cycle, immunity is linked to the type of anticoccidial used (Mathis, 1993). Halofuginone significantly suppresses the amount of shedding and recycling of oocysts and when removed from the diet between eight to ten weeks of age coccidiosis breaks may occur (Mathis, 1993). Yadav and Gupta (2007) indicated that different isolates of the same strain affected the immune development differently. The type of litter used also has an effect on immune development. Unmedicated chicks raised on used litter acquire immunity by five weeks of age, due to natural exposure from oocysts shed in the previous flock, compared to the typical seven weeks when chicks are raised on new litter. Medicated chicks acquire immunity by seven week regardless of the type of litter used (Chapman, 1999). A single large peak of oocysts occurs in the litter of chicken flocks between four and eight weeks of age when fed a preventative dose of ionophores in the diet (Williams, 1998).

Advantages/Disadvantages

Performance in medicated flocks is consistently equal to or better than those that are vaccinated (Danforth, 1998). Medicated flocks tend to have significantly higher body weights and better feed conversion rates than vaccinated flocks (Li et al., 2005; Rojs et al., 2007). In addition to being an anticoccidial, ionophorous antibiotics have additional benefits unrelated to *Eimeria*. Salinomycin has a positive effect on the microflora in the gastrointestinal tract in broilers. It decreases the amount of *Clostridia perfringens* in the gastrointestinal tract and reduces the risk and incidence of necrotic enteritis in broilers (Johansen et al., 2007). Since ionophores are antimicrobial compounds, they reduce the overall bacterial load in the gut and increase feed efficiency, consequently they are classified as growth promoters. Medicated birds also have higher body weights than non-medicated unchallenged controls (Johansen et al., 2007).

Although there are benefits to using prophylactic treatments, there are several reasons for discontinuing their use. Foremost, *Eimeria* species easily develop resistance to chemicals and ionophorus antibiotics (Li et al., 2004). In recent field study conducted by Chapman and Rathinam (2007), the majority of field isolates of *Eimeria* in commercial turkey operations were either partially or fully resistant to monensin. The growing demand for naturally raised poultry products and increasing chemical resistance has fueled the need to find alternative methods to prophylactic treatments for the control of coccidiosis.

Vaccines

Traditional Vaccines

Coccidiosis vaccines are nearly 60 years in the making. Professor Samuel Allen Edgar of Auburn University, Auburn, Alabama successfully formulated the first anticoccidial vaccine in 1952 for chickens (Williams, 2002). The vaccine consisted of a single live virulent strain of *Eimeria tenella* and was marketed under as what is known today as Coccivac®. Dr. Eng-Hong Lee created and marketed the next live non-attenuated vaccine for chickens known as Immucox® (Vetech Laboratories Inc., Guelph, Ontario) in Canada in 1985 (Williams, 2002). Paracox®, a combination of live attenuated strains, was developed in 1989 in the Netherlands as part of the Glaxo Animal Health Ltd® (Williams, 2002). Attenuated strains are selected based on the precocious trait that is very stable and heritable. Precocious strains have a decreased reproductive potential yet have the ability to stimulate immunity while causing minimal damage to the gastrointestinal tract. Precocious strains can interbreed with corresponding wild species and reduce the virulence of the wild strain (Williams, 1998). Dr. Peter Bedrnik of the Czech Republic formulated Livacox® (Virbac Animal Health, Republic of South Africa), the first vaccine that contained embryo adapted attenuated species of *Eimeria*, in 1992 (Williams, 2002). It was not until 1989 that the first coccidial turkey vaccine, Coccivac-T®, became available. All live vaccines commercially available today were derived from of Coccivac®, Paracox®, or Livacox® formulations (Williams, 2002). Nearly 60 years later coccidial vaccines appear to remain effective, decreased efficacy of the vaccines has not been reported. The use of

vaccines has restored the sensitivity of *Eimeria* to in feed coccidiostats and has replaced virulent field strains in the environment by competitive exclusion (Williams, 1998).

Coccidial vaccines are administered to poultts during the first week of life via a gel drip (Immucox®) or water based spray (Coccivac-T®). Coccivac-T® administered to day old turkey poultts via ocular vaccination provides similar protection as oral ingestion of the oocyst (Chapman, 1996). Proper administration of the vaccine is critical for its effectiveness (Williams, 1998), uniform vaccination results in even immune development in the flock. Gel applications tend to keep the oocysts suspended more evenly in solution than water based sprays that require the assistance of an aerator and based on lesion scores, result in a more uniform vaccination based on lesion scores (Dasgupta and Lee, 2000). To acquire immunity to species of *Eimeria* in the chick, the vaccine must result in a low-level coccidial infection with several cycles of oocyst shedding and re-infection (Li et al., 2004). Coccidial cycling can be determined by enumerating the oocysts shed in the fecal droppings and the litter. Fecal samples reflect the intensity of the coccidial infection at that specific time while litter samples tend to evaluate the accumulation of oocysts in the litter and even out small-scale peaks seen in fecal samples (Williams, 1998). Approximately one week following the vaccination of the chicken with Paracox®, oocysts start to appear in the litter. Between the second and fourth week, a small peak in oocyst shedding is seen (Williams, 1998). Between the fourth and seventh week post vaccination a slightly higher peak is normally seen. The second higher peak is most likely due to a field challenge (Williams, 1998). Oocyst recycling and shedding tends to decrease as host immunity increases. Approximately

seven to eight weeks post vaccination very few oocysts are detected in the litter. All vaccinated chicken flocks exhibit similar oocyst shedding patterns (Williams, 1998).

An added coccidiosis vaccination practice in the commercial egg laying industry demonstrates the importance of the recycling and re-exposure of oocysts to acquire full immunity (Soares et al., 2004). Hens raised in wire cages had limited exposure to their feces or shed oocysts. Prior to the placement of paper plates in the cages for a period of two weeks following vaccination, to promote the recycling of oocysts, vaccinated laying hens were not able to acquire immunity to *Eimeria* and coccidiosis breaks were common. After adopting the paper plate method, hens developed immunity much quicker and exhibited overall increases in egg production (Soares et al., 2004).

Non-traditional Vaccines

In ovo vaccination is a fairly new technique that is being attempted as an alternative administration method. Under experimental conditions, broiler chicks vaccinated with sporozoites, sporocysts, or oocysts via *in ovo* injection in the air cell on the eighteenth day of incubation shed oocysts in their feces post hatch (Weber and Evans, 2003). *In ovo* vaccinated chicks had lower lesion scores compared to the controls and exhibited coccidial protection when experimentally challenged at three weeks of age (Weber and Evans, 2003). Inovocox® (Pfizer Animal Health, Durham, NC), the only commercially *in ovo* anticoccidial vaccine available, is comprised of chicken species of sporulated oocysts (Dalloul and Lillehoj, 2005). Future *in ovo* vaccines may consist of sporocytes that are injected directly into the yolk (Vermeulen et al., 2001).

Sub-unit vaccines are antigen based and not capable of replicating in the host making the risk of adverse reactions relatively low (Abbass et al., 2007). *Eimeria tenella* sporozoite antigens incorporated into immune stimulating complexes (ISCOM), a vaccine adjuvant, and administered intranasally induced protection under experimental conditions. Vaccinated chicks challenged with *Eimeria tenella* had lower lesion scores, a lesser amount of tissue damage, and a smaller amount oocyst shedding when compared to unvaccinated controls (Garcia et al., 2008). CoxAbic® (ABIC Biological Laboratories Teva Ltd., Israel), recently developed in Israel to control chicken coccidiosis, is the only sub-unit anticoccidial vaccine commercially available. It is a transmission blocking vaccine that consists of affinity-purified gametocyte antigens which inhibit the development of macrogametes into oocysts. Vaccinated hens pass maternal antibodies to *Eimeria* to the offspring. CoxAbic® has been tested on over 60 million broiler offspring throughout Asia, Africa, Eastern Europe, and Latin America, and is effective in controlling coccidiosis (Sharman et al., 2010).

Recombinant vaccines, a type of sub-unit vaccine, may be less expensive to manufacture and have a longer shelf life than the traditional live vaccines (McDonald and Shirley, 2009). Sub-unit vaccines may be dosed by injection and therefore result in a more consistent exposure. Since recombinant vaccines do not require recycling of oocysts to gain immunity, adverse side effects of traditional live vaccines could be avoided (Vermeulen et. al, 2001; Williams, 2002; Talebi and Mulcahy, 2005; McDonald and Shirley, 2009). *Salmonella typhimurium* and herpes virus of the turkey (HVT) are potential vaccine vectors for *Eimeria* antigens derived from invasion proteins on the

sporozoites or from the asexual and sexual stages of the life cycle (Vermeulen, 1998). Antigen based vaccines elicit a humoral antibody response but do not elicit the local IgA mediated immune response in the mucosa of the gastrointestinal tract. Therefore, local mucosal immunity is not acquired when birds are vaccinated with antigen-based vaccines (Long, 1984).

In addition to sub-unit vaccines, synthetic peptides containing T and B cell epitopes have been shown to elicit a significant humoral response and induce the proliferation of lymphocytes. Cross-protection between species of *Eimeria* may be possible with synthetic peptide vaccines (Talebi and Mulcahy, 2005). Short oligodeoxynucleotides containing unmethylated cytosine-phosphate-guanine (CpG) motifs also stimulate innate and adaptive immune responses by enhancing antigen-presenting cells and supporting Th₁ responses. *In ovo* vaccination of CpG in white leghorn chickens improved weight gain and reduced oocyst shedding when birds were challenged with *Eimeria tenella* (Dalloul et al., 2005). Similarly, injections with the chicken cytokine IFN- γ reduced oocyst production and the negative effects coccidiosis had on growth performance (Lowenthal et al., 2000).

Problems with Vaccination

As promising as coccidiosis vaccines seem, they are not widely accepted for a number of reasons. Consistent uniform vaccination is difficult to obtain since the majority of traditional vaccines are administered orally (Dasgupta and Lee, 2000). Pecking order as well as hatch timing can affect vaccine uptake (unpublished). Uniform

distribution of vaccine oocysts is critical for the uniform development of immunity in a flock. Uneven oocyst distribution may lead to uneven recycling of oocysts. Unprotected birds may ingest a high or lethal dose of oocysts when they are shed in the droppings of vaccinated birds and result in uneven flock uniformity (Dasgupta and Lee, 2000). Higher doses of oocysts are associated with decreased growth (Hu et al., 2000). Therefore, birds that are over exposed during vaccination may also exhibit adverse results. Stressors or immunosuppressive diseases may interfere with the necessary vaccine induced immune response and inhibit immunity to *Eimeria* (Williams, 1998).

There have been several contradictory reports regarding bird performance after vaccination. Body weight and feed conversion rates in vaccinated chicks are not always equivalent to birds treated with prophylactic medications (Danforth, 1998). Although mortality appears to be similar (Rojs et al., 2007), several reports indicate that both vaccinated chicks and poults exhibit a post vaccinal set back in weight gain (Chapman, 1996; Danforth, 1998; Williams, 1998). Some researchers suggest that the set back in weight gain cannot be compensated for (Williams, 1998), while other reports suggest that vaccinated birds exhibit compensatory growth and comparable in weight to unvaccinated and unmediated controls at the time of market (Danforth, 1998; Li et al., 2005). Poults vaccinated via ocular administration exhibited suppression in weight gain. At three weeks of age, vaccinated poults had significantly lower body weights than the unchallenged controls. At six weeks of age, there were no significant differences in body weight (Chapman, 1996). Production costs in vaccinated and medicated birds appear to be similar (Lee et al., 2009).

Vaccines used in conjunction with other programs may provide additional benefits. Live attenuated multi-valent monensin tolerant vaccines used in conjunction with monensin showed beneficial results. This combination helps protect young birds from virulent field strains of *Eimeria* when immunity has not developed during the first three to four weeks, to decrease the spread of virulent field strains, and increase weight gain (Li et al., 2004 and Li et al., 2005).

Alternative Treatments

Consumer demands for organically grown poultry and concerns regarding bacterial resistance have led to the exploration of natural treatments to the prophylactic use of chemicals. Essential oils, classified as residue free, secondary plant metabolites are currently the subject of several investigations. Certain essential oils exhibit antimicrobial, antioxidant, and antiparasitic properties (Brenes and Roura, 2010). They also have a positive impact on the microbial communities in the gastrointestinal tract that is important for the development of immunity to pathogens (Oviedo-Rondon et al., 2006). Several factors can affect microbial communities such as feed quality, feed additives, or even the use of coccidiosis vaccines. Coccidial challenges drastically shift microbial communities in the gastrointestinal tract. The use of essential oil blends helps avoid the drastic shift in microbial communities typically seen with coccidial challenges (Hume, 2006; Oviedo-Rondon et al., 2006).

Oregano supplements in the diet have some anticoccidial effects in the chicken but are much lower when compared to the ionophore lasalocid (Giannenas et al., 2003).

Similar results were seen with Apacox® (GreenVet® Veterinary Phytotherapy, Italy); a commercial blend of herbal extracts (Christaki et al., 2004). When Orego-Stim® (Meridian Animal Health Ltd., Bedfordshire, UK), a commercially available oregano based product, was used in conjunction with the coccidiosis vaccine, Paracox® in the chicken, increased body weight and decreased feed conversion rates were seen (Waldenstedt, 2003). Direct-fed microbials also affect microbial communities. Direct-fed microbials act as immunomodulating agents and increase the protective immune responses of both the innate and acquired immune systems. Immunity to *Eimeria* is increased with direct-fed microbials due to the elevation in cell-mediated immunity. Chicks fed direct-fed microbials exhibited fewer clinical signs, reduced lesion scores, and increased in body weight when challenged with species of *Eimeria* (Lee et al., 2010).

The crude extract of the guava leaf acts as a coccidiostat. Body weight, feed conversion rate, mortality, and carcass quality of broilers fed diets containing guava leaf extract at levels as low as 0.04% are comparable to broilers vaccinated with CocciVac B®, LivaCox D®, or fed the coccidiostat Avatec® (Alpharma®, Mississauga, Ontario) (Rattanaphol, 2009). *Yucca schidigera* extract, the Mojave yucca, also acts as a coccidiostat. The natural saponin affects the cholesterol on cell membranes of the protozoa and inhibits the development of coccidia. The Mojave yucca has a synergistic relationship with anticoccidial vaccines. Vaccinated birds fed diets containing yucca extract have longer duodenal villi and better feed conversion rates when compared to the controls, birds solely vaccinated, solely fed a coccidiostat, or fed the coccidiostat and the

extract (Alfaro et al., 2007). Diets containing flaxseed or high levels of n-3 fatty acids offered some protection against particular strains of *Eimeria* in the chicken via reduction of oxidative stress. *Eimeria tenella*, characteristically reproduced in the anaerobic environment of the ceca, may be susceptible to oxidative stress. Diets containing high levels of n-3 fatty acids suppressed the development of *Eimeria tenella* in the ceca but had no obvious beneficial effect on the development of *Eimeria maxima* in the mid intestine (Allen et al., 1997).

Conclusion

Coccidiosis is the most expensive disease in the poultry industry (Dalloul and Lillehoj, 2006). Intensive rearing systems favor species of *Eimeria* (Long, 1984) and the oocyst stage of the life cycle make it very resistant to drying and chemicals, allowing it to survive in the environment for extended periods of time (Saif, 2003). Typically, the use of anticoccidial medications have been favored over the use of coccidiosis vaccines to control the disease due to differences in performance related to post-vaccinal reductions in weight gain (Chapman, 1996; Danforth, 1998; Williams, 1998). The majority of field turkey isolates of *Eimeria* are fully or partially resistant to the commonly used ionophore monensin due to overuse (Chapman and Rathinam, 2007). Increased chemical resistance and demand for naturally raised poultry products are forcing the decrease in use of anticoccidials. The role vaccination in the control of chicken coccidiosis has been studied but its role in turkeys is not yet described in the literature. In addition to the need for further anticoccidial vaccine research in the turkey,

there is an increased need for the understanding of the turkey's immune response. The study of immune related mucosal gene expression in the gut may provide information to the host's response and give a better insight to controlling the disease as well as others (Abasht et al., 2008).

CHAPTER III

COCCIDIOSIS VACCINE INDUCED OOCYST SHEDDING PATTERNS

Overview

Vaccine induced oocyst shedding patterns in turkey poults vaccinated on day of hatch with Coccivac-T® (Intervet/Schering-Plough Animal Health, Summit, NJ) was investigated. One hundred Hybrid® (Ontario, Canada) turkey hens were gavaged with a single dose of vaccine, 0.28 mL, randomized into four identical groups, and raised on wood shavings under experimental conditions for 30 days. Three fecal and three litter samples were obtained from each group, on a daily basis, analyzed, and compared. Body weights from five random poults in each group were taken on a weekly basis.

The fecal sampling provided more accurate and sensitive information when compared to the litter sampling. The litter samples were highly variable depending upon the location of the pen sampled. Based on fecal samples, peaks in vaccine oocyst shedding occurred on 5-6, 13- 17, and 19-20 days post vaccination. Gross lesions and clinical signs such as huddling, lethargic birds, and bloody droppings coincided with peak oocyst shedding days. Vaccine shedding trends and body weights were similar amongst all four groups. Weekly body weights and rate of gain correlated with vaccine cycling observed in fecal samples.

Introduction

Avian coccidiosis, caused by infections with species of the intestinal parasite *Eimeria*, is a universal problem in the poultry industry. The disease most notably characterized by diarrhea and enteritis is the most expensive disease affecting the poultry industry today. Treatment costs and lost performance total an estimated \$3 billion dollars each year worldwide (Dalloul and Lillehoj, 2006). Traditionally, the poultry industry has relied heavily on the use of coccidiostats to prevent or treat the disease (William, 2002). Unfortunately, species of *Eimeria* easily develop resistance to chemicals and antibiotics making them less effective for long-term treatment (Li et al., 2004). A recent field study conducted by Chapman and Rathinam (2007) revealed the majority of turkey strains of *Eimeria* are either partially or fully resistant to the commonly used ionophore, monensin. The growing demand for naturally raised poultry products, and increasing chemical resistance has fueled the need to find alternative methods to prophylactic treatments for the control of coccidiosis. Consequently, intensive rearing systems favor the *Eimeria* life cycle (Long, 1984) therefore the threat of coccidiosis is unlikely to disappear.

Eimeria are single-cell obligate intracellular parasites with a complex life cycle consisting of both asexual and sexual stages. Species of *Eimeria* are host specific and seven species infect the turkey. Of the seven, four of them are considered pathogenic or of economic importance: *Eimeria meleagritidis*, *Eimeria dispersa*, *Eimeria gallapovonis*, and *Eimeria adenoides* (Saif, 2003; Charlton, 2006). Coccivac-T®, one of the two live coccidial vaccines commercially available for the turkey, contains

oocysts from all four pathogenic strains of *Eimeria*. Coccidiosis vaccination in the turkey is relatively new when compared to the chicken. The first anticoccidal turkey vaccine, Coccivac-T®, appeared 21 years ago while the first chicken vaccine appeared nearly 60 years ago (Williams, 2002). Although vaccines appear to be a viable alternative to prophylactic treatment, side effects such as post-vaccinal setbacks in weight gain have limited their acceptance (Danforth, 1998) even though reports of compensatory growth exist in the chicken (Danforth, 1998 and Li et al., 2005). Reports also indicate that medicated flocks consistently have significantly higher body weights and lower feed conversion rates than vaccinated flocks (Danforth, 1998; Li et al., 2005; Johansen et al., 2007; Rojs et al., 2007). There is a lack of peer-reviewed data regarding coccidiosis vaccination in turkeys. Coccivac-T® is typically applied at the hatchery via a spray cabinet. A 10,000-dose vial of the vaccine is mixed with 280 mL of water and aerated to keep oocysts suspended in solution (Coccivac-T® Instructions). Green dye is added to the vaccine to promote preening and oocyst ingestion. Hydration levels and pecking order may affect uptake and lead to uneven exposure. Initial uneven vaccine exposure may result in adverse growth effects or mortality in the brooder barn (Dasgupta and Lee, 2000).

The progression of the coccidiosis and its characteristics between the chicken and the turkey are somewhat different therefore, data acquired in the chicken is not fully applicable to the turkey. Different species of *Eimeria* infect the turkey than the chicken and the coccidial life cycle is shorter. Although coccidiosis is very common in the turkey industry, the disease often times goes undiagnosed (Saif, 2003). Diagnosis is

difficult because species of *Eimeria* that infect the turkey do not infiltrate the intestinal wall very deeply. Intestinal lesions heal very quickly and are often times missed upon necropsy when clinical signs are observed (Saif, 2003).

The objective of this trial was to examine vaccine induced oocyst shedding patterns in turkey poult s g avaged with a single dose of Coccivac-T® on day of hatch. Shedding patterns were studied through the daily monitoring and enumeration of oocysts in fecal and litter samples. The goal was to characterize vaccine oocyst shedding patterns for the subsequent lesion and immune response trials. To understand and isolate vaccine specific characteristics, poult s were grown under experimental conditions.

Materials and Methods

Experimental Design

The experiment was set up as a time course study with four identical treatment groups. One-hundred newly hatched Hybrid hen poult s from a recycled Willmar Poultry Company breeder flock thirteen weeks into production were obtained from Willmar Poultry Company Hatchery (Willmar, Minnesota). Poult s were serviced according to routine hatchery procedures and randomized into four replicate groups of 25 birds. Average poult weight per group ranged from 60 to 65 grams. One vial of Coccivac-T ® (TCV-4) (Serial Number 94380002) provided by Intervet/Schering-Plough Animal Health was mixed according to the manufacturers' specification by mixing a 10,000 dose vial with 280 mL of distilled water and five mL of green dye. To ensure uniform dosing, each bird was g avaged with 0.28 mL of vaccine solution. Based on hemocytometer

counts, 0.28 mL of vaccine mixture contained approximately 500 oocysts. According to the specifications, Coccivac-T® vaccine contained live oocysts from *Eimeria adenoeides*, *Eimeria meleagrimitis*, *Eimeria gallopavonis*, and *Eimeria dispersa*.

Before poults were placed, three litter samples were obtained from each pen. Poults were housed in individual group pens in an isolation brooder room on wood shavings. The pen number represented the group number. The pen set up was similar to that typically seen in commercial turkey operations, for example, birds were confined to small cardboard rings placed under the brooder stove for the first days in addition to close access to feed and water. On day six post hatch each group was let out of the cardboard rings into a larger individual group pen. There was approximately 0.85 square feet per bird. Feed and water was available *ad libitum*. Poults were fed a (Nutrena Naturewise® Gamebird Starter Crumbs 91183 NR 0504, Runnings, Willmar, MN) non-medicated ration consisting of 27% crude protein. Body weights from five random birds per group were taken on a weekly basis for four weeks. Three 10 g litter samples were randomly obtained from the top inch of the litter in each pen on a daily basis for 30 days and stored in Whirl-pak® bags at 4°C until processed. In addition to the litter samples, three 4 g fecal samples were obtained daily for 30 days and stored in the same manner as the litter samples. The study was conducted using Willmar Poultry Company dba Ag Forte animal welfare guidelines.

Determination of Oocysts in Fecal Samples

The number of oocysts shed in the fecal droppings was determined by using a protocol provided by Dr. Steve Fitz-Coy from Intervet/Schering-Plough Animal Health (personal communication). The 4 g fecal sample was homogenized thoroughly by hand in the Whirl-pak® (Nasco®, Salida, CA) bag. Twelve mL of double distilled water was added to the bag and the sample was homogenized again. Once the fecal material was uniformly suspended in the water, 10 µL of the suspension was removed from the bag and both chambers of a hemocytometer were loaded. Oocysts found in the large center square and four large corner squares of each of the chambers were counted. The hemocytometer was then cleaned and reloaded with the next sample. Four chambers were counted per sample. Samples that had very high concentrations of oocysts were diluted with an additional 12 mL of reverse osmosis water to allow more accurate counting. The amount of oocyst per gram of fecal material was calculated according to the respective dilutions.

Determination of Oocyst Shedding in Litter Samples

Oocyst shedding patterns in the litter were determined using the method published by Pfizer Animal Health in “Poultry Coccidiosis- Diagnostic and Testing Procedures” (Conway et al, 1991). One-hundred mL of tap water was added to the 10 g litter sample in the Whirl-pak® bag. The sample was homogenized by hand until thoroughly mixed and allowed to soak for 24 hours at 4°C. The Whirl-pak® bag was then shaken vigorously to thoroughly mix the contents and filtered through a single layer

of cheesecloth into a beaker. Fifteen mL of filtrate was poured off into a centrifuge tube and then centrifuged at 5,000 rpm for five minutes and the supernatant was decanted. The solid pellet at the bottom of the tube was re-suspended in three mL of saturated sodium chloride salt solution using a vortex. After the pellet was re-suspended, additional saturated salt solution was added to the test tube to equal 15 mL of litter solution. In order to maintain sample consistency, the test tube was inverted 10 times before the subsample was removed. A two-chambered McMaster egg counting slide was charged with the litter solution. The slide sat for one minute prior to reading to allow the oocysts to float to the top of the solution and all oocysts within the grid of each chamber were counted. The McMaster slide was rinsed thoroughly with tap water between samples. Oocysts per gram of litter were calculated according to the published protocol.

Statistical Analysis

Statistical analysis to determine if pens differed in body weight was performed using a one-way ANOVA test with SPSS® Graduate Pack 16.0 for Windows Software (SPSS® Inc, Somers, NY). Differences in the mean body weights between the groups were considered to be significant if probability (P)-values were <0.05 . Error bars on the graphs are at a 95% confidence interval.

Results and Discussion

One-day post hatch vaccination, the droppings of the birds in the litter appeared green most likely due to the dye used in the vaccine. Examination of the droppings

revealed a large amount of degraded oocysts and or ruptured oocysts in addition to a few sporulated oocysts. According to Williams (1998), up to 20% of ingested oocysts can pass through the gastrointestinal tract undamaged. On day seven, some birds started to exhibit some ruffled feathers. On day nine, trace amounts of blood were seen in the fecal droppings in pen number three. On day 10, blood started to appear in the droppings of pens number one and four. On day 14, there were trace amounts of blood in the droppings of all groups. The amount of blood in the droppings increased through day 17. On day 17, several birds in each pen exhibited clinical signs of coccidiosis. They were hunched over and the heat in the rooms needed to be increased two degrees to make the birds comfortable, possibly indicating hypothermia or fever in response to the infection. Pens three and four had trace amounts of blood in the feces on day 18. Pens one and two had trace amounts of blood in the droppings on day 20. The amount of blood in the droppings appeared to peak again at day 21. Again, a few birds appeared lethargic with ruffled feathers. After the 22 day, the birds appeared to thrive, the presence of blood in the droppings was less frequent, and oocyst cycling appeared decrease drastically. The unevenness in the onset of symptoms between pens correlates with the slight variability in oocyst shedding patterns seen. This is likely due to the coprophagic nature of individual pens. All lethargic and sick birds recovered and the 30-day livability was 100%, similar with observations by Rojs et al. (2007). Since poult were gavaged with the vaccine, exposure level was likely higher. Clinical symptoms may have been as a result of a higher vaccine exposure

Oocyst Shedding via Fecal Sampling

To obtain a more accurate idea of oocyst shedding in the fecal droppings, samples were run in duplicate. Samples were averaged to obtain daily oocyst output for each individual pen. Fecal samples reflect the intensity of the coccidial infection at a specific point in time (Williams, 1998). Oocyst shedding patterns for individual pens followed a similar trend with slight individual pen variations (Fig. 1). When all pens were averaged, there were three distinct peaks at days 5-6, 13-17 and 19-20 post vaccination (Fig 2).

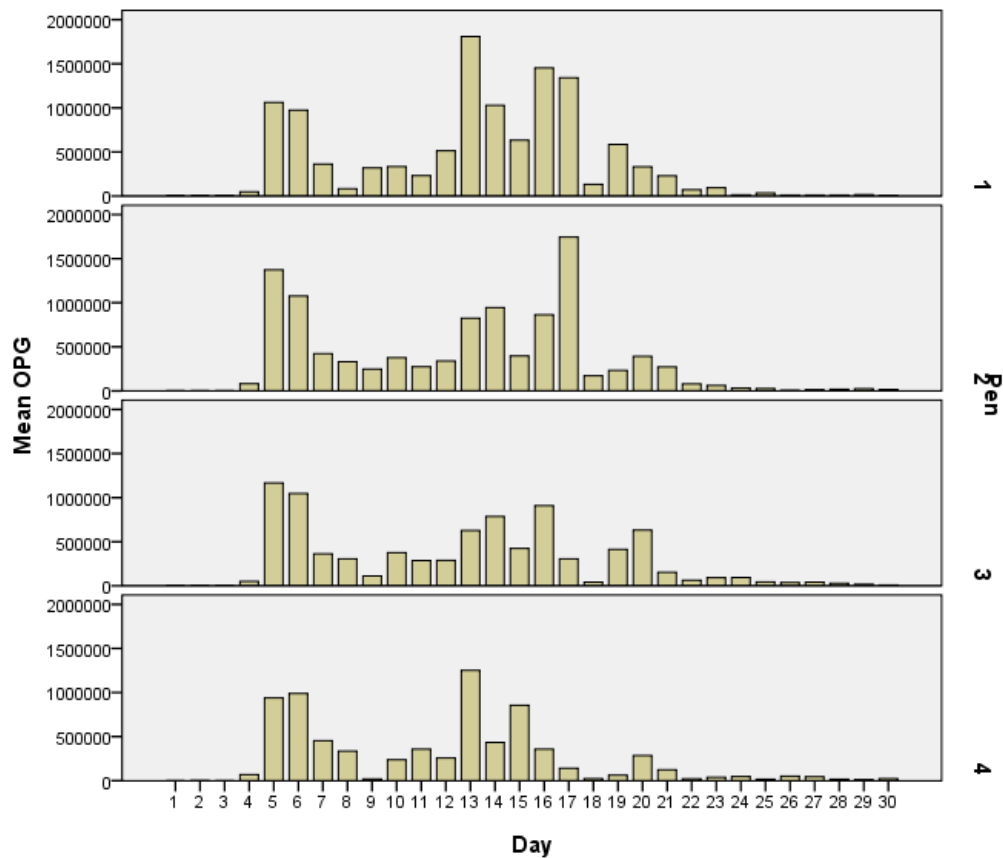


Figure 1. Mean daily OPG fecal by pen.

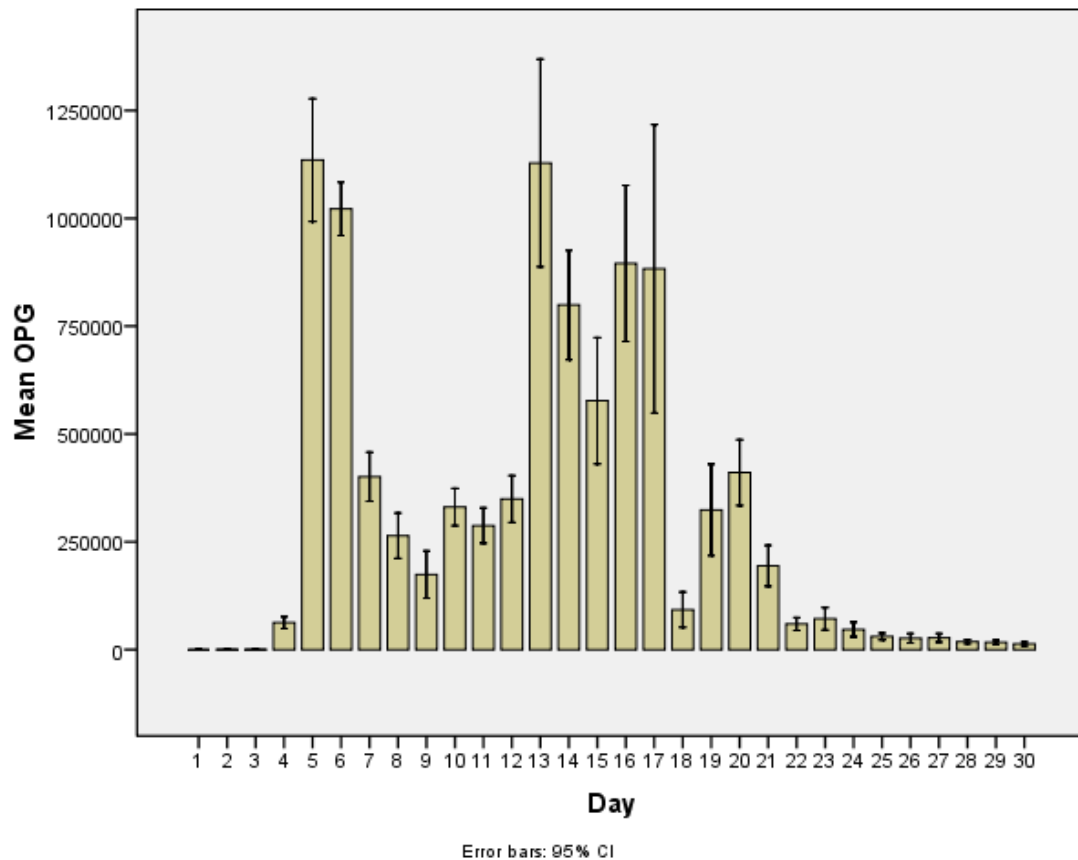


Figure 2 . Combined mean daily OPG fecal.

The average number of days in a life cycle of Coccivac-T® appeared to be approximately five days. This is shorter than the typical seven day cycling pattern seen in the chicken. There was a slight increase in oocyst shedding at around day 10. This peak is most likely lower and or delayed because the birds were released from the cardboard rings on day six. The rings were expanded during the first peak in shedding and oocyst exposure and uptake was somewhat limited. Oocyst shedding was shown to be influenced by management practices. Different management practices may

potentially affect efficacy of the vaccine. A uniform peak between pens was seen following the controlled gavaged dose. Thereafter, there was a slight variation in shedding patterns due to the coprophagic behavior of the individual pen (Fig. 1). Nonetheless, each of the four pens followed a similar vaccinal oocyst shedding pattern.

Oocyst Shedding via Litter Sampling

Mean daily oocyst per gram of litter by pen was highly variable (Fig. 3). When all pens were averaged throughout the study, oocyst shedding patterns appeared somewhat similar to the patterns seen in the fecal samples (Fig. 4). The litter samples were more variable and less sensitive than the fecal samples. This is consistent with what Williams (1998) described about litter samples. Litter sampling minimizes small scale peaks often times seen in fecal samples and tends to measure oocyst accumulation in litter rather than the intensity of the coccidial infection (Williams, 1998). There is more variability in litter samples depending upon where the sample is collected. Naturally, oocyst concentrations were higher where birds tended to migrate, such as the feeders and drinkers, compared to the edges of the ring therefore multiple samples need to be obtained to correlate with fecal sampling. Smaller scale peaks seen in the litter samples after day 20 were most likely from birds that may still have been cycling.

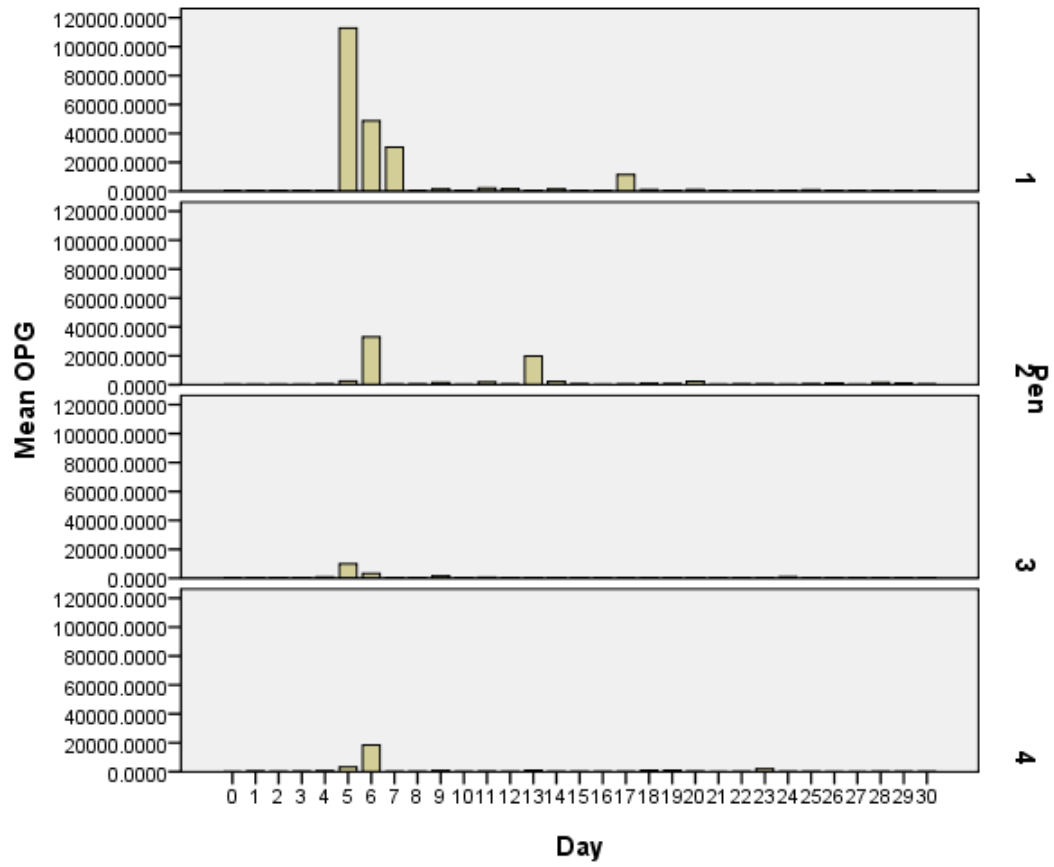


Figure 3. Mean daily OPG litter by pen.

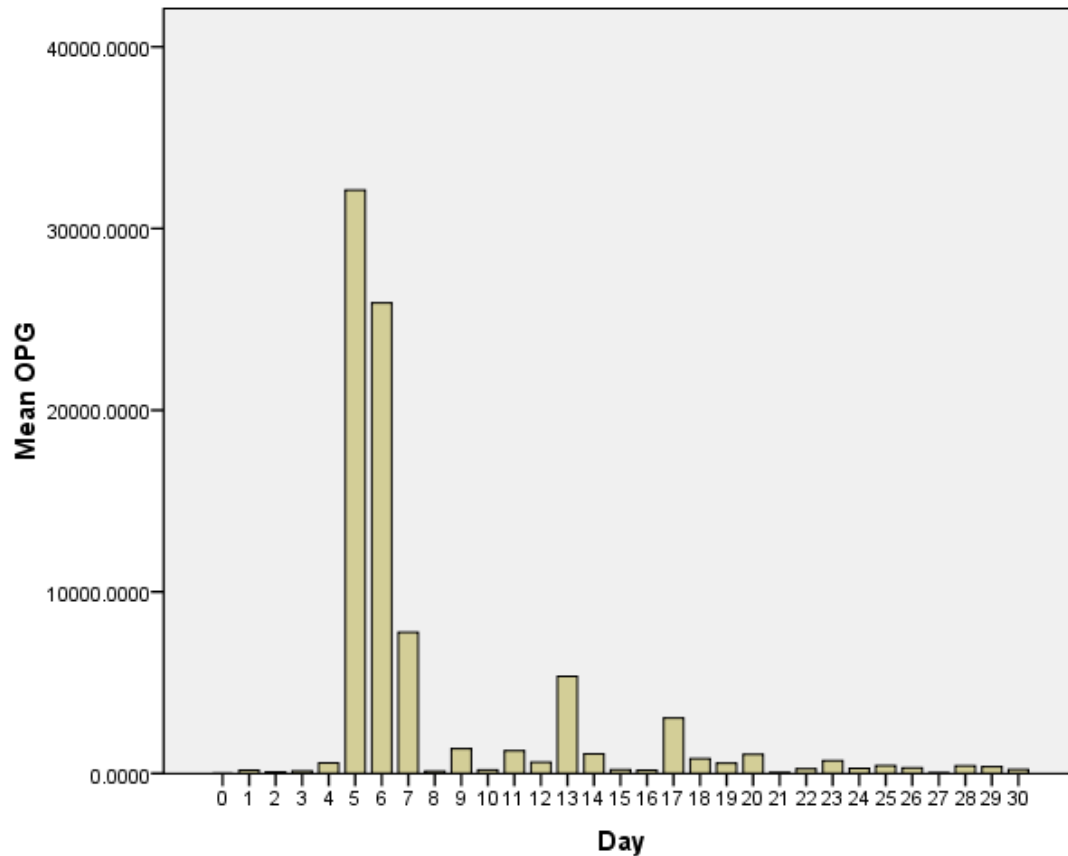


Figure 4. Combined mean daily OPG litter.

Body weight trends and oocyst cycling were correlated. After the week three body weights, rate of growth increased two to three times of what it was week two to week three (Fig. 5). Based on fecal oocyst counts, oocyst shedding dropped dramatically the third week. The birds appeared to exhibit an increase in growth during the third and fourth week post vaccination. It is unknown if this is a normal growth curve or a form of compensatory growth. Chapman (1996), Danforth (1998), Williams (1998), and Li et al. (2005) described a post-vaccinal set back in weight gain with

coccidiosis vaccinations. Long-term setbacks in weight gain (Williams, 1998) as well as compensatory growth in vaccinated birds (Danforth, 1998; Li et al., 2005) have been reported. Differences in body weight between pens were not observed. (Fig. 5)

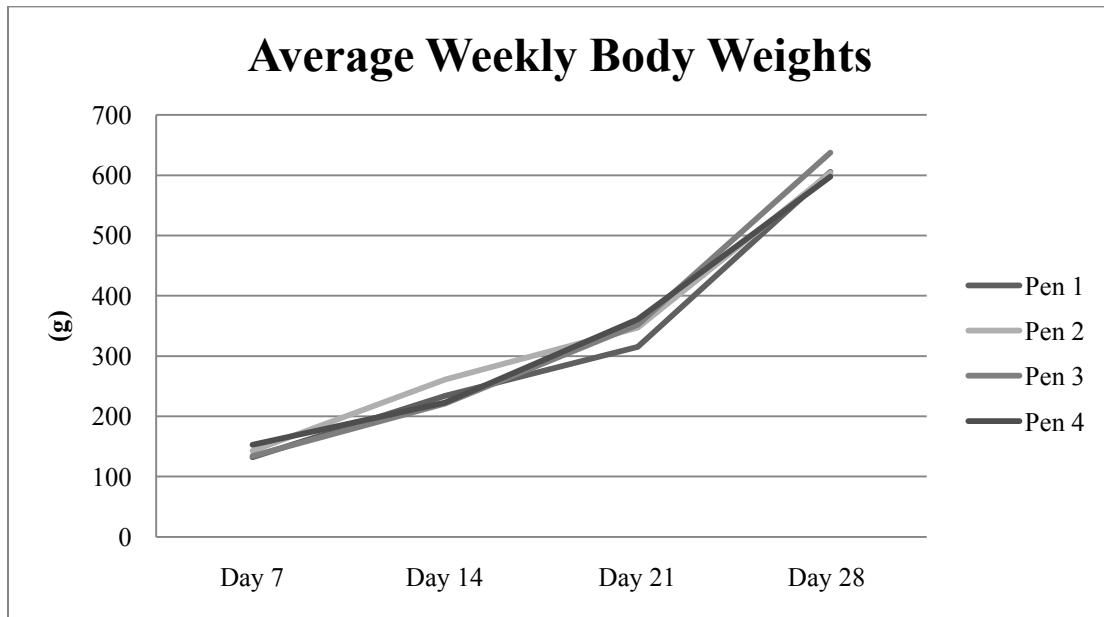


Figure 5. Average weekly body weight by pen.

There is a general lack of information describing the role vaccinations have in the control of turkey coccidiosis. This is the first paper to investigate the coccidiosis vaccine oocyst shedding patterns and gross observations of coccidiosis vaccination in the turkey in detail. A better understanding of the disease characteristics in the turkey and potential control measures such as coccidiosis vaccines may provide an explanation to observations seen in the field and better ways to manage vaccinated flocks. The results of this trial are the basis for subsequent lesion and immune response studies.

CHAPTER IV
COCCIDIOSIS VACCINE INDUCED LESIONS AND MUCOSAL GENE
EXPRESSION OF IL-10 AND IL-1 β

Overview

Coccidiosis vaccine dose and its effects on body weight, histological lesions, and mucosal gene expression of turkey poualts vaccinated on the day of hatch were investigated. Poualts were gavaged with a 0.28 mL solution containing the equivalent to either 0 x, 0.5 x, 1 x, or 2 x manufacturers available dose of vaccine oocysts and raised on wood shavings under isolation conditions. During times of peak vaccine oocyst shedding, determined in a previous study, poualts were sacrificed, weighed, and three areas of the gastrointestinal tract were collected. A two cm section of intestine centered over the Meckel's diverticulum, the ileocecal junction, and the middle of the ceca were collected for histological examination. An approximate 0.4 g sample of adjacent tissue was obtained from each section for gene expression analysis. Histological measurements from the tip of the villus extending down to the base of the *lamina propria*, width of the villus, and *muscularis mucosae* thickness were taken using imaging software. Body weight and oocyst dose were inversely related. Significant differences with regards to the intestinal measurements and dose response were seen but the results were not always linear. A significant variation among individuals within the same group was seen, therefore limiting statistical data. Mucosal gene expression of IL-10, IL-1 β , and GAPDH was examined in the control group and twofold vaccine dosed

group. Analysis of the genes was obtained through mRNA extraction of the harvested tissues, a conversion of mRNA into cDNA, and quantified using qRT-PCR. Fold changes between the control and treated group were calculated using the $2^{-\Delta\Delta CT}$ method. Interleukin-10 was significantly up regulated at the ileocecal junction and ceca on day five, the ceca on day 10, 13, and 17, the ileocecal junction on day 17, and significantly down regulated in the ceca day 20. Interleukin-1 β was significantly up regulated on day 5 in the ileocecal junction and ceca, the ceca on days 10 and 13, and significantly down regulated in the ileocecal junction on day 20. No significant changes in gene expression were seen in the Meckel's diverticulum at any point during the course of the study. Extreme outliers were excluded from statistical analysis but are the topic of further investigations of the turkey's immune response.

Introduction

Coccidiosis, characterized by diarrhea and enteritis, is a universal problem in the poultry industry. Caused by various species of *Eimeria*, the disease costs an estimated \$3 billion worldwide each year (Dalloul and Lillehoj, 2006). These single-cell protozoa are species-specific obligate intracellular parasites. Seven species of *Eimeria* are known to infect the turkey. Four of them are considered pathogenic and of economic significance, *Eimeria meleagridis*, *Eimeria dispersa*, *Eimeria gallapovonis*, and *Eimeria adenoides* (Saif, 2003; Charlton, 2006). The industry has heavily relied on the use of chemicals since the first sulfur based anti-coccidial chemotherapeutic drug appeared in 1939 (Long, 1984) to control the disease. Species of *Eimeria* easily develop

resistance to chemicals making them less effective for continuing treatment (Li et al., 2004). Chapman and Rathinam (2007) determined the majority of field isolate strains of *Eimeria* in turkey facilities are either fully or partially resistant to the commonly used ionophore monensin.

Coccidiosis vaccination appears to be a viable option but side effects have limited its acceptance (Danforth, 1998). There have been several contradictory reports regarding bird performance and vaccination. Vaccinated bird performance is not always equivalent to what is typically seen with birds treated with prophylactic medications (Danforth, 1998). Although mortality appears to be the same (Rojs et al., 2007), several reports concur that vaccinated birds exhibit a post vaccinal set back in weight gain (Chapman, 1996; Danforth, 1998; Williams, 1998). Studies indicate that vaccinated birds exhibit compensatory growth and are comparable in weight to unvaccinated and unmediated controls at the time of market (Danforth, 1998; Li et al., 2005). Additionally, vaccinated birds tend to have poorer feed conversion when compared to medicated birds (Li et al., 2005). However, production costs of both vaccinated and medicated birds appear to be similar (Lee et al., 2009).

In addition to inconsistent effect on growth rate, consistent uniform vaccination is difficult to obtain orally. Coccivac-T® (Intervet/Schering Plough Animal Health, Summit, NJ) coccidiosis vaccine is typically applied at the hatchery via a spray cabinet. Poults acquire the vaccine via the ingestion of oocysts while preening each other (Coccivac-T® Instructions). The first dose of the vaccine is critical in acquiring protection. If poults do not receive an initial dose at the time of hatch, it is possible that

the exposure in the brooder house will be too high and result in adverse growth effects or mortality (Dasgupta and Lee, 2000). Uniform consumption of vaccine oocysts is critical for the uniform development of immunity (Dasgupta and Lee, 2000). Higher doses of oocysts are associated with decreased growth in chickens (Hu et al., 2000), but not necessarily with lesion scores (Conway et al. 1999). Weight gain, feed consumption, and feed conversion may be a better way to analyze coccidial control of a product rather than traditional intestinal lesion scoring. Lesion scoring fails to measure oocyst dose (Conway et al., 1999).

Avian Immune Response

The avian immune response to *Eimeria* infections appears to be very complex. The immune mechanisms involved are dependent upon the area of the gastrointestinal tract that is parasitized, the *Eimeria* species involved in the infection, as well as the developmental stage of the parasite (Lillehoj, 1998; Talabia and Mulcahy, 2005). When *Eimeria* are accompanied with other pathogens, such as *Clostridium perfringens*, the immune mechanisms involved become even more complex (Collier et al., 2008). Understanding how the avian immune system responds to enteric pathogens, particularly *Eimeria*, may provide insight and better understanding on how to combat the coccidiosis and associated diseases such as necrotic enteritis and gangrenous dermatitis. Previous studies in the chicken indicate the up regulation of IL-1 β (Kaiser et al., 2004), IL-2, IL-5, IL-6, IL-10, (Yun et al., 2000), and IFN- γ (Lillehoj, 1998) across regions of the gastrointestinal tract in response to challenges with *Eimeria*. A cDNA microarray of

over four-hundred genes in the intestinal intraepithelial lymphocytes during primary and secondary *Eimeria maxima* infections in leghorn chickens revealed significant changes in IL-1 β , IL-2, IL-6, IL-8, IL-15, and IL-18 (Kim et al., 2008).

Interleukin-10

Interleukin-10, secreted by activated macrophages and T-regulatory cells, is one of the most important immunoregulatory cytokines. It helps to maintain balance of the innate and cell mediated immune responses by inhibiting activated macrophages (Abbass et. al, 2007) and consequently inflammation (Kaiser et al., 2004). During peak parasitic infections in chickens, IL-10 expression is elevated. The increase in IL-10 may be an attempt of the parasite to evade macrophage-mediated destruction by suppressing the host's inflammatory response (Collier et al., 2008).

Interleukin -1 β

Interleukin-1 β , a pro-inflammatory cytokine produced by the macrophages, endothelial cells, and epithelial cells, mediates the inflammatory response of the host. The level of response or inflammation depends on the amount of IL-1 β produced. Small quantities result in local inflammation. Large concentrations of IL-1 β enter the blood stream, stimulate the synthesis of acute phase plasma proteins as part of the early innate immune response, and stimulate the production of IL-6, which promotes the growth of B-lymphocytes (Abbass et al., 2007), and increases chemokine and corticosterone production (Hilton et al., 2002). Although IL-1 β appears to have a similar function in

birds as it does in mammals, the location of genetic loci on the chromosome is not similar to the mammalian analogue (Abbass et al., 2007). Quantitative real time polymerase chain reaction (qRT-PCR) analysis has shown an 80-fold increase in IL-1 β gene expression seven days post challenge with *Eimeria tenella* in chickens. Similarly, challenges with *Eimeria maxima* tend to up regulate IL-1 β gene expression but to a much lesser extent (Kaiser et al., 2004).

Gene Expression

Gene expression profiling of immune related components, such as cytokines and Toll-like receptors, throughout the course of infections may provide insight to controlling particular diseases (Abasht et al., 2008). The characterization of mucosal immune related genes in the chicken is to some extent focused on responses to infections with *Salmonella*, although limited data concerning coccidial infections in the chicken is available. Gene profiling research in the turkey is absent in the peer reviewed literature. Gene expression is accurately quantified using qRT-PCR through the extraction of mRNA in the biological sample and amplification of targeted genes via sequence specific primers and probes (Roth, 2002). Endogenous genes, such as, such as glyceraldehyde 3-phosphate dehydrogenase (GAPDH) are used as internal control references (Zhou et al., 2010). Livak and Schmittgen (2001) described the $2^{-\Delta\Delta CT}$ method to calculate and analyze gene expression data acquired using qRT-PCR.

Based on Toll-like receptor mRNA expression in the duodenum and cecal tonsils, native breeds of chickens in India are immunologically more competent and

disease resistant compared to the commercial equivalent (Dhinakar Raj et al., 2009). The selection of increased performance, such as growth, negatively affects the immune response (van Hemert et al., 2006; Dhinakar Raj et al., 2009). Similarly, comparing gene expression in fast and slow growing lines of broilers indicates distinct differences in gene expression in the jejunum when challenged with *Salmonella* (van Hemert et al., 2006). The faster growing chicken line responds to the challenge with an increase in genes that enhance T cell activation while the slower growing line responds much differently and more efficiently with an increase in macrophage activation. The different responses seen between the fast and slow growing broiler lines to the same pathogen may potentially explain the variations in susceptibility to *Salmonella* (van Hemert et al., 2006) or potentially other pathogens.

The progression of the coccidiosis and its characteristics between the chicken and the turkey are somewhat different therefore, data acquired in the chicken may not be fully applicable to the turkey. Different species of *Eimeria* infect the turkey than the chicken and the coccidial life cycle is shorter in turkeys. Non-pathogenic species of *Eimeria* are also found in the turkey's gastrointestinal tract making diagnosis more complex (Saif, 2003; Charlton, 2006). Although coccidiosis is very common in the turkey industry, the disease often times goes undiagnosed (Saif, 2003). Lesions tend to heal more quickly in the turkey and are may be missed upon necropsy when clinical signs are observed (Saif, 2003). This may be due to the shallow depth of the epithelial cells that the coccidia invade.

Objectives

The first objective of this study was to examine the effects variable doses of coccidiosis vaccine, 0x, 1/2x, 1x, or 2x manufacturers available dose, on the day of hatch had on body weight and vaccine induced intestinal lesions during peak oocyst shedding over the course of 20 days. The second objective of the study was to investigate changes in mucosal gene expression in the tissue adjacent to the Meckel's diverticulum, ileocecal junction, and ceca. Understanding the turkey's response to coccidiosis vaccines may disease provide helpful insight to controlling it in the future.

Materials and Methods

Experimental Design

Five-hundred newly hatched Hybrid® (Ontario, Canada) turkey hen poult were acquired from a recycled Willmar Poultry Company (Willmar, MN) breeder flock 20 weeks into production. Poults were serviced according to routine hatchery procedures, randomized into four treatment groups, and gavaged with four different doses of Coccivac-T® (TCV-4) (Serial Number 94380002) (Intervet/Schering-Plough Animal Health, Summit, NJ) coccidiosis vaccine comprised of the equivalent of 0 x, ½ x, 1x, or 2x the manufactures available dose. According to the specifications, the vaccine consisted of live oocysts of *Eimeria adenoeides*, *Eimeria meleagrimitis*, *Eimeria gallopavonis*, and *Eimeria dispersa*. Based on hemocytometer counts, the standard vaccine dose was 500 oocysts mixed in 0.28 mL solution. The vaccine was mixed according to the manufacturer's instructions using distilled water and green dye. Each

bird was gavaged with 0.28 mL of solution. The first treatment group consisted of a twofold vaccine dose. Vaccine was diluted in distilled water and green dye and contained approximately 1,000 oocysts. The second treatment group received the standard vaccine dose of 500 oocysts. The third group received the equivalent of one-half of a dose, 250 oocysts. The fourth group served as a control group and received a mixture of distilled water and dye. Each group was randomized again within itself into four replicates of 32 birds per replicate. Birds within each replicate were color-coded with a marker on the top of the head to ensure proper identification when the birds were removed from the pens and taken to the diagnostic laboratory for tissue collection.

All four replicates of each treatment group were placed in individual pens in separate identical isolation room. The pen and room setups were similar to commercial operations. The litter consisted of wood shavings and feed and water was available ad libitum. The diet consisted of a (Nutrena Naturewise® Gamebird Starter Crumbs 91183 NR 0504) (Runnings®, Willmar, MN) non-medicated ration with a minimum of 27% crude protein. Poults were initially placed within cardboard rings in each pen; these rings were removed at three days of age. Based on oocyst shedding patterns seen in a previous study, birds were euthanized at 5, 10, 13, 17, and 20 days post vaccination. On the day of the scheduled sacrifice, a fecal sample from each treatment group was taken and examined underneath the microscopically to ensure oocyst shedding was indeed occurring and the controls remained negative.

Five birds were randomly selected from each pen, 20 birds per treatment group, euthanized on the scheduled sacrifice day via cervical dislocation, and weighed.

Sampling locations were selected based on the localization of the species of *Eimeria* (Saif, 2003). A 2 cm cross section of the small intestine centered over the Meckel's diverticulum (MD), the ileocecal junction(ICJ) and middle of the ceca (Ce) were excised and immediately placed in individual labeled tubes with 35 mL of 10% neutral buffered formalin (Fisher Scientific, Fremont, CA) and stored at 4° C. An adjacent approximate 0.4 g section of the intestine was collected, weighed, fecal content gently removed, and immediately placed in individual labeled tubes with 0.3 mL of RNAlater® (Qiagen®, Valencia, CA). The samples were stored at 4°C for 24 hours and then stored at -80°C.

Formalin fixed tissues were sent to the Imaging Center at the University of Minnesota in St. Paul, MN for histological processing. After fixation, the tissue was dehydrated in varying concentrations of alcohol ranging from 30%-90%. The intestinal segments were cut into three sections and embedded in Paraplast for cross sectioning. A five µm transverse slice was sectioned, placed on a microscope slide, and stained with hematoxylin-eosin. Slides were scanned in using a Logitech® (Fremont, CA) camera modified to fit a Nikon® (Nikon Inc., Melville, NY) stereoscope at a fixed zoom of 200x. The Gnu image manipulation program (GIMP) (GNOME Foundation, Groton, MA) was used to acquire measurements. The scaling ratio of 179.33 pixels/mm was determined from images of a fixed scale. Three measurements from the tip of the villus extending down to the base of the *lamina propria*, width of the villus, and *muscularis mucosae* thickness were taken from two animals in each replicate. Measurement types

were selected based on the lesions that the species of *Eimeria* infecting the turkey produce.

Gene Expression Analysis

RNA was extracted from the intestinal sections from the first two animals in each replicate of the control and twofold vaccine dose group using an RNeasy® Plus Mini Kit (Qiagen®, Valencia, CA). The intestinal tissues were removed from the tube containing RNAlater® and cut in half. Half of the tissue was placed in a 2 mL microfuge tube and the retention tissue placed back in the tube containing the RNAlater® and stored in a -20° C freezer. Total RNA was isolated using an RNeasy® Plus Mini Kit (Qiagen) according to the manufacturer's instruction and stored at -80°C. The quantity of RNA in each sample was assessed using a NanoDrop® spectrophotometer. Samples that contained less than 100 ng per µl were concentrated using a freeze centrifugal vacuum concentrator. After concentration, if the RNA content in the sample was still less than 100ng/µl the sample was not used. One microgram of RNA from each sample was converted to cDNA by incubating with one µl of 20X RT Enzyme Mix (High Capacity RNA to cDNA Kit, Applied Biosystems, CA) in a final volume of 20 µl on a thermal cycler. The reaction was incubated at 37°C for 60 minutes and stopped by heating at 95°C for 5 minutes. The cDNA was then diluted to 200 µl with 0.1X TE buffer and stored at -20°C. Amplification was performed on a GeneAmp 7900 Sequence Detection System (Applied Biosystems) using 394-well plate. Each qRT-PCR reaction contained µl of diluted cDNA, 1 µl of 20X primers/probe Mix, 10 µl of 2× TaqMan Universal

Master Mix (Applied Biosystems), and H₂O in a final volume of 20 μ l. The thermal profile consisted of an initial hold at 50 °C for 2 min, followed by a single denaturation at 95 °C for 10 min, and then 40 cycles of 95 °C for 15 s, 60 °C for 60 s. Duplicate PCR reactions were performed for each sample cDNA. The resulting threshold cycle values were normalized to the endogenous GAPDH control gene and were calculated using the $2^{-\Delta\Delta CT}$ method (Livak and Schmittgen, 2001). The ΔC_T values between the treated and control group were compared and differences in expression of the IL-10 and IL-1 β were expressed as fold changes. Primer and probe sequences used in qRT-PCR are presented in Table 1.

Table 1. Real-time RT-qPCR primer and probes sequences of the targeted genes.

Gene	Forward Primer	Reverse Primer	TaqMan MGB Probe	Accession Number
GAPDH	CTCCTGTGACT TCAATGGTGA CA	CAGGAAACA AGCTTGACAA AATGGT	CCAGCACCCGC ATCAA-FAM	GQ184819.1
IL-10	TTTGGCTGCCA GTCAGTGT	GCTGGTGCTG GTCTTCATG	AAGCGCAGCAT CTCT-FAM	AM493432.1
IL-1 β	AAGGGCTACA AGCTCTACAT GTC	CGTCGGCTTC CTCCAGTT	CCGAGCCCACG CTGC-FAM	DQ393271.1

Statistical Analysis

Statistical analysis of the body weight and the histological measurements were done using a one-way ANOVA and a Duncan's Multiple Range Test using SPSS® Graduate Pack 16.0 for Windows (SPSS® Inc, Somers, NY). Probability (p)-values <0.05 were considered significant. Fold and gene expression changes were analyzed with a Student's T-test using SPSS® of the ΔC_T in the treated and control groups.

Results and Discussion

The day following vaccination, considerable amounts of green droppings were present in the litter of all groups most likely due to the dye used with the vaccine. Clinical symptoms such as blood in the droppings, ruffled feathers, lethargic birds and huddling appeared in the vaccinated appeared at various times throughout the course of the study. Inflammation and intestinal wall thickening was noted in all vaccinated groups starting on day five. Distended ceca, cecal cores, fibrino-necrotic tissue and mucosal damage in the ceca were present in all vaccinated groups day 13 (Figs. 6, 7, 8, and 9).

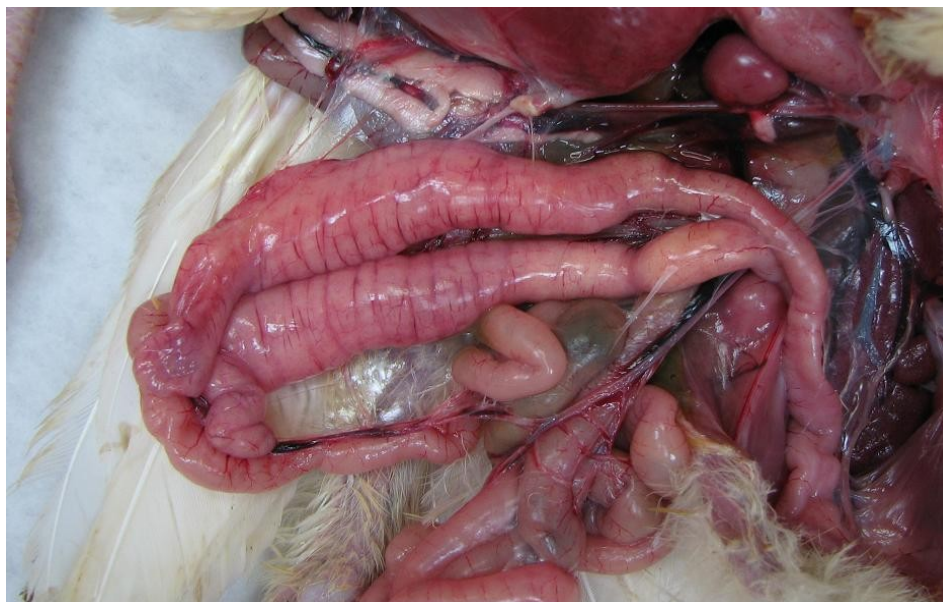

Fig. 6. Ceca distended, filled with fibrino-necrotic material.

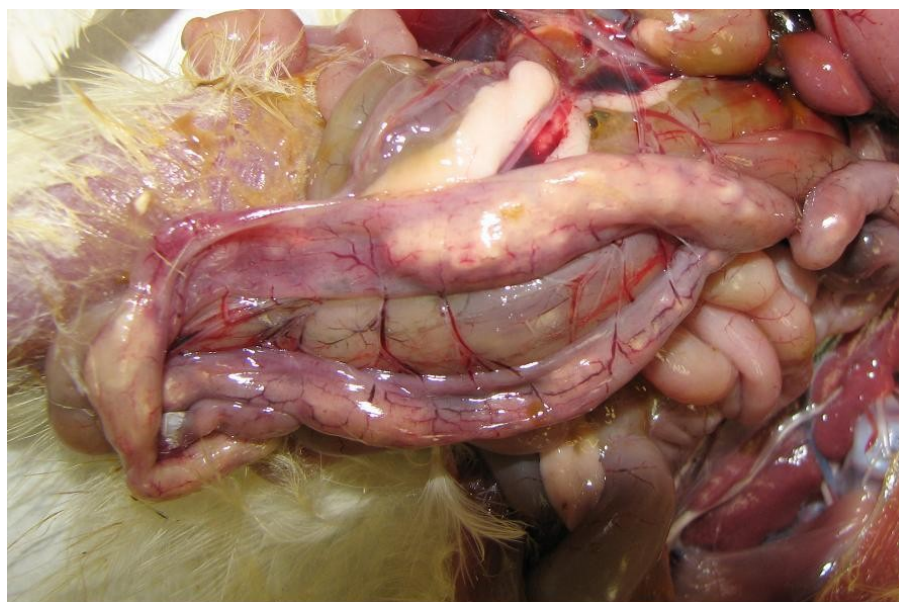


Fig. 7. Cecal cores visible through the intestinal wall.

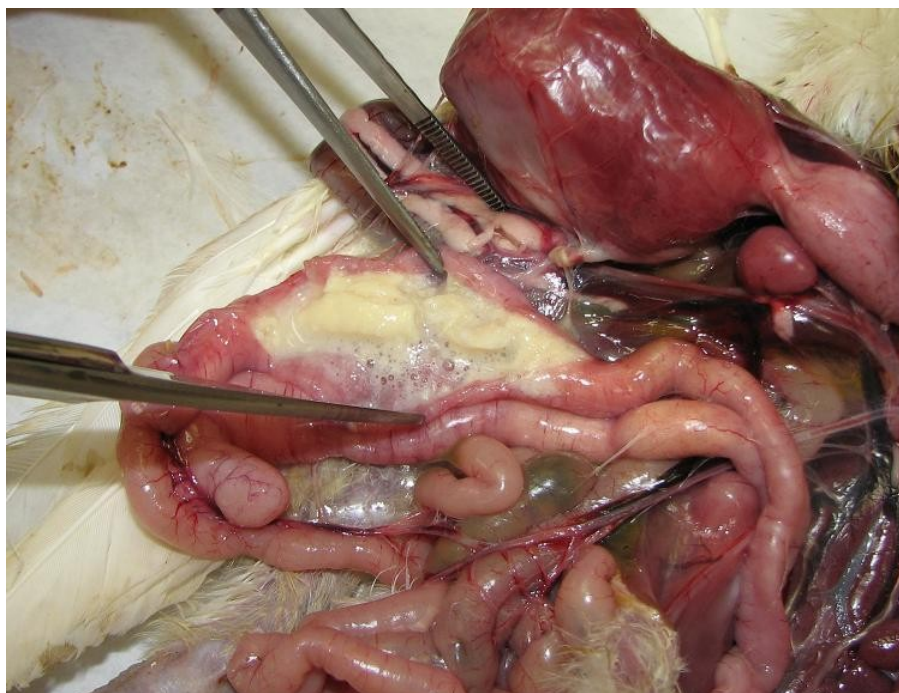


Fig. 8. Cecal cores - fibrino-necrotic material present in the lumen.

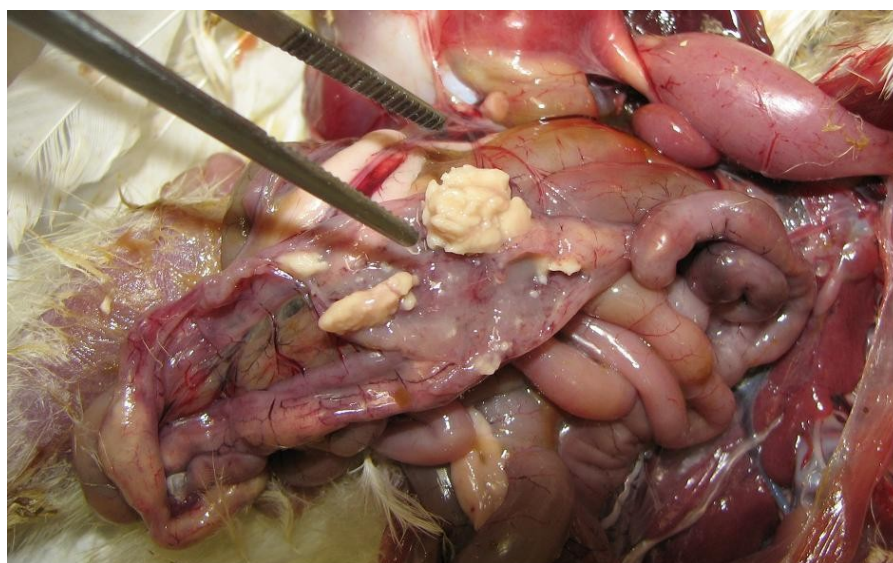


Fig. 9. Fibrino-necrotic material in the lumen and mucosal damage in the form of focal ulcerations and hemorrhaging.

Histological examination of the ceca, at an independent laboratory (Dr. Daniel Shaw, University of Missouri), revealed the intestinal lumen to be filled with fibrino-necrotic material with numerous oocysts (Fig. 10) in addition to the epithelial cells containing coccidia at numerous stages of development (Fig. 11 and 12). Cellular infiltration of the *lamina propria musosae* with heterophils and macrophages and substantial villus atrophy was also observed (Fig. 13). An intact villus from the control group is shown in Fig. 14.

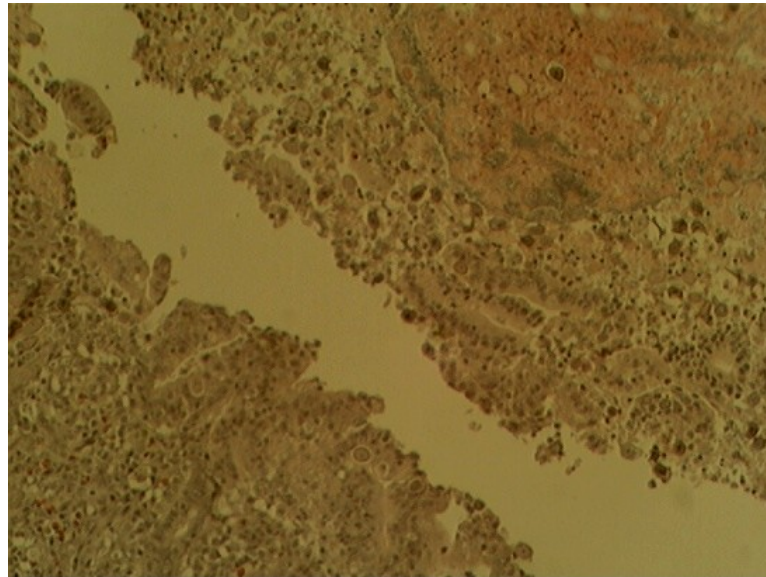


Figure 10. Lumen of the ceca filled with fibrino-necrotic material and coccidia.

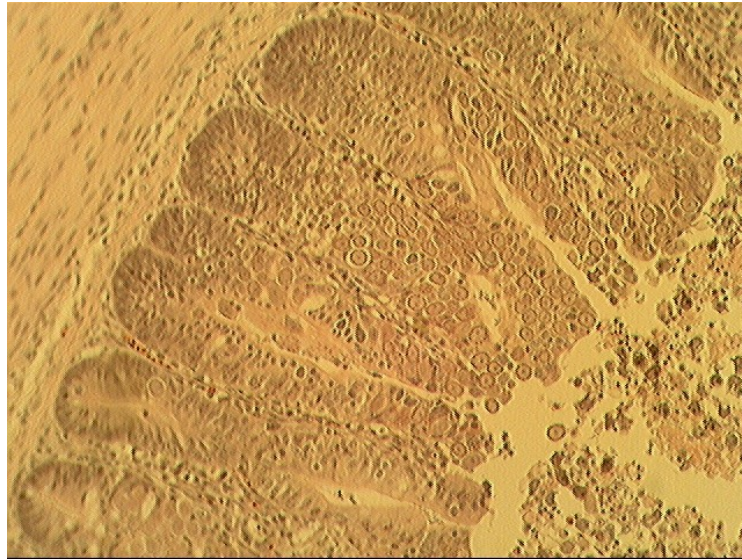


Figure 11. Epithelial cells in the ceca contain coccidia at numerous stages of development.

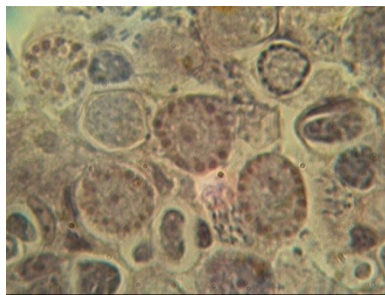


Figure 12. Coccidia at numerous stages of development. (Higher magnification)

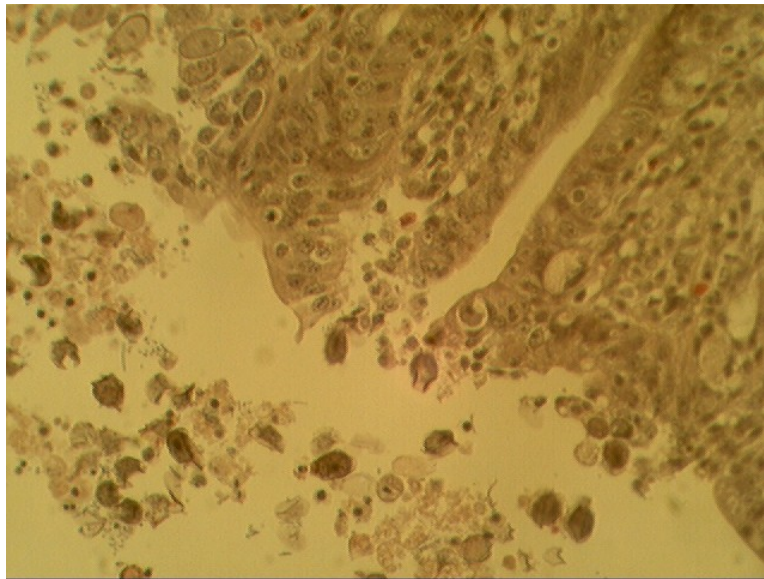


Figure 13. Atrophy of the villus.

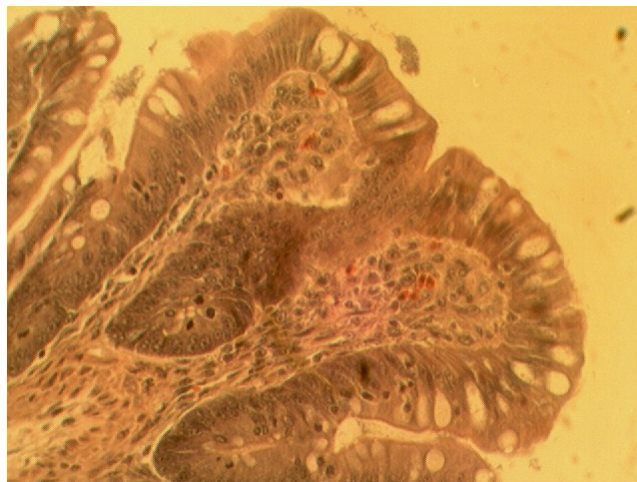


Figure 14. Control villus.

Body weights taken at the time of sacrifice revealed a significant difference between the treated and control groups starting at day five. (Fig.6) Oocyst dose and body weight were inversely related through day 17. These findings are consistent with

previous research in the chicken (Hu et al., 2000). Infection with a single oocyst can result in the production of up to one million oocysts (Conway et al., 1991). Very small differences in the challenge dose may produce major effects on the poult. Thus, lesions are difficult to control because of uneven oocyst consumption. The second and third cycles of the *Eimeria* life cycle are dependent upon the coprophagic nature of the individual and oocyst shedding of the flock. A longer grow out period is needed to determine if poult will exhibit compensatory growth, if the amount of growth is consistent among treated groups, and if gain is sufficient to be comparable in bodyweight to the controls.

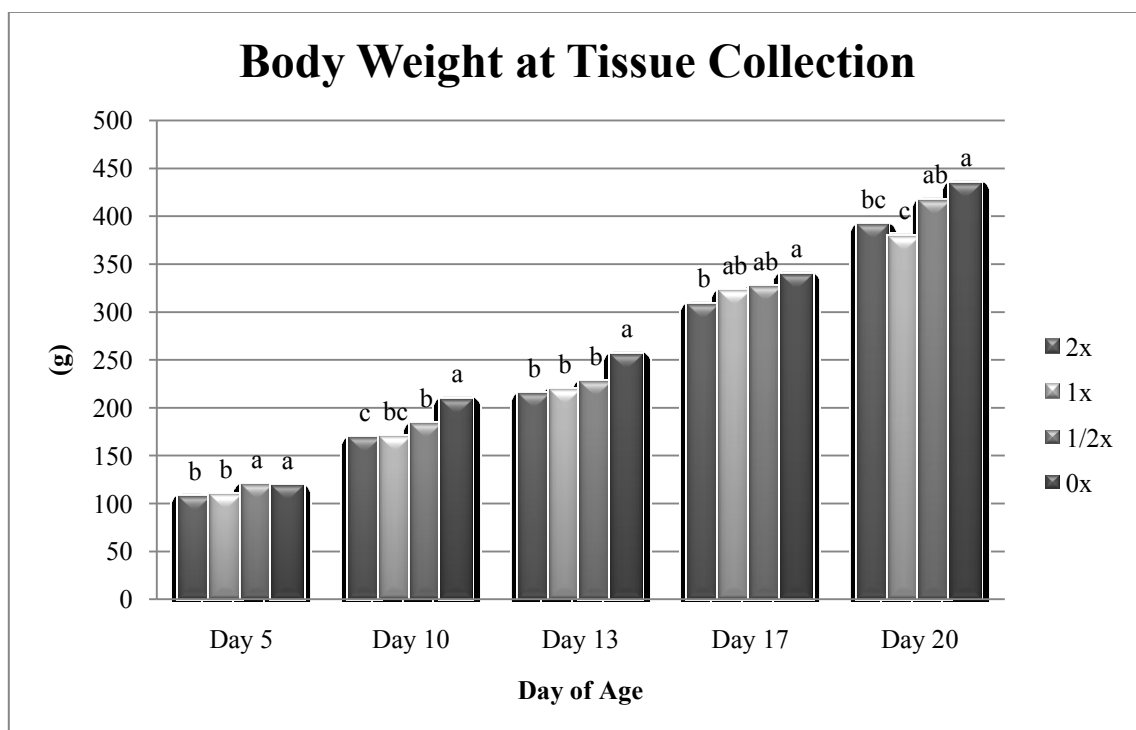


Figure 15. Body weight at the time of tissue collection. P-values <0.05 were considered significant.

Intestinal Measurements

The marked inflammation noted upon necropsy in the vaccinated groups can be clearly observed in the intestinal histopathology. Significant differences in the measurement taken from the tip of the villus to the base of the *lamina propria mucosae* were seen adjacent to the Meckel's diverticulum on day five and day 20 post vaccination (Fig. 7). The measurement was significantly larger in all vaccinated groups when compared to the controls on day five, most likely due to inflammation. On the contrary, measurements obtained from day 20 indicated the control group to have significantly longer villus than the 1/2x and 2x dose group. Few differences in villus width were seen, although there was a large decrease in width across all groups on day 17.

Muscularis mucosae thickness was significantly thicker in the control group on day 20.

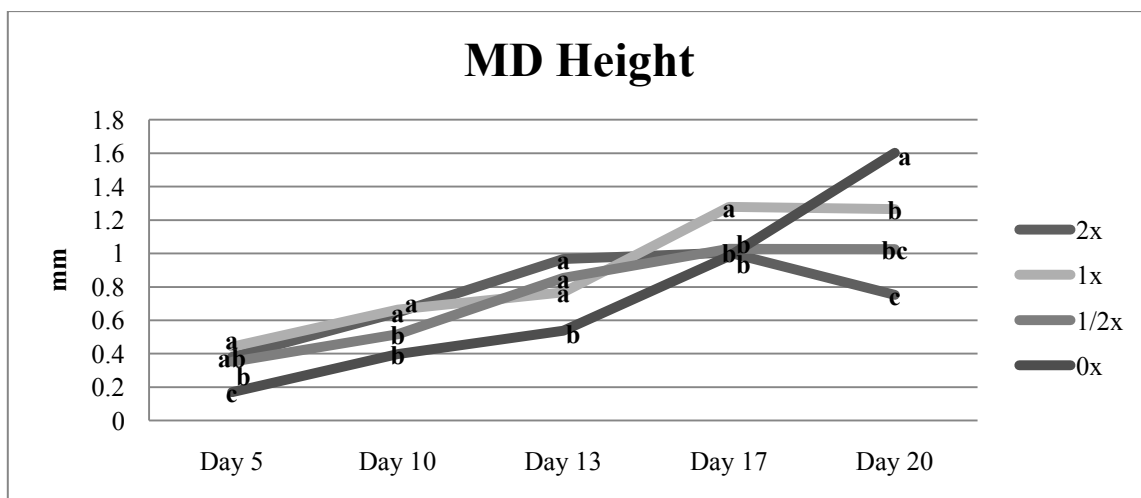


Figure 16. Intestinal measurements taken from the Meckel's diverticulum. P-values <0.05 were considered significant.

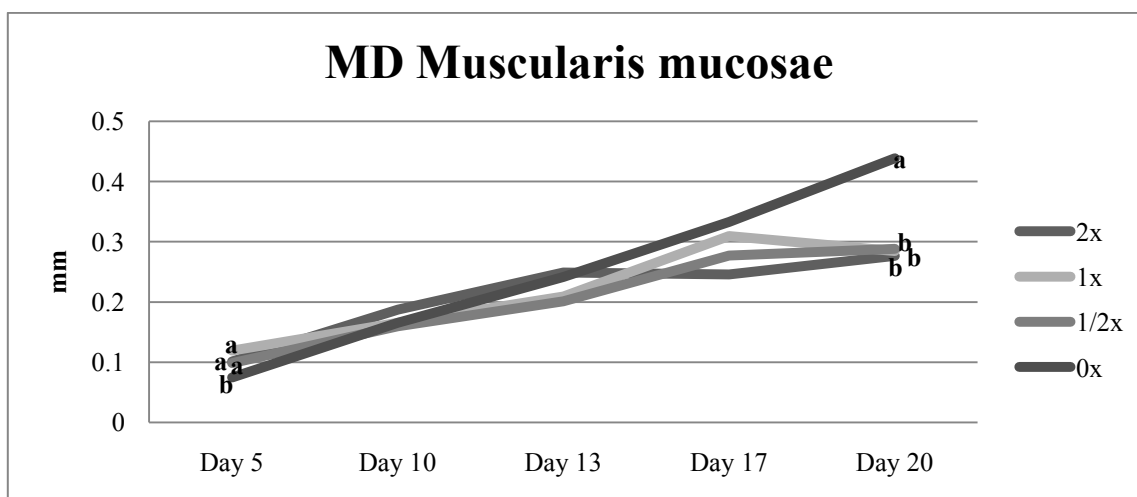
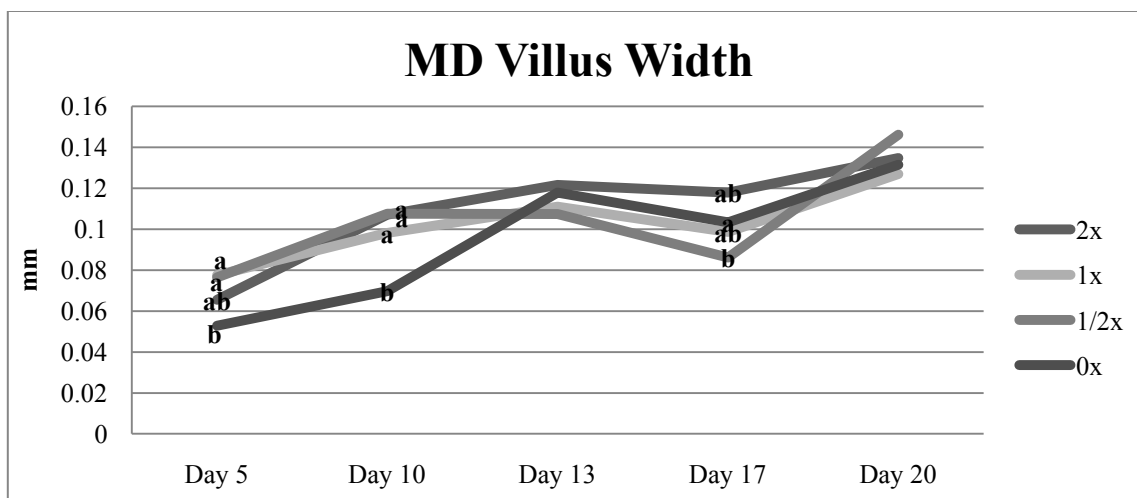


Figure 16 continued.

Height and width measurements taken at the illeocecal junction were more variable and not necessarily correlated with vaccine dose (Fig. 17). Height measurements appear to converge on day 13. Significant differences in the illeocecal *muscularis mucosae* were seen between the control and 2x group on day 17. Similar variability was seen in measurements taken in the ceca (Fig. 18). The control group had

the smallest villus width on day five and the largest on day 20. No significant differences were seen on day 20 regarding height and *muscularis mucosae* thickness between the groups.

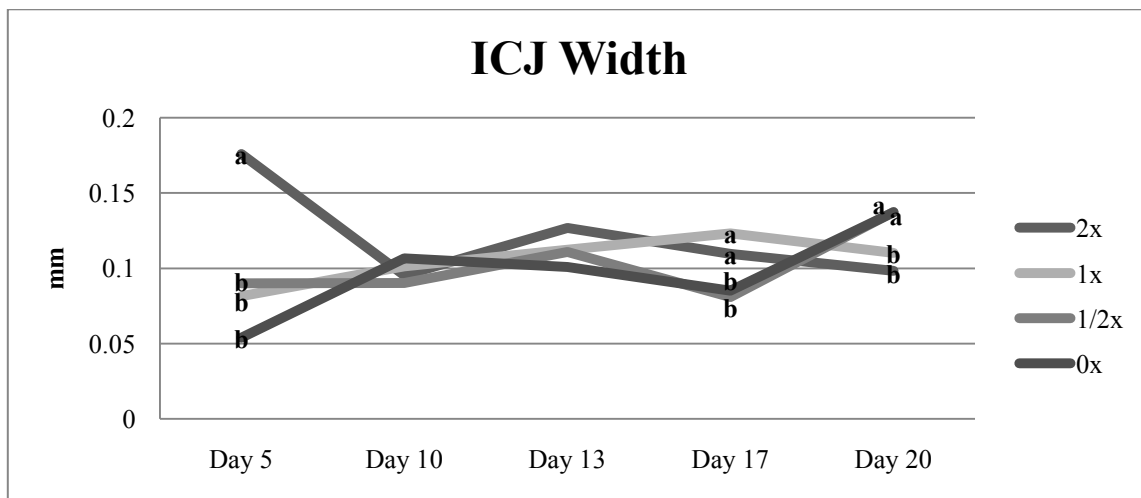
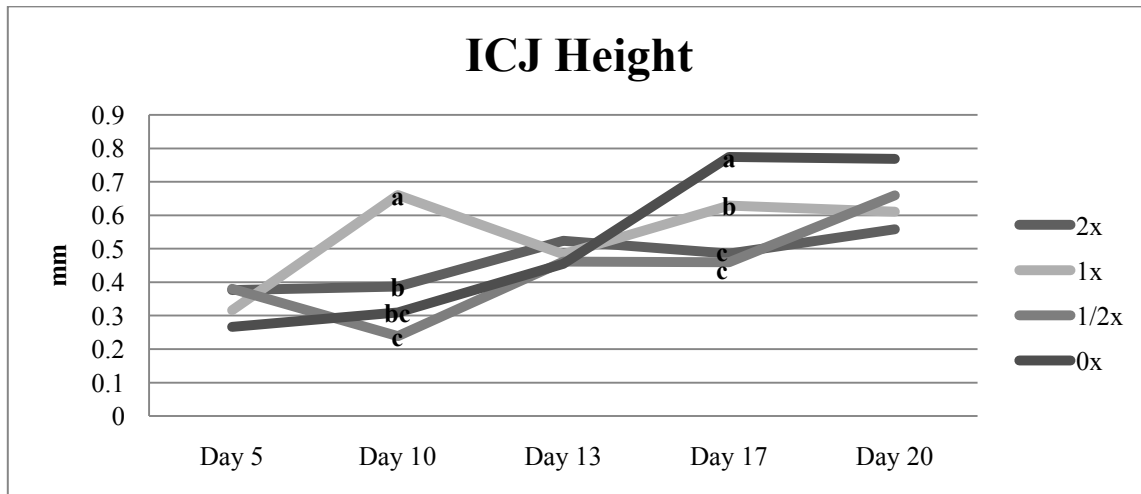


Figure 17. Intestinal measurements taken from the illeocecal junction. P-values <0.05 were considered significant.

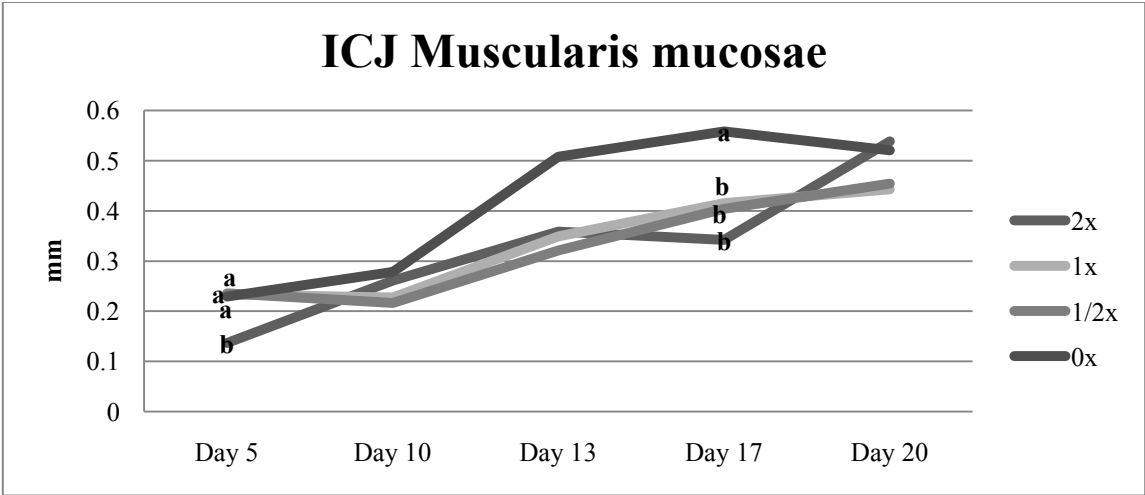


Figure 17 continued.

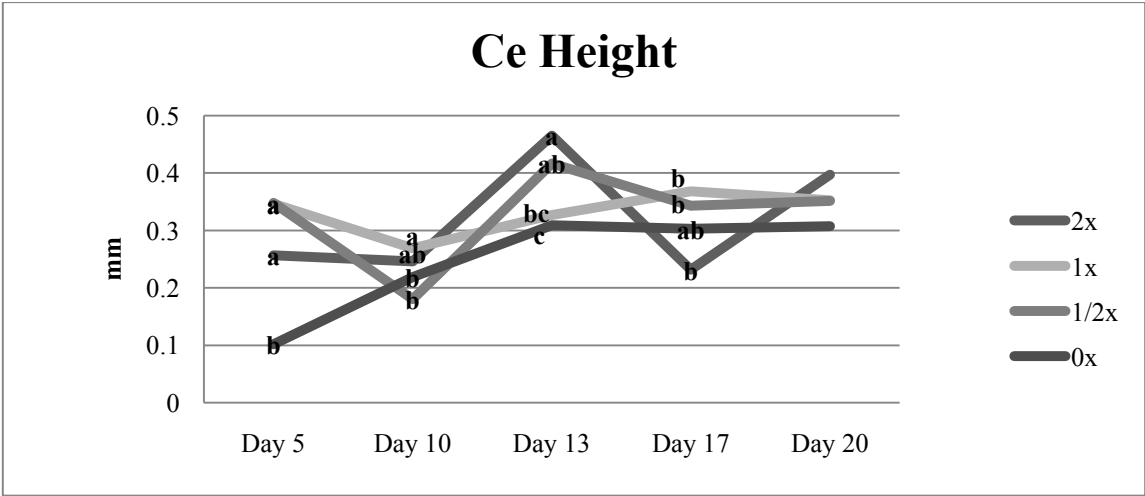


Figure 18. Intestinal measurements taken from the ceca. P-values <0.05 were considered significant.

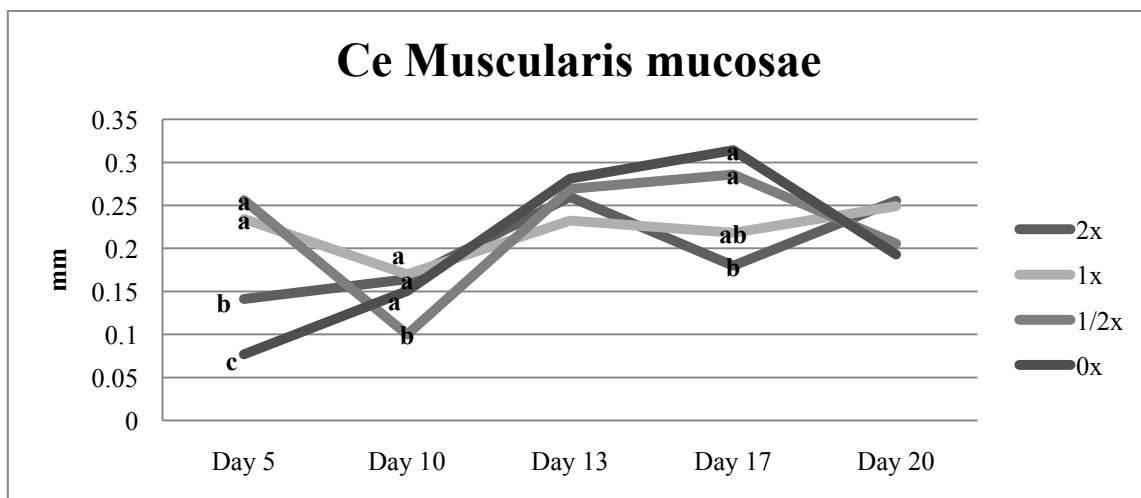
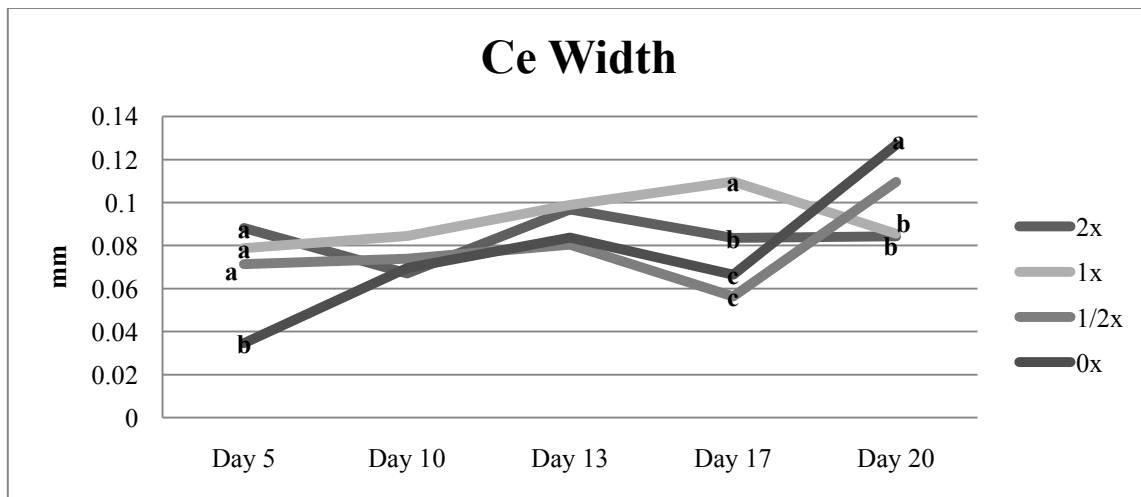


Figure 18. Continued.

Statistical analysis was limited in the vaccinated groups, particularly in the 2x dose group, due amount of variation throughout the study. The control group had much less intestinal measurement variability. Conway and colleagues (1999) saw similar results in broilers in which lesion scoring failed to correlate with oocyst dose. In addition, they did not see a linear increase in lesion scores and level of oocyst

consumption. This may be due to the coprophagic nature of the individual and variable consumption of oocysts. Alternative approaches to the traditional lesion scoring such as weight gain, feed consumption, and feed conversion may be a better way to analyze the effect of coccidiosis in turkeys (Conway et al., 1999).

There were no significant changes in the mucosal gene expression of IL-10 and IL-1 β in the intestinal tissue adjacent to the Meckel's diverticulum throughout the course of the study (Fig. 19). The lack of significant immunological activity in this area may indicate the lack of immunological response.

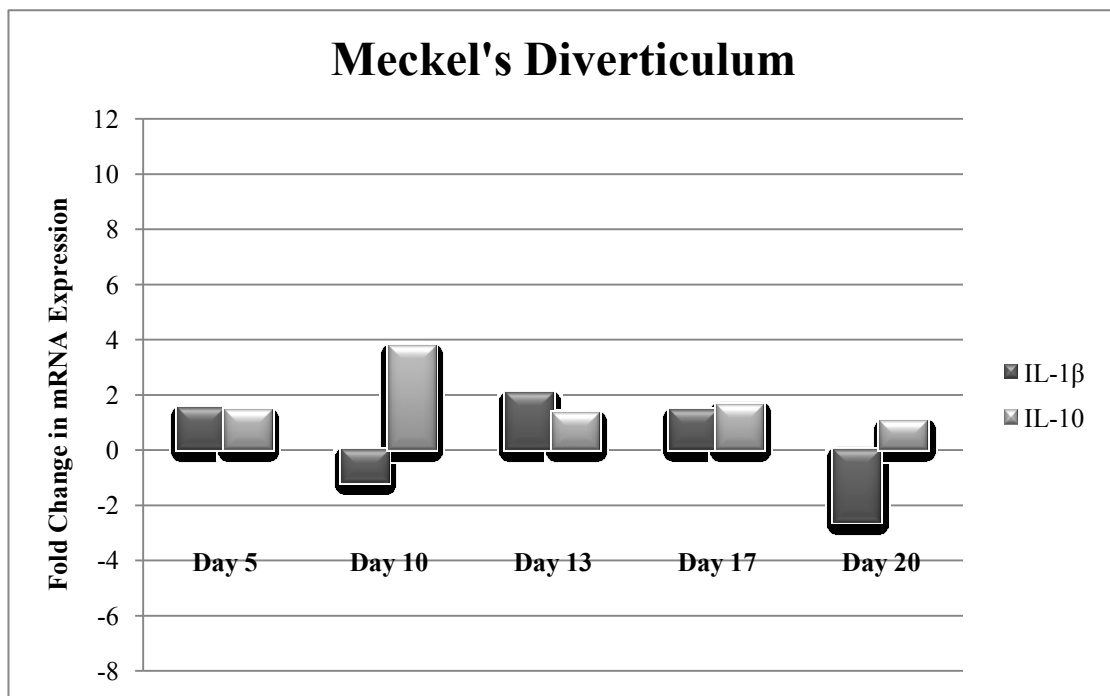


Figure 19. Fold change in mRNA gene expression in the Meckel's diverticulum. An '*' denotes a significant difference. P-value was <0.05.

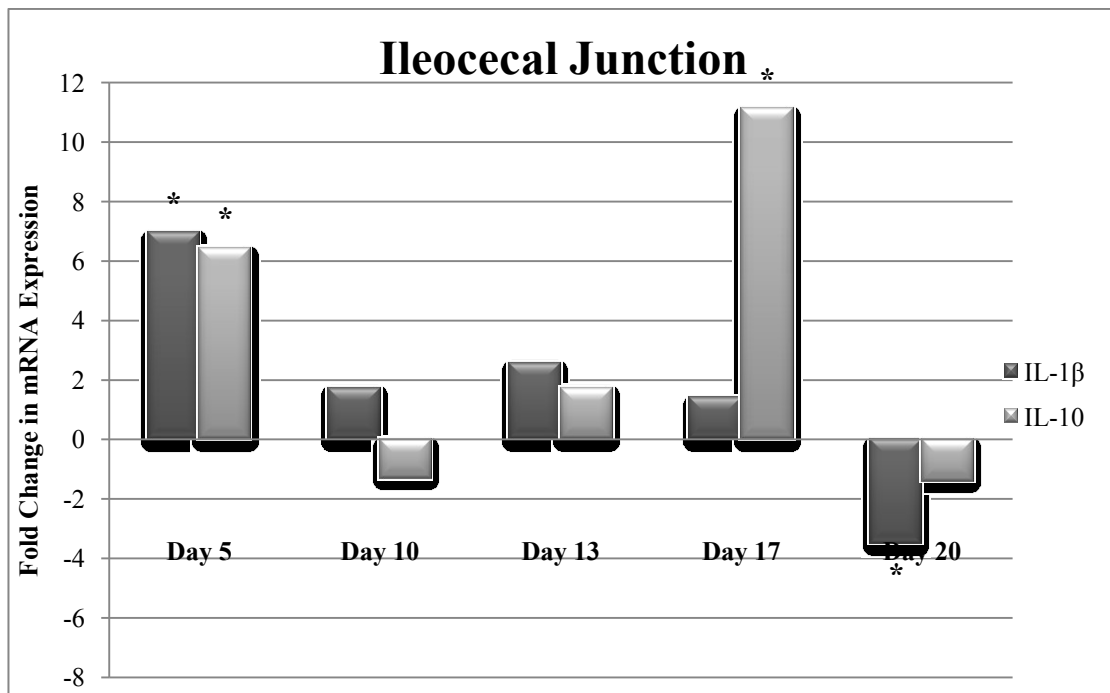


Figure 20. Fold change in mRNA expression in the ileocecal junction. An ‘*’ denotes a significant difference. P-value was <0.05.

Day five post vaccination there was a significant up regulation in both IL-10 and IL-1 β at the ileocecal junction. Interleukin-10 was significantly upregulated on day 17 and IL-1 β was significantly down regulated on day 20 in the ileocecal junction (Fig. 20). A considerable amount of changes in mucosal gene expression occurred in the ceca. Both IL-10 and IL-1 β were significantly upregulated on days 5, 10, and 13 post vaccination. Interleukin-10 was significantly upregulated in the ceca on day 17 and significantly down regulated on day 20 (Fig 21).

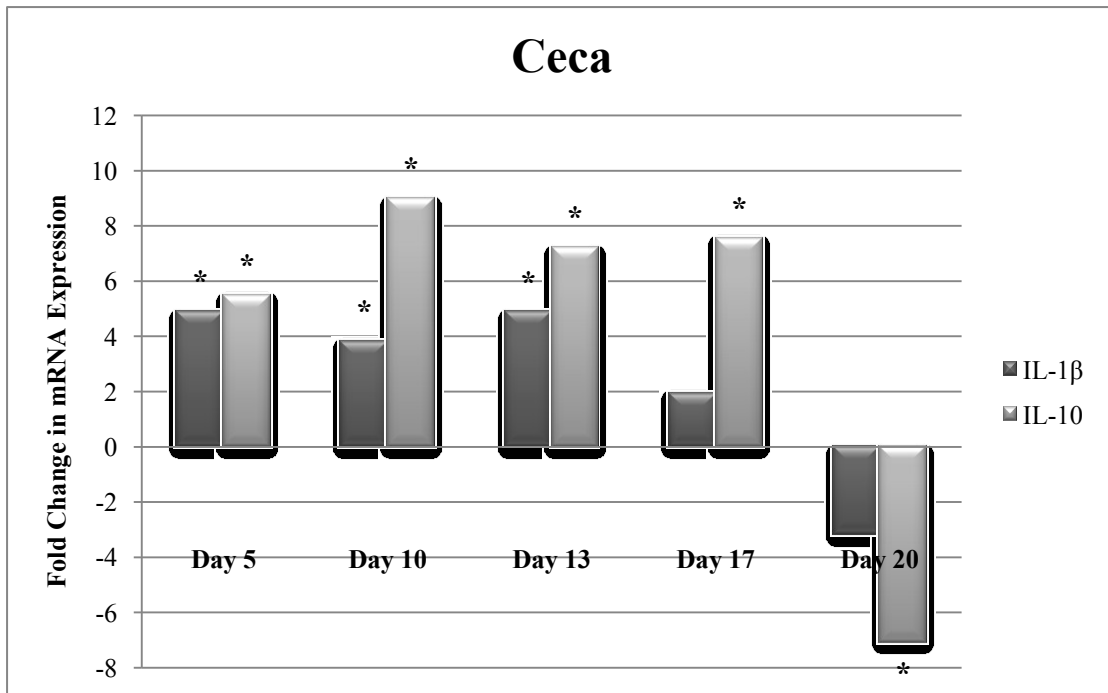


Figure 21. Fold change in mRNA expression in the ceca. An ‘*’ denotes a significant difference. P-value was <0.05.

The amount of immunological activity occurring in the ceca indicates that the species within the vaccine highly paracitize this region of the gastrointestinal tract. Interleukin-10 was much more active than IL-1 β that through day 17, IL-10 was trying to control the immune response in the ceca.

On average, there was one obvious outlier per collection day in the treated group. The massive outliers, excluded from the statistical results, are of particular interest for further investigations. Outliers were animal specific and across all tissue types. For example, on day 5 an individual animal was an outlier in IL-1 β in all three tissues types that were collected. The animal had a 26-fold increase near the Meckel’s diverticulum

and a 111 fold increase across both the ileocecal junction and ceca in the mucosal gene expression of IL-1 β . The normal group saw a 1.5 fold increase at the Meckel's diverticulum, a seven fold increase at the ileocecal junction and a five fold increase in IL-1 β in the ceca. Similarly, a measurable amount of GAPDH was recovered from an individual on day 20 but measurable amounts of IL-10 or IL-1 β were not, possibly indicating a lack of immune response. A massive outlier on day five post vaccination is of particular interest because the individual was gavaged the same dose as other individuals that did not respond in the same manner. For an unknown reason the outlier had what appears to be an uncontrolled or excessive immune response. Powell et al. (2009) reported an uncontrolled immune response in the turkey following challenges with another enteric pathogen, *Histomonas meleagridis*. It would be of interest to investigate why the individual outliers were seen.

Additional research regarding the turkey's immune response to pathogens, particularly coccidiosis, is needed to understand the vaccine and bird interaction. Coccivac-T® contains the original strains of *Eimeria* when it was first formulated in 1989 (Williams, 2002). The vaccine has not changed but the immune function of the turkey has. Several researchers indicate that through the selection of a more growth efficient bird, both the chicken and turkey industry has inadvertently selected for birds with a weaker immune system (Genovese et al., 2006; van Hemert et al., 2006; Genovese et al. 2007, Dhinakar Raj et al., 2009). Particular attention must be given to the turkey's immune response and the factors that contribute to the individual massive variation when gavaged with similar amounts of oocysts. Full grow out trials are needed

to examine the long term side effects of coccidiosis vaccination on weight gain, feed consumption, and feed conversion.

CHAPTER VI

CONCLUSIONS

Coccidiosis vaccine induced oocyst shedding, intestinal lesions, and mucosal gene expression in Hybrid® turkey hens vaccinated on the day of hatch were investigated. The first study examined the vaccine induced oocyst shedding patterns under experimental conditions through daily fecal sampling and gross observations. Peak shedding occurred at 5-6, 13- 17 and 19- 20 days post vaccination. All four replicates had similar shedding patterns. Oocyst shedding ceased at approximately 20 days. Management practices appeared to affect oocyst shedding patterns and may affect vaccine efficacy. Clinical signs such as lethargic birds and bloody droppings coincided with peaks in oocyst shedding but may be attributed to the vaccine dosage level from gavaging. Weekly body weights and rate of gain correlated with vaccine cycling. The possibility of compensatory growth requires further investigation.

The second study examined vaccine induced lesions at various dosage levels and mucosal gene expression in birds vaccinated with 0x, 1x, 1/2x, and 2x the manufactures available dose Coccivac-T®. Poults were sacrificed at 5, 10, 13, 17, and 20 days post vaccination based on oocyst shedding patterns seen in the previous study. Body weight and intestinal sections over the Meckel's diverticulum, ileocecal junction, and middle of the ceca were collected for histological examination and gene expression. Body weight was inversely related to vaccine dose. Measurements from the tip of the villus to the base of the lamina propria mucosae, villus width, and *muscularis mucosae* thickness

were taken from the histological sections. Intestinal measurements did not necessarily correlate with the vaccine dose, although there appeared to be some correlation on day five. IL-10, IL-1 β , and GAPDH gene expression was measured using RT-qPCR. There were no significant changes in the mucosal gene expression of IL-10 and IL-1 β in the intestinal tissue adjacent to the Meckel's diverticulum throughout the course of the study. On day five post vaccination IL-10 and IL-1 β were significantly upregulated in the ileocecal junction. Interleukin-10 was significantly upregulated on day 17 and IL-1 β was significantly down regulated on day 20 in the ileocecal junction. Both IL-10 and IL-1 β were significantly upregulated in the ceca day 5, 10, and 13 post vaccination. Interleukin-10 was significantly upregulated in the ceca on day 17 and significantly down regulated on day 20. It appears that IL-10 and IL-1 β can be used to study coccidiosis in the turkey. Based on gross pathology, histology, and gene expression, coccidiosis was most severe in the ceca.

There was a large individual variation in gene expression and vaccine induced intestinal lesions. Levels of variability were high among the vaccinated groups, therefore retained tissue and slides from other animals in the same group need to be examined in order to increase sample sizes and reveal significant differences. Uniform application of the vaccine does not appear to result in consistent lesion development and immune response. Unpredictable immune responses have been previously described in the turkey following infections with the enteric pathogen, *Histomonas meleagridis* (Powell et al., 2009). A similar immune response may occur with coccidiosis. As turkeys are bred for higher body weight and rate of gain increases, inadvertently there is

a negative impact on immune function (van Hemert et al., 2006, Dhinakar Raj et al., 2009). With the decreased immune function, live vaccines, such as Coccivac-T®, may need continual modifications such as attenuation to the formulation to reduce adverse side effects yet remain effective in the control of the disease.

REFERENCES

- Abasht, B., Kaiser, M.G., and Lamont, S.J. 2008. Toll-like receptor gene expression in the cecum and spleen of advanced intercross line chicks infected with *Salmonella enterica* serovar *enteritidis*. *Veterinary Immunology and Immunopathology* 123: 314-323.
- Abbas, A. K., Lichtman, A.H., and Pillai, S. 2007. *Cellular and Molecular Immunology*. 6 ed. Saunders Philadelphia.
- Alfaro, D. M., Silva, A.V.F., Borges, S.A., Maiorka, F.A., Vargas, S., and Santin, E. 2007. Use of *Yucca schidigera* extract in broiler diets and its effects on performance results obtained with different coccidiosis control methods. *Journal of Applied Poultry Research* 16: 248-254.
- Allen, P. C., Danforth, H., and Levander, O.A. 1997. Interaction of dietary flaxseed with coccidia infections in chickens. *Poultry Science* 76: 822-827.
- Andrews, J. 1933. The control of poultry coccidiosis by the chemical treatment of litter. *American Journal of Hygiene* 17: 466-490.
- Bar -Shira, E., Sklan, D., and Friedman, A. 2003. Establishment of immune competence in the avian GALT during the immediate post-hatch period. *Development and Comparative Immunology* 27: 147-157.
- Batungbacal, M. R., Hilomen, G.V., Luis, E.S., Centeno, J.R., and Carandang, N.F. 2007. Comparative efficacy of oregano extract and amprolium in the control of coccidiosis and their effects on broiler performance. *Philippine Journal of Veterinary Medicine* 44: 91-99.
- Brenes, A., and Roura, E. 2010. Essential oils in poultry nutrition: Main effects and modes of action. *Animal Feed Science and Technology* 158: 1-14.
- Ceruti, R., Ferrazzi, V., Gavazzi, L., Gallazzi, D., and Grill, G. 2005. Efficacy in the field of two anticoccidial vaccines for broilers. *Italian Journal of Animal Sciences* 4: 259-262.
- Chapman, H. D. 1992. Immunity to *Eimeria* in broilers reared on nicarbazin and salinomycin. *Poultry Science* 71: 577-580.

- Chapman, H. D. 1996. Administration of a coccidiosis vaccine to day-old turkeys via the eye and development of immunity to *Eimeria* species. *Poultry Science* 75: 1496-1497.
- Chapman, H. D. 1999. The development of immunity to *Eimeria* species in broilers given anticoccidial drugs. *Avian Pathology* 28: 155-162.
- Chapman, H. D. and Rathinam, T. 2007. Sensitivity of field isolates of *Eimeria* to monensin in the turkey. *Avian Diseases* 51: 954-957.
- Charlton, B. R. (Editor), 2006. *Avian Disease Manual*. American Association of Avian Pathologists, Jacksonville, FL.
- Christaki, E., Florou-Paneri P., Giannenas, I., Papazahariadou, M., Botsoglou, N.A. and Spais, A.B. 2004. Effect of a mixture of herbal extracts on broiler chickens infected with *Eimeria tenella*. *Animal Research* 53: 137-144.
- Collier, C. T., Hofacre, C.L., Payne, A.M., Anderson, D.B., Kaiser, P., Mackie, R.I., and Gaskins, H.R. 2008. Coccidia-induced mucogenesis promotes the onset of necrotic enteritis by supporting *Clostridium perfringens* growth. *Veterinary Immunology and Immunopathology* 122: 104-115.
- Conway, D. P., Dayton, A.D., and McKenzie, M.E. 1999. Comparative testing of anticoccidials in broiler chickens: The role of coccidial lesion scores. *Poultry Science* 78: 529-535.
- Conway, D. P. and McKenzie, M.E. 1991. *Poultry Coccidiosis- Diagnostic and Testing Procedures*. 2 ed. Pfizer, New York.
- Dalloul, R. A., and Lillehoj, H.S. 2005. Recent advances in immunomodulation and vaccination strategies against coccidiosis. *Avian Diseases* 49: 1-8.
- Dalloul, R. A., Lillehoj, H.S., Klinman, D.M., Ding, X., Min, W., Heckert, R.A., and Lillehoj, E.P. 2005. In ovo administration of CpG oligodeoxynucleotides and the recombinant microneme protein MIC2 protects against *Eimeria* infections. *Vaccine* 23: 3108-3113.
- Dalloul, R.A. and Lillehoj, H.S. 2006. Poultry coccidiosis: recent advancements in control measures and vaccine development. *Expert Reviews of Vaccines* 5: 143-163
- Danforth, H. D. 1998. Use of live vaccines in the control of avian coccidiosis: Experimental studies and field trials. *International Journal for Parasitology* 28: 1099-1109.

- Dasgupta, T., and Lee, E.H. 2000. A gel delivery system for coccidiosis vaccine: Uniformity of distribution of oocysts. *Canadian Veterinary Journal* 41: 613-616.
- Dhinakar Raj, G., Chazhavel Rajanathan, T.M., Kumanan, K., and Elankumaran, S. 2009. Expression profile of toll-like receptor mRNA in an indigenous Aseel breed of chicken in India. *International Journal of Poultry Science* 8: 651-655.
- Fitz-Coy, S. January 2010. Personal communication. Intervet Schering-Plough Animal Health. Willmar, MN.
- Garcia, J. L., Guimarães Jr. J., Headley, S.A., Bogado, A.L., Bungi, F.M., Ramalho, D.C., Montemor de Souza, L. 2008. *Eimeria tenella*: Utilization of a nasal vaccine with sporozoite antigens incorporated into Iscom as protection for broiler breeders against a homologous challenge. *Experimental Parasitology* 120: 185-190.
- Genovese, K.J., He, H., Lowry, V.K. Swaggerty, C.L., and Kogut, M.H. 2006. Comparison of heterophil functions of modern commercial and wild-type Rio Grande turkeys. *Avian Pathology*. 34: 217-223.
- Genovese, K.J., He, H., Lowry, and Kogut, M.H. 2007. Comparison of MAP and tyrosine kinase signaling in heterophils from commercial and wild-type turkeys. *Developmental and Comparative Immunology*. 31: 927-933.
- Giannenas, I., Florou-Paneri, P., Papazahariadou, M., Botsoglou, N.A., and Spais, A.B. 2003. Effect of dietary supplement with oregano essential oil on performance of broilers after experimental infection with *Eimeria tenella*. *Archives of Animal Nutrition* 57: 99-106.
- Haghighi, H.R., Abdul-Careem, M.F., Dara, R.A., Chambers, J.R., and Sharif, S. 2008. Cytokine gene expression in the chicken cecal tonsils following treatment with probiotics and *Salmonella* infection. *Veterinary Microbiology* 126: 225-233.
- Hilton, L. S., Bean, A.G.D., and Lowenthal, J.W. 2002. The emerging role of avian cytokines as immunotherapeutics and vaccine adjuvants. *Veterinary Immunology and Immunopathology* 85: 119-128.
- Hume, M. E., Clemente-Hernandez, S., and Oviedo-Rondont, E.O. 2006. Effects of feed additives and mixed *Eimeria* species infection on intestinal microbial ecology of broilers. *Poultry Science* 85: 2106-2111.

- Johansen, C. H., Bjerrum, L., and Pederson, K. 2007. Impact of salinomycin on the intestinal microflora of broiler chickens. *Acta Veterinaria Scandinavica* 49: 30-37.
- Kaiser, P., Rothwell, L., Avery, S., and Balu, S. 2004. Evolution of interleukins. *Development and Comparative Immunology* 28: 375-394.
- Karlson, T. and Reid, W.M. 1978. Development of immunity to coccidiosis in chickens administered anticoccidials in feed. *Avian Diseases* 22: 487-495.
- Kim, C.H., Lillehoj, H.S., Bliss, T.W., Keeler Jr., C.L., Hong, Y.H., Park, D.W., Yamage, M., Min, W., and Lillehoj, E.P. 2008. Construction and application of an avian intestinal intraepithelial lymphocyte cDNA microarray (AVIELA) for gene expression profiling during *Eimeria maxima* infection. *Veterinary Immunology and Immunopathology* 124: 341-354.
- Lee, J. T., Broussard, C., Fitz-Coy, S., Burke, P., Eckert, N.H., Stevens, S.M., Anderson, P.N., Anderson, S.M., and Caldwell, D.J. 2009. Evaluation of live oocyst vaccination or salinomycin for control of field-strain *Eimeria* challenge in broilers on two different feeding programs. *Journal of Applied Poultry Research* 18: 458-464.
- Li, G. Q., Kanu, S., Xiao, S.M., and Xiang, F.Y. 2005. Responses of chickens vaccinated with a live attenuated multi-valent ionophore-tolerant vaccine. *Veterinary Parasitology* 129: 179-186.
- Li, G. Q., Kanu, S., Xiang, F.Y., Xiao, S.M., Zhang, L., Chen, H.W. and Ye, H.J., 2004. Isolation and selection of ionophore-tolerant *Eimeria* precocious lines: *E. tenella*, *E. maxima*, and *E.acervulina*. *Veterinary Parasitology* 119: 261-276.
- Lillehoj, H. S. 1998. Role of T lymphocytes and cytokines in coccidiosis. *International Journal for Parasitology* 28: 1071-1081.
- Livak, K.J., and Schmittgen, T.D. 2001. Analysis of relative gene expression data using real-time quantitative PCR and the $2^{-\Delta\Delta CT}$ method. *Methods* 25: 402-408.
- Long, P.L. 1984. Coccidiosis control: Past, present, and future. *British Poultry Science* 25: 3-18.
- MacKinnon, K.M., He, H., Nerren, J.R., Swaggerty, C.L., Genovese, K.J., and Kogut, M.H. 2009. Expression profile of toll-like receptors within the gastrointestinal tract of 2-day-old *Salmonella enteritidis* infected broiler chickens. *Veterinary Microbiology* 137: 313-319.

- Mathis, G. F. 1993. Toxicity and acquisition of immunity to coccidia in turkeys medicated with anticoccidials. *Journal of Applied Poultry Research* 2: 239-244.
- McDonald, V. and Shirley, M.W. 2009. Past and future: Vaccination against *Eimeria*. *Parasitology* 136: 1477-1489.
- Muir, W. I., Bryden, W.L., and Husband, A.J. 2000. Immunity, vaccination and the avian intestinal tract. *Development and Comparative Immunology* 24: 325-342.
- Oviedo-Rondon, E. O., Hume, M.E., Hernandez, C., and Clemente-Hernandez, S. 2006. Intestinal microbial ecology of broilers vaccinated and challenged with mixed *Eimeria* species, and supplemented with essential oil blends. *Poultry Science* 85: 854-860.
- Powell, F. L., Rothwell, L., Clarkson, M.J., and Kaiser, P. 2009. The turkey, compared to the chicken, fails to mount an effective early immune response to *Histomonas meleagridis* in the gut. *Parasite Immunology* 31: 312-327.
- Roth, C.M. 2002. Quantifying gene expression. *Current Issues in Molecular Biology* 4: 93-100.
- Rattanaphol, M. and Rattanaphol, N. 2002. Efficacy of crude extract from the guava leaf *Psidium quajava* for the prevention of coccidiosis in broilers inoculated with *Eimeria tenella*. *Thai Journal of Phytopharmacy* 9: 15-23.
- Rebel, J., Van Hemert, S., Hoekman, A., Balk, F., Stockhofe-Zurwieden, N., Bakker, D., and Smits, M.A. 2006. Maternal diet influences gene expression in the intestine of offspring in chicken (*Gallus gallus*). 2006. *Comparative Biochemistry and Physiology, Part A* 145: 502-508.
- Rojs, O. Z., Rataj, A.V., Volk, M., Racnik, J., Dovc, A., Krapez, U., and Cajavec, S. 2007. Efficacy and benefits of prevention of coccidiosis in broilers by vaccination in comparison to anticoccidial drug program. *International Journal of Environment and Pollution* 31: 85-97.
- Rose, M. E. 1982. *The Biology of Coccidia*. Edward Arnold Publishers, London.
- Saif, Y. M. (Editor), 2003. *Diseases of poultry*. Blackwell Publishing, Ames, IA.
- Sharman, P. A., Smith, N.C., Wallach, M.G., and Katrib, M. 2010. Chasing the golden egg: Vaccination against poultry coccidiosis. *Parasite Immunology* 32: 590-598.

- Soares, R., Cosstick, T., and Lee, E.H. 2004. Control of coccidiosis in cages egg layers: A paper plate vaccination method. *Journal of Applied Poultry Research* 13: 360-363.
- Stevens, D. A. 1998. *Encyclopedia of Immunology*. 2 ed. Academic Press Ltd., London.
- Talebi, A., and Mulcahy, G. 2005. Partial protection against *Eimeria acervulina* and *Eimeria tenella* induced by synthetic peptide vaccine. *Experimental Parasitology* 110: 342-348.
- van Hemert, S., Hoekman, A.J.W., Smits, M.A., and Rebel, J.M.J. . 2006. Gene expression responses to a *Salmonella* infection in the chicken intestine differ between lines. *Veterinary Immunology and Immunopathology* 114: 247-258.
- Vermeulen, A. N. 1998. Progress in recombinant vaccine development against coccidiosis: A review and prospects into the next millennium. *International Journal for Parasitology* 28: 1121-1130.
- Vermeulen, A. N., Schaap, D.C., and Schetters, P.M. 2001. Control of coccidiosis in chickens by vaccination. *Veterinary Parasitology* 100: 13-20.
- Waldenstedt, L. 2003. Effect of vaccination against coccidiosis in combination with an antibacterial oregano compound in organic broiler production. *Acta Agriculturae Scandinavica: Section A, Animal Science* 52: 101-109.
- Weber, F. H. and Evans, N.A. 2003. Immunization of broiler chicks by in ovo injection of *Eimeria tenella* sporozoites, sporocysts, or oocysts. *Poultry Science* 82: 1701-1707.
- Williams, R. B. 1998. Epidemiological aspects of the use of live anticoccidial vaccines for chickens. *International Journal for Parasitology* 28: 1089-1098.
- Williams, R. B. 2002. Fifty years of anticoccidial vaccines for poultry (1952-2002). *Avian Diseases* 46: 775-802.
- Yadav, A., Gupta, S.K. 2007. Effect of ionophores on immunity to *Eimeria tenella* field isolates. *Indian Journal of Animal Research* 41: 43-47.
- Yin, Y., Lei, F., Zhu, L., Li, S., Wu, Z., Zhang, R., Gao, G.F., Zhu, B., and Wang, X. 2010. Exposure of different bacterial inocula to newborn chicken affects gut microbiota development and ileum gene expression. *The International Society for Microbial Ecology Journal* 4: 367-376.

- Yun, C. H., Lillehoj, H.S., and Lillehoj, E.P. 2000. Intestinal immune response to coccidiosis. *Developmental and Comparative Immunology* 24: 303-324.
- Zhou, Y.H., Raj, V.R., Siegel, E., and Yu, L. 2010. Standardization of gene expression quantification by absolute real-time qRT-PCR system using a single standard for marker and reference genes. *Biomarker Insights* 5: 79-85

VITA

Name: Michelle A. Behl

Address: Department of Poultry Science - Texas A&M University
101 Kleberg Bldg. College Station, TX 77843-2472

Email Address: Michelle.Behl@willmarpoultry.com
jmabehl@gmail.com

Education: B.S. Natural Sciences, Poultry Sciences, University of
Wisconsin- Madison, 2005